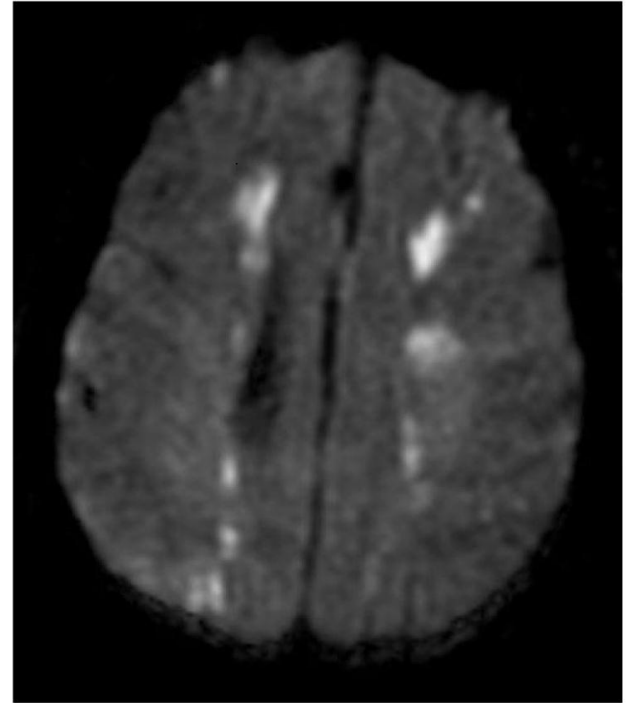

Neurologische complicaties na hartchirurgie

Rianne de Jong
Physician Assistant i.o.
Cardiothoracale Chirurgie
Isala Klinieken Zwolle

Hartlong Isala klinieken centrum



Hoe vaak komt het voor?

- Verwardheid/ Delier 13,5 – 41,5%
- “Verminderde cognitieve functie” 20 – 30%
- TIA/ CVA (ischemisch) 1,5 - 5,2%

Delier, risicofactoren

- Leeftijd > 65 jaar
- Diabetes mellitus
- CVA in voorgeschiedenis
- Hoge Euroscore
- Operatie duur > 3 uur
- Perioperatief toedienen van PC's
- LV ejectie fractie < 30%
- Preoperatieve IABP
- Cardiogene shock
- Spoed operatie

CVA, risicofactoren

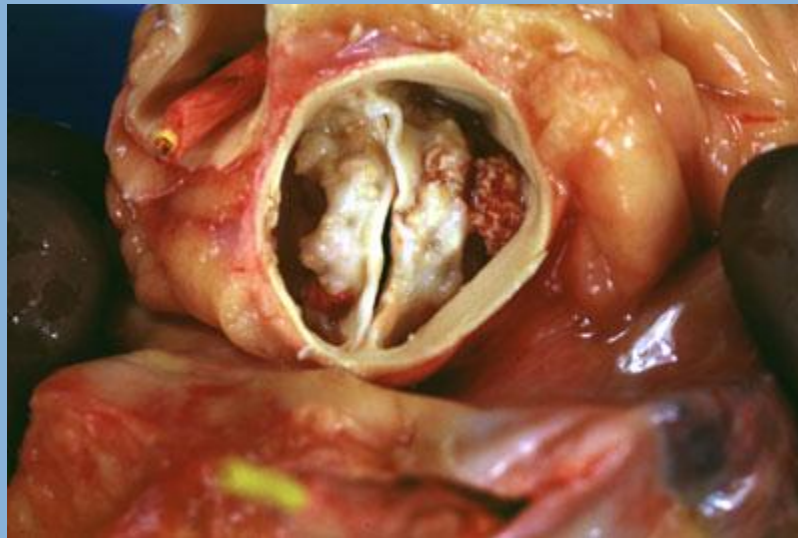
- Hoge bloeddruk
- Roken
- Overgewicht
- Cholesterol↑
- Onvoldoende lichaamsbeweging
- Diabetes Mellitus
- Atriumfibrilleren
- Arteriosclerose
- Cardiale VG

CVA/TIA, risicofactoren

- Soort ingreep

Aortachirurgie/ aortaboogchirurgie

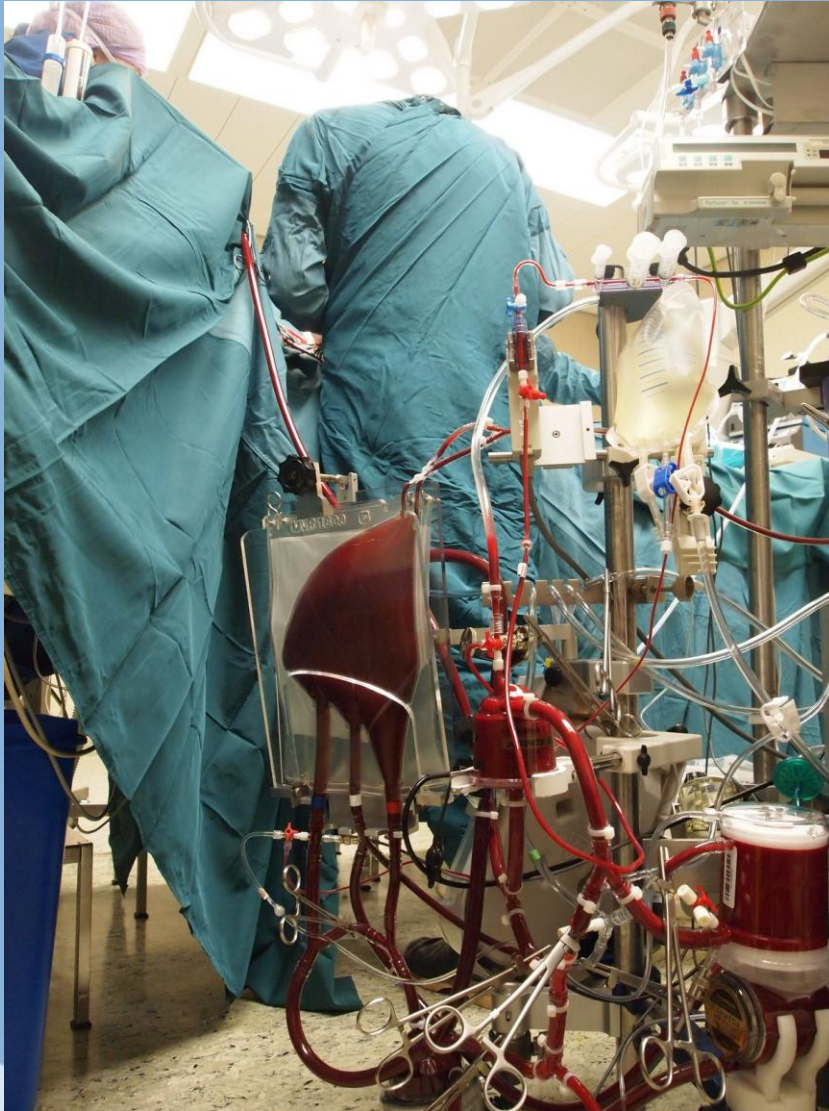
Diepe hypothermie en circulatie arrest



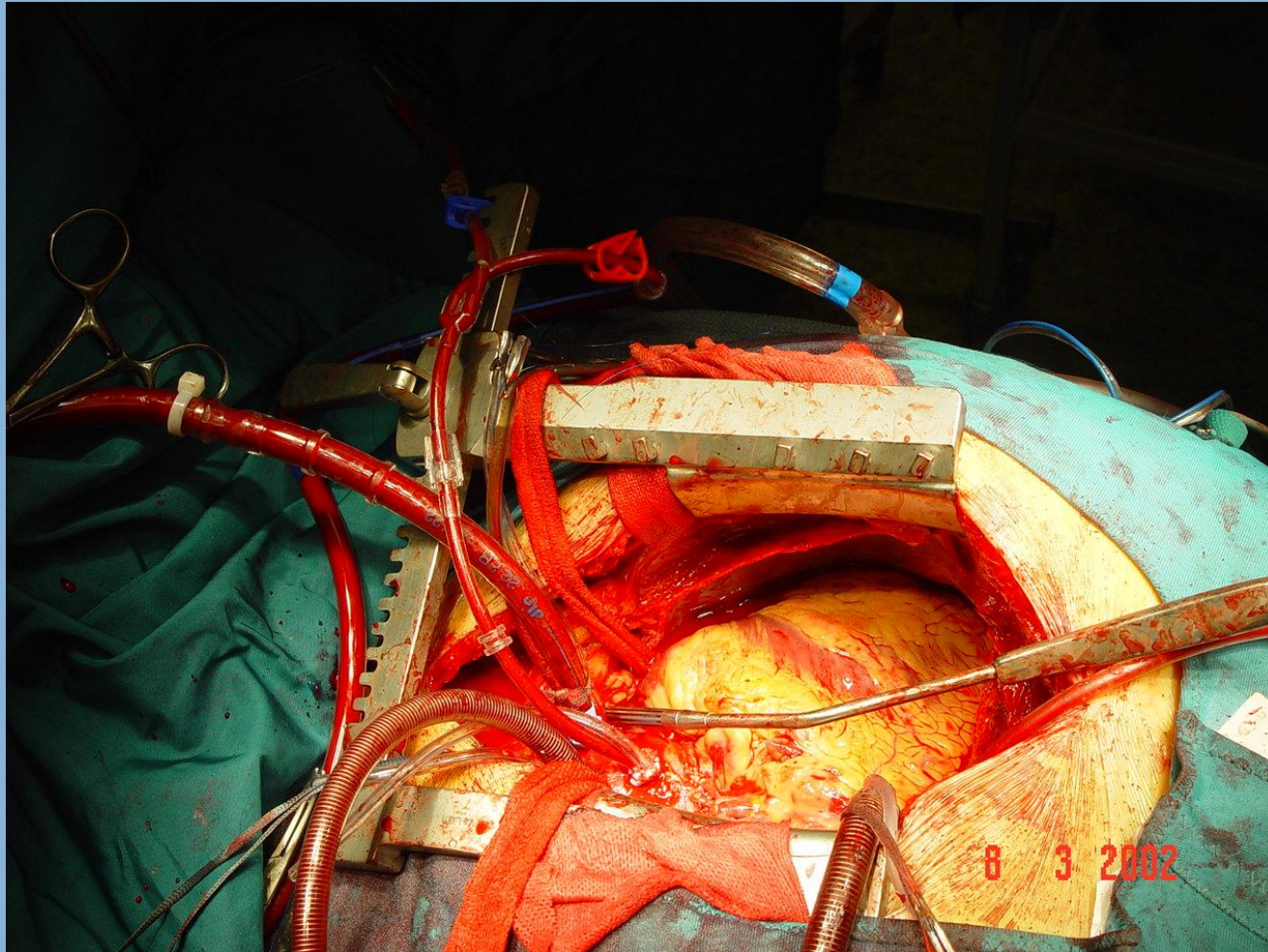
CVATIA, etiologie

- Cerebrale embolie
 - soft plaques uit aorta
 - luchtembolie
- Hypoperfusie/ hypotensie
- Vetembolie
 - Cardiectomie zuiger hartlongmachine
- Hyperglycemie
- Anemie
- Atriumfibrilleren
- Off-pump

Hartlongmachine



Hartlongmachine



Risicofactoren, lichamelijk onderzoek

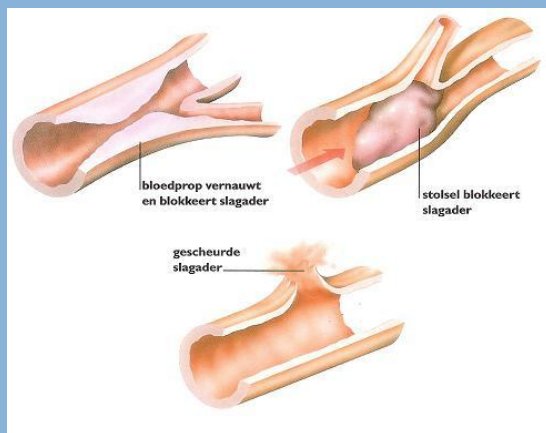
- Souffles over de carotiden
- Afwijkingen op al verrichte duplex carotiden

asymptomatisch

geen consequentie

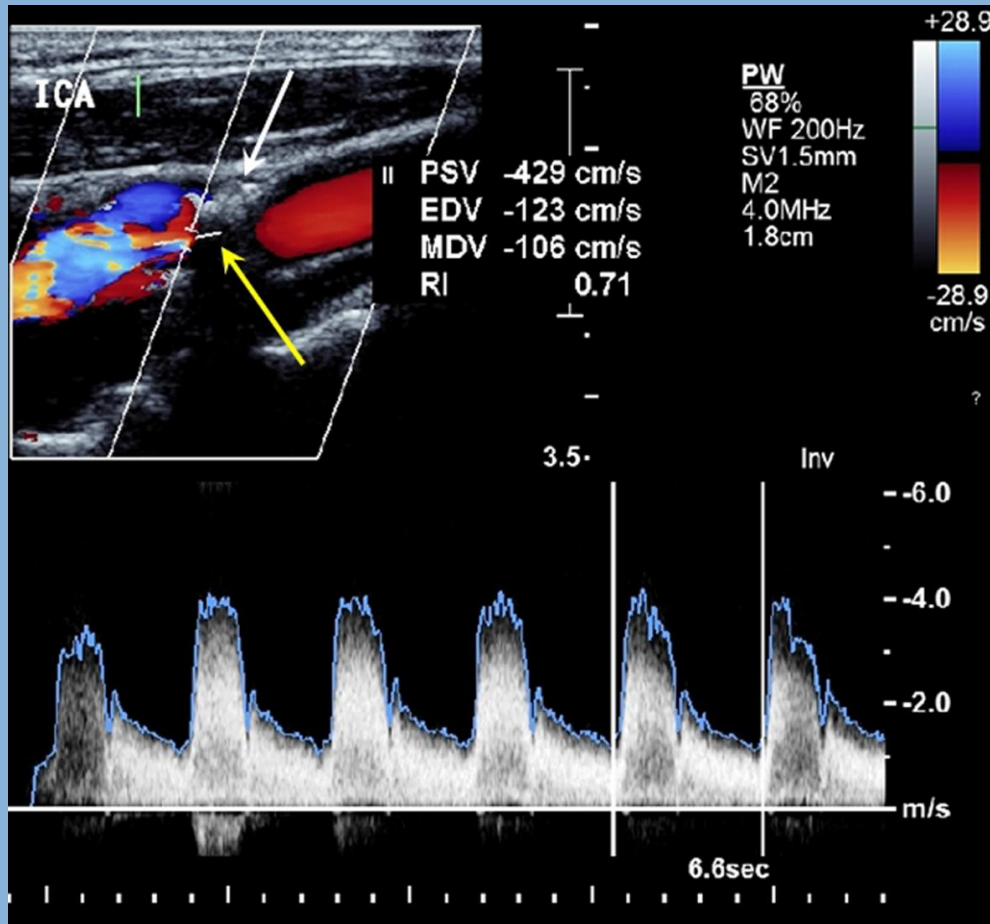
symptomatisch (< 6 maanden preop)

neurologische
interventie



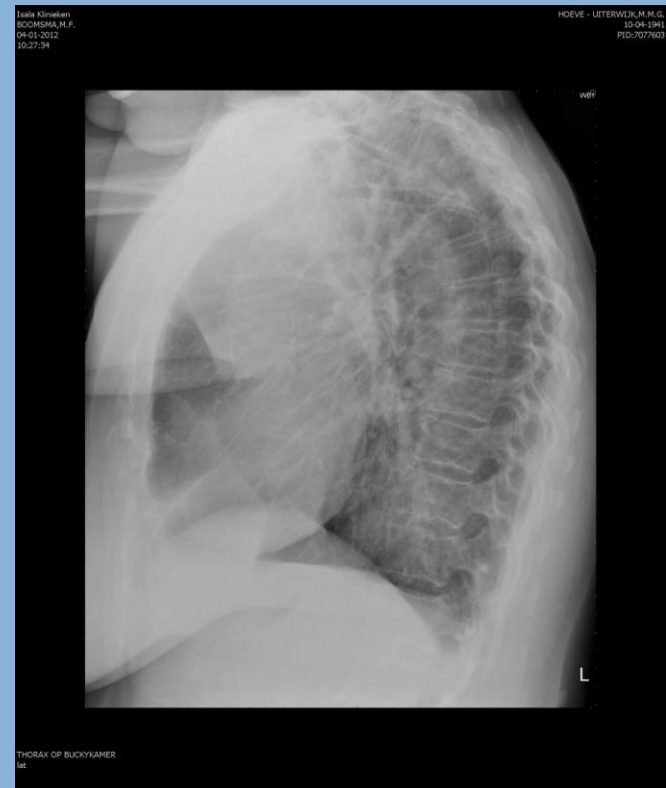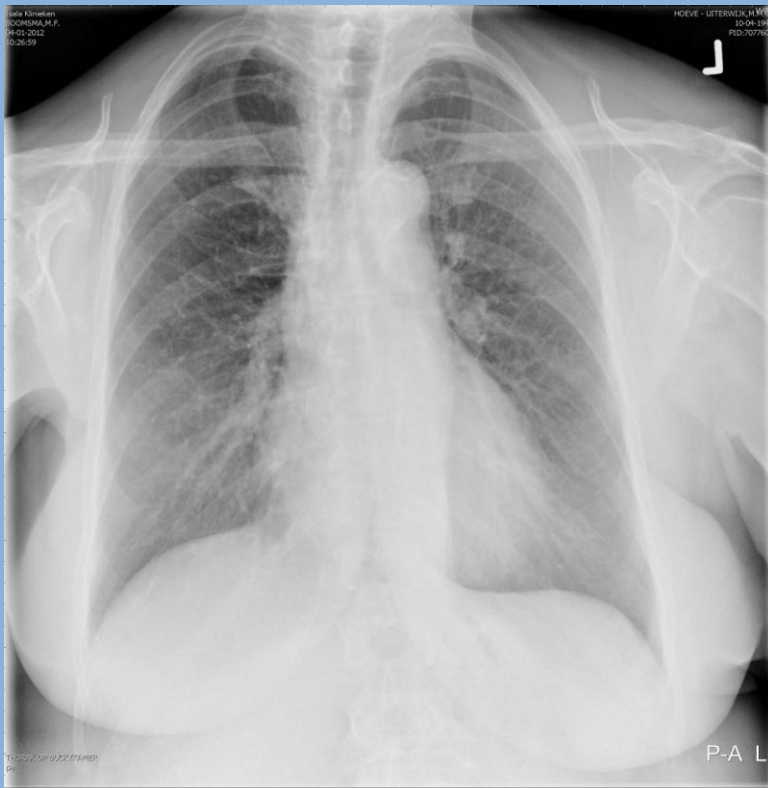
Risicofactoren, aanvullend onderzoek

- Duplex carotiden



Risicofactoren, aanvullend onderzoek

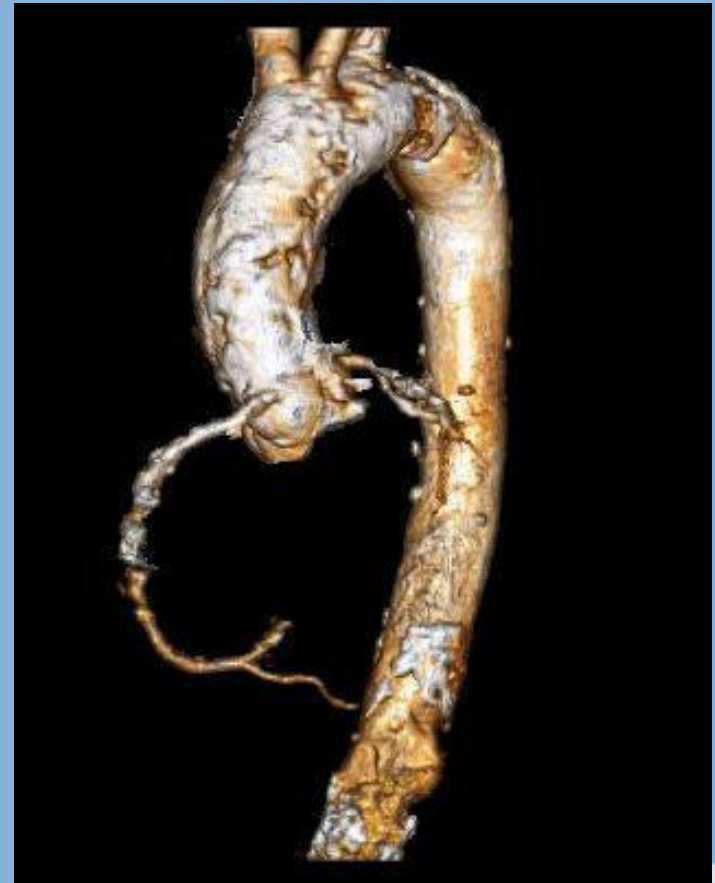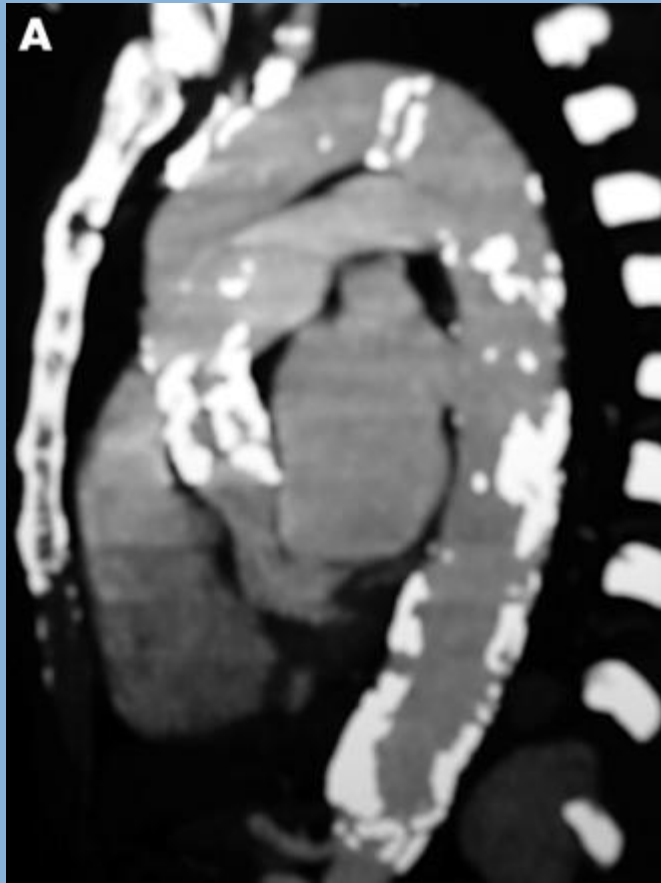
- X-Thorax



Preoperatief, veiligheids check

- Evaluatie aorta pathologie
 - CT gehele aorta zonder contrast
 - 3-D reconstructie van de aorta

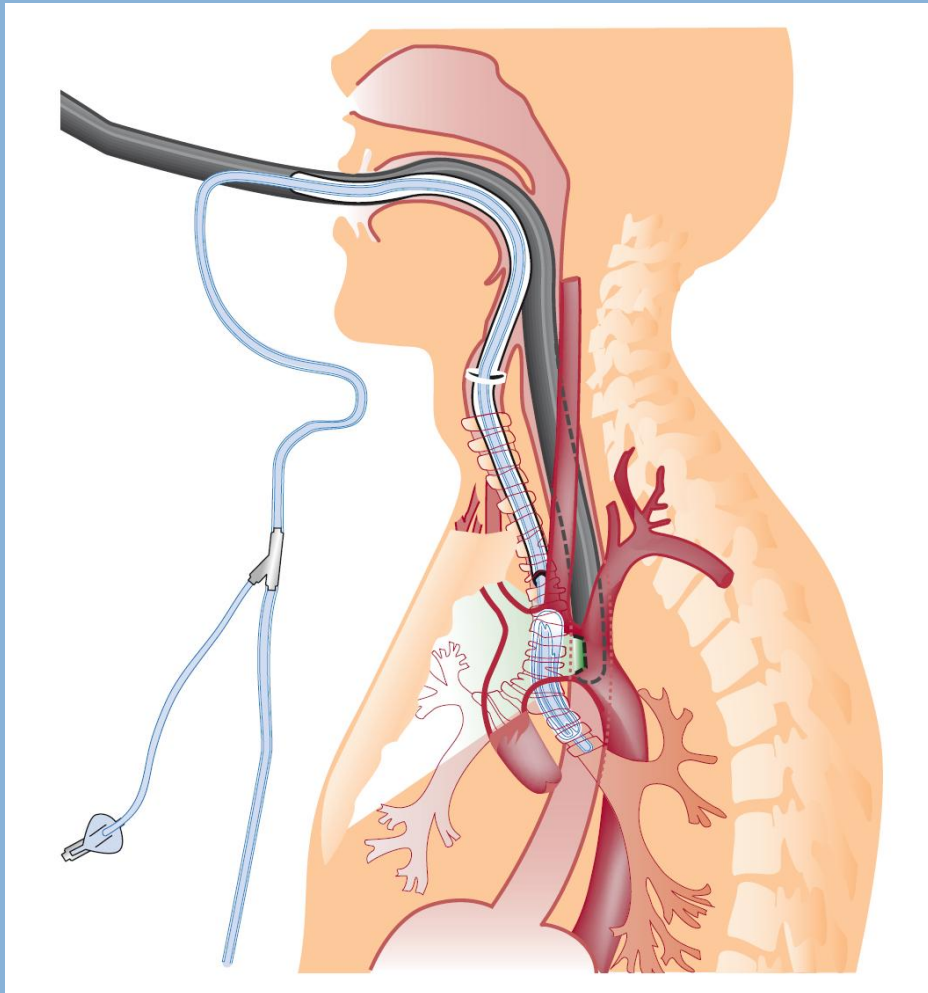
Preoperatief, CT AORTA



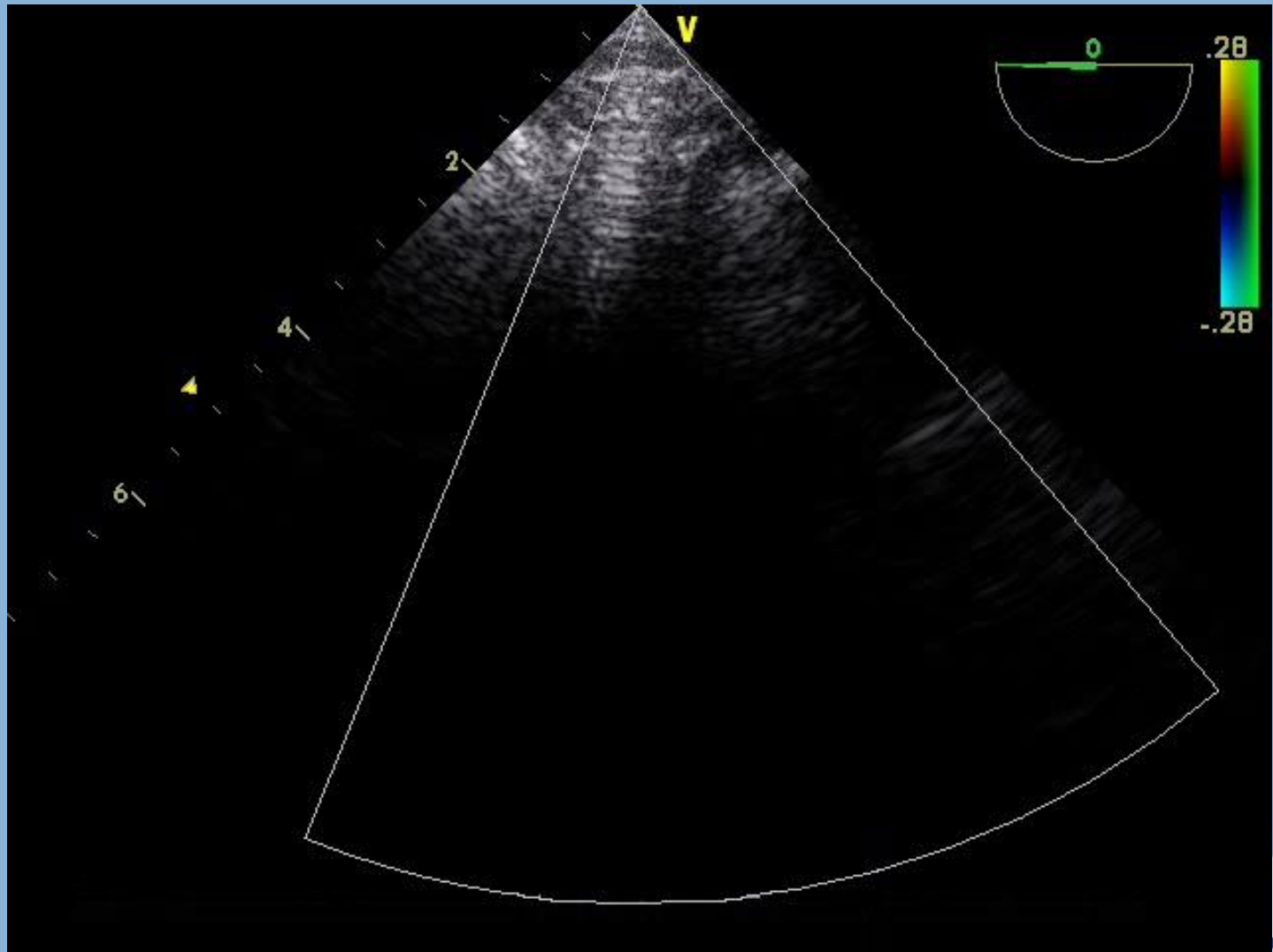
Preoperatief, veiligheids check

- Evaluatie aorta pathologie
 - CT gehele aorta zonder contrast
 - 3-D reconstructie van de aorta
 - A-view®


A-view®



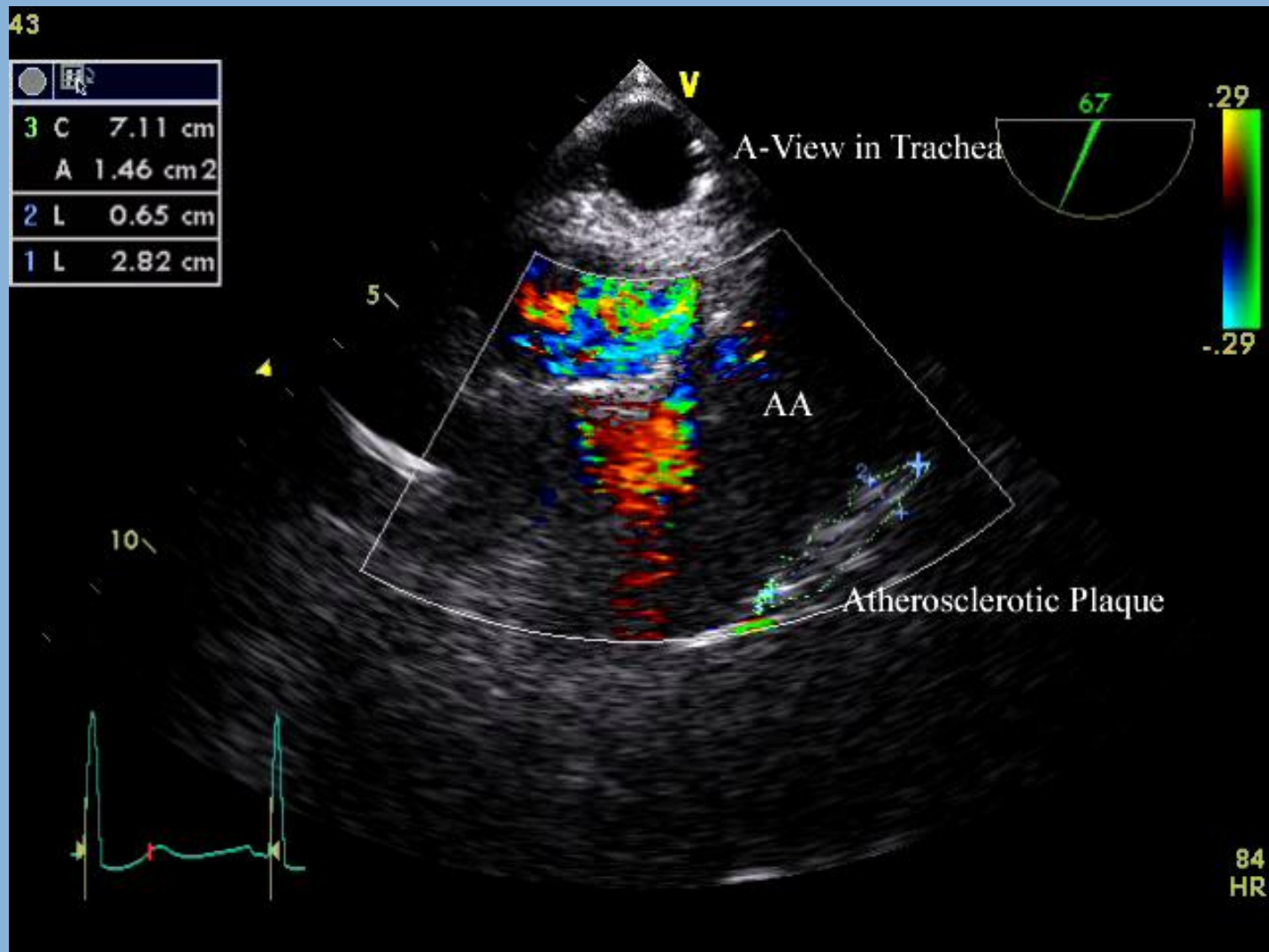
A-view[®], wat je niet zag

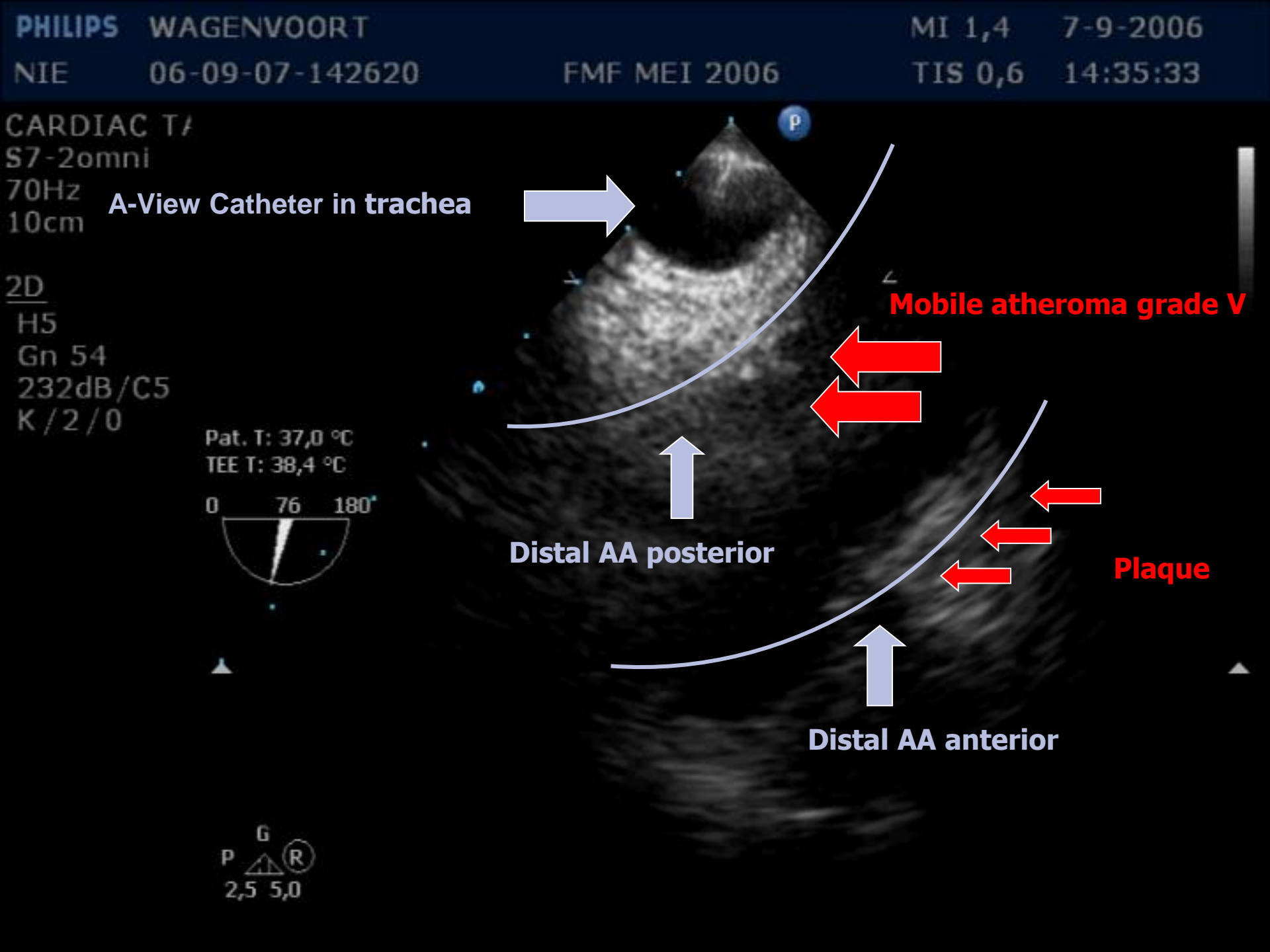


A-view®



A-view[®], wat nu wel te zien is

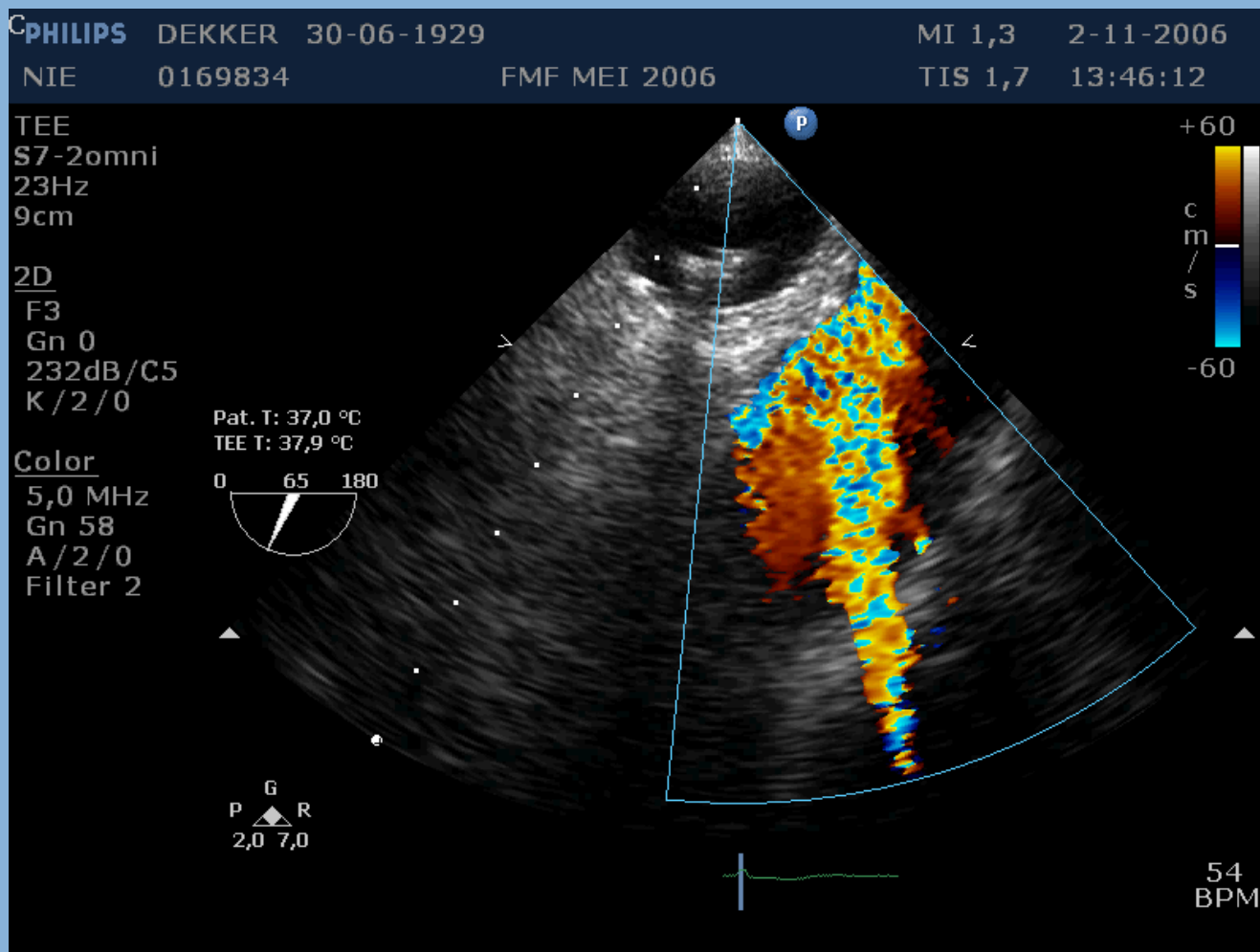




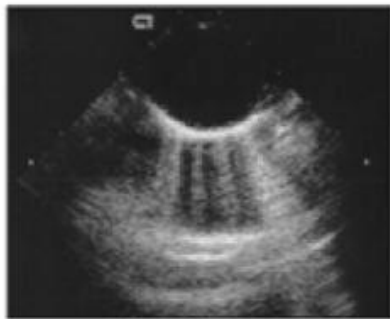Preoperatief, A-View®

- Trans oesophageale echo (TEE)
- Aorta ascendens en boog goed in beeld brengen
 - Atherosclerose scannen ivm hartlong machine
 - In beeld brengen dissectie
 - Gebruik tijdens TAVI

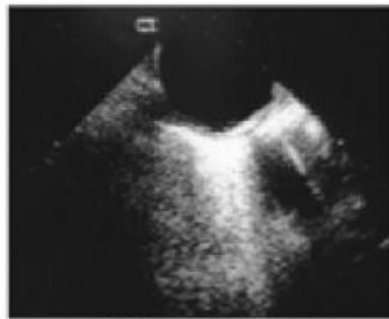A-view®, aorta scanning



Peri-operatief, voor incisie

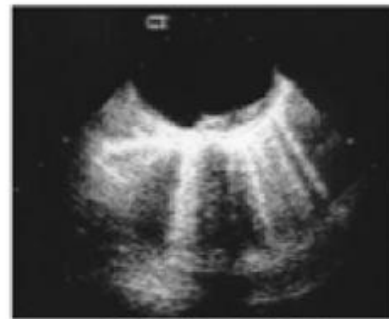

GRADE I



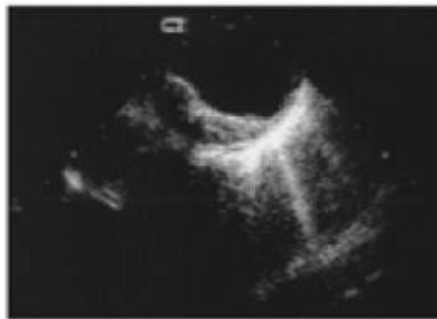
GRADE II

< 3mm



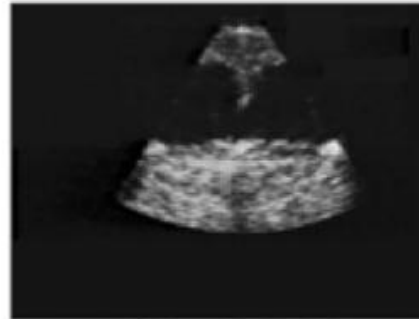
GRADE III

3 - 5 mm



GRADE IV

> 5 mm

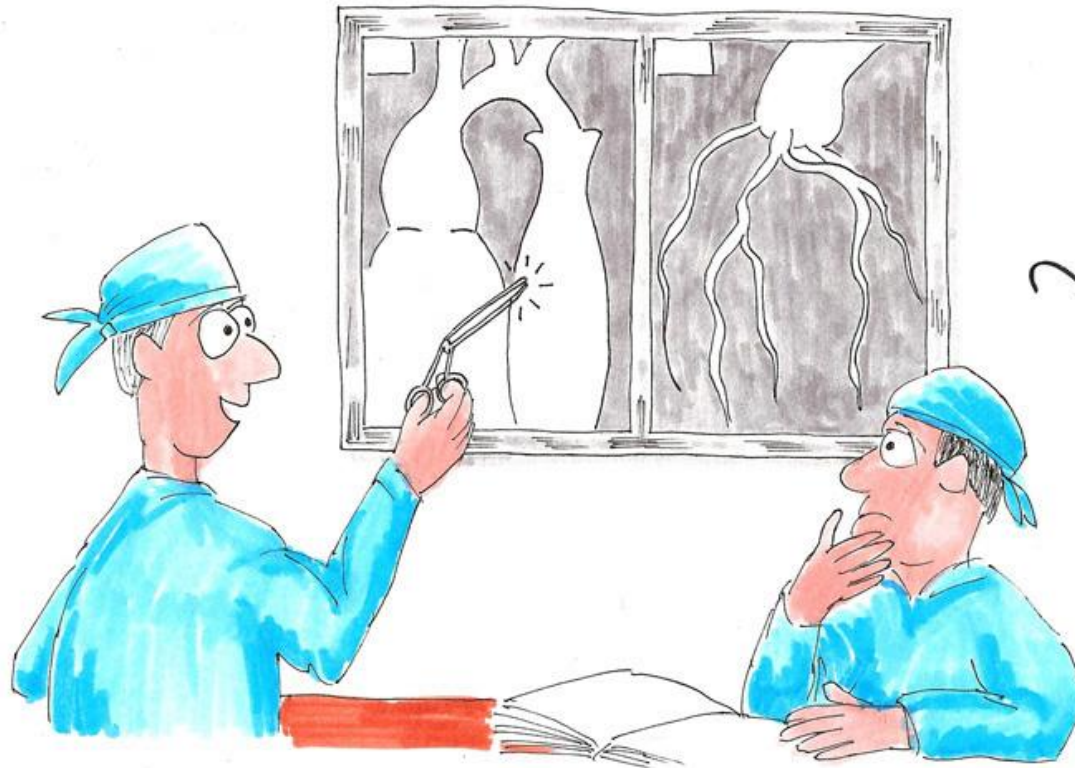

GRADE V

(mobile components)

Kalk.....en dan?

" I BELIEVE THIS PATIENT HAS A
PORCELAIN AORTA."

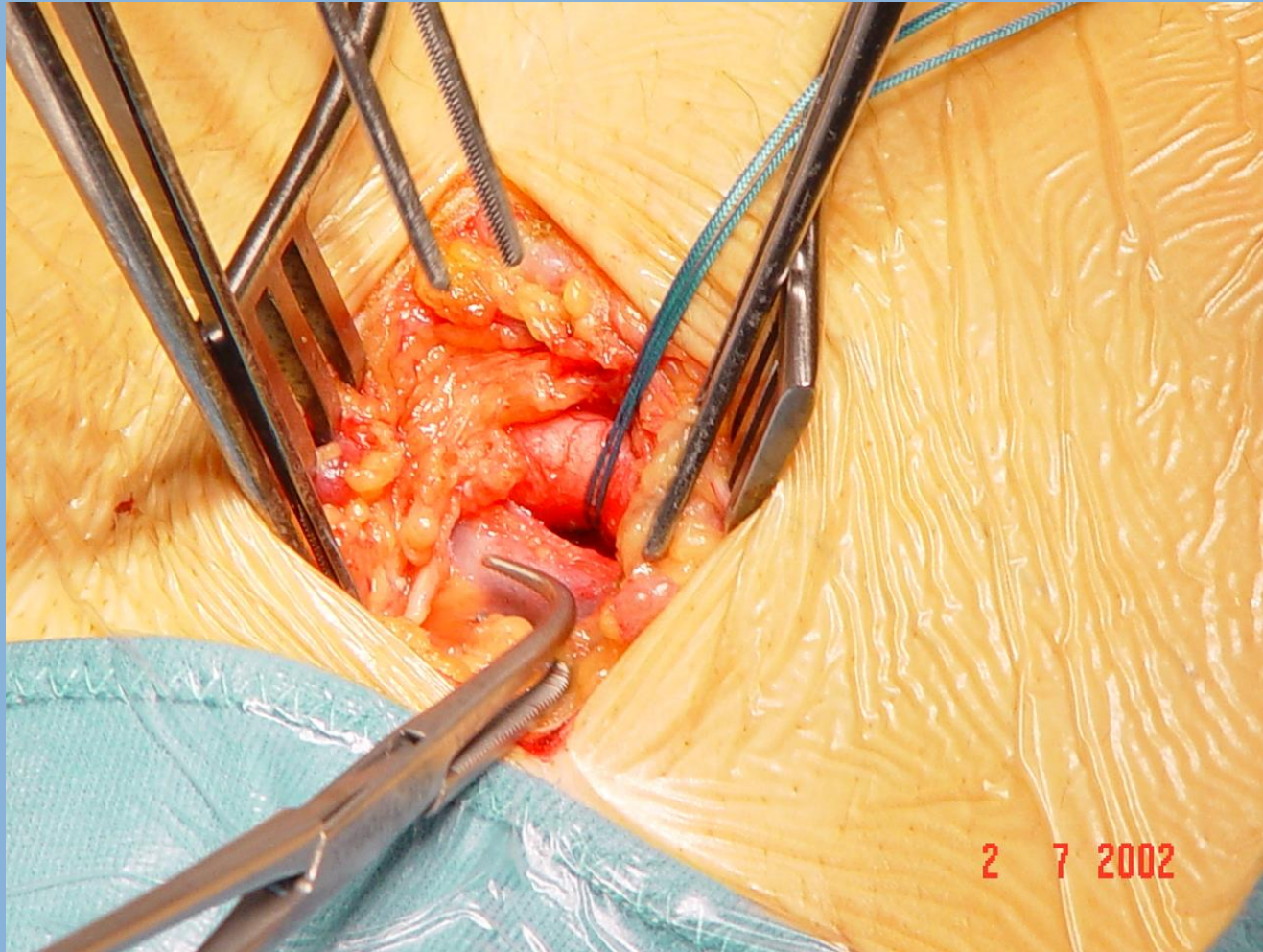


© TAU BOGA www.tauindex.com

Kalk.....en dan?

- Tussen de kalkschotsen door
- Liescanulatie? (“Kärcher in de aorta”)

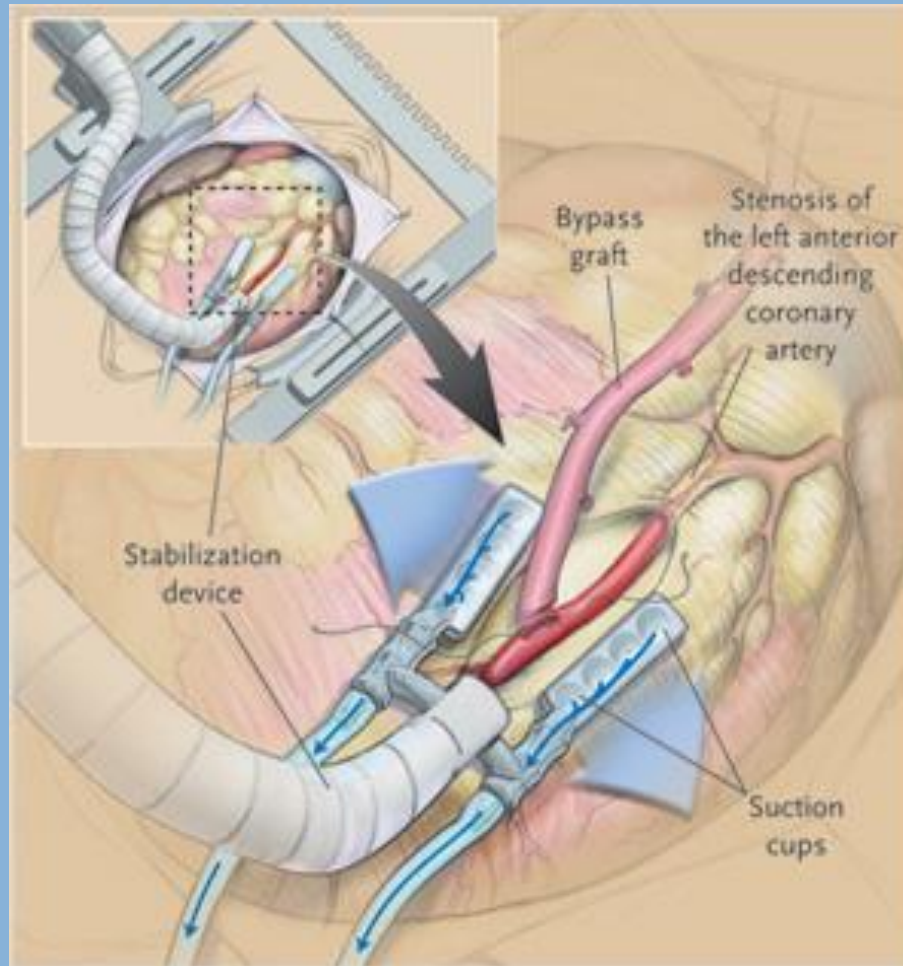
Liescanulatie



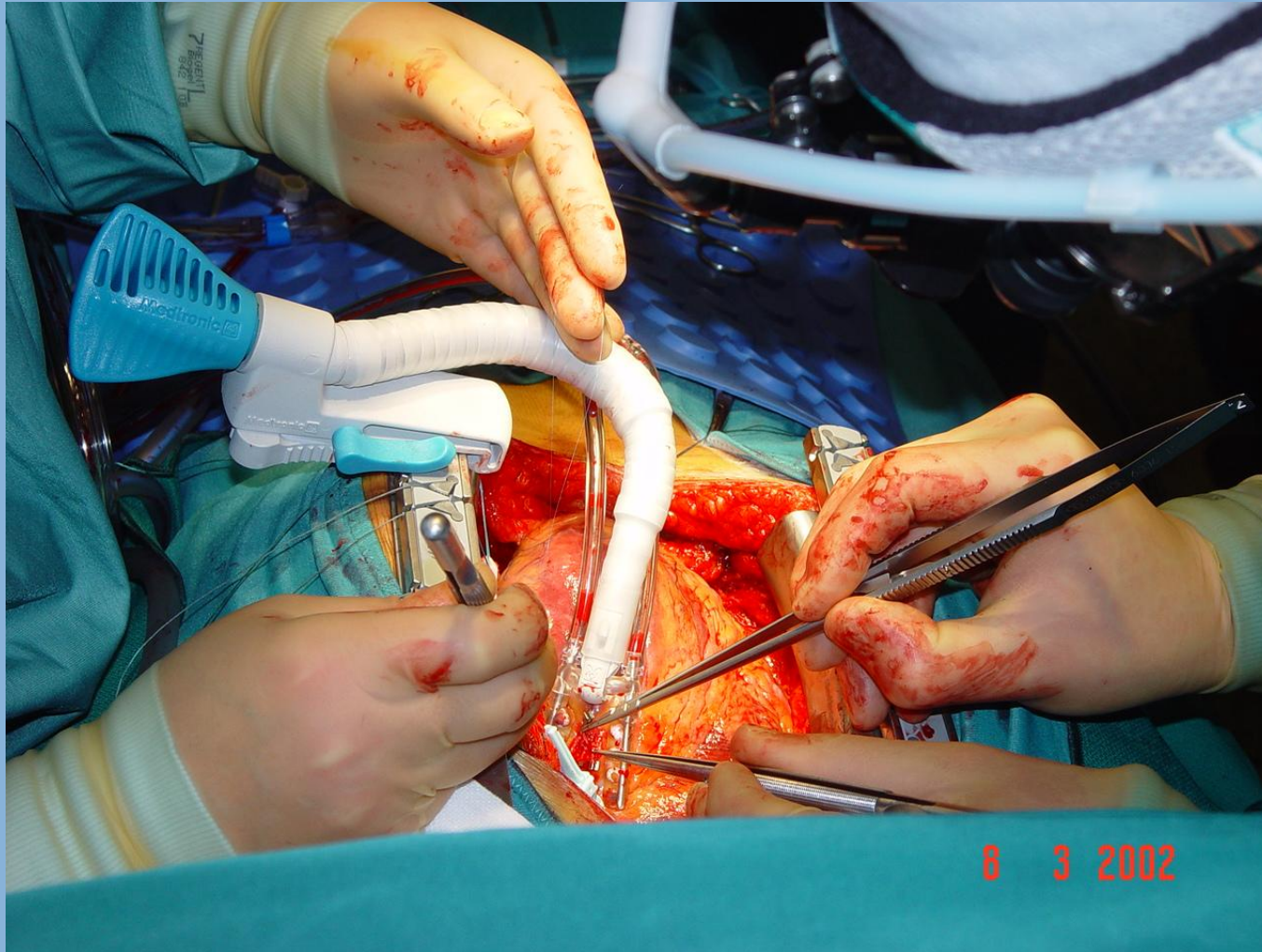
Kalk.....en dan?

- Tussen de kalkschotsen door
- Liescanulatie? (“Kärcher in de aorta”)
- Off pump (CABG)?

Off pump



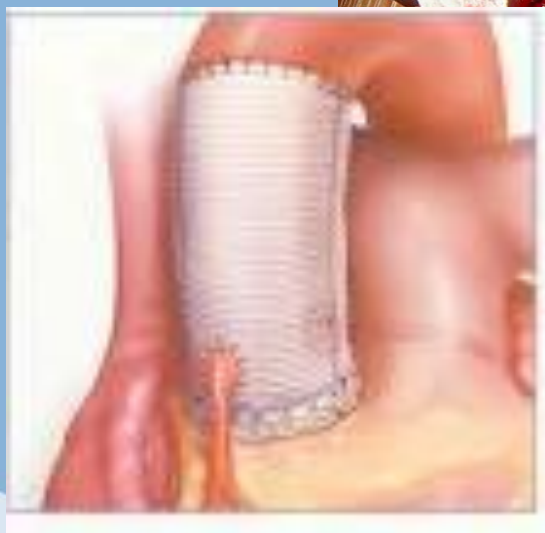
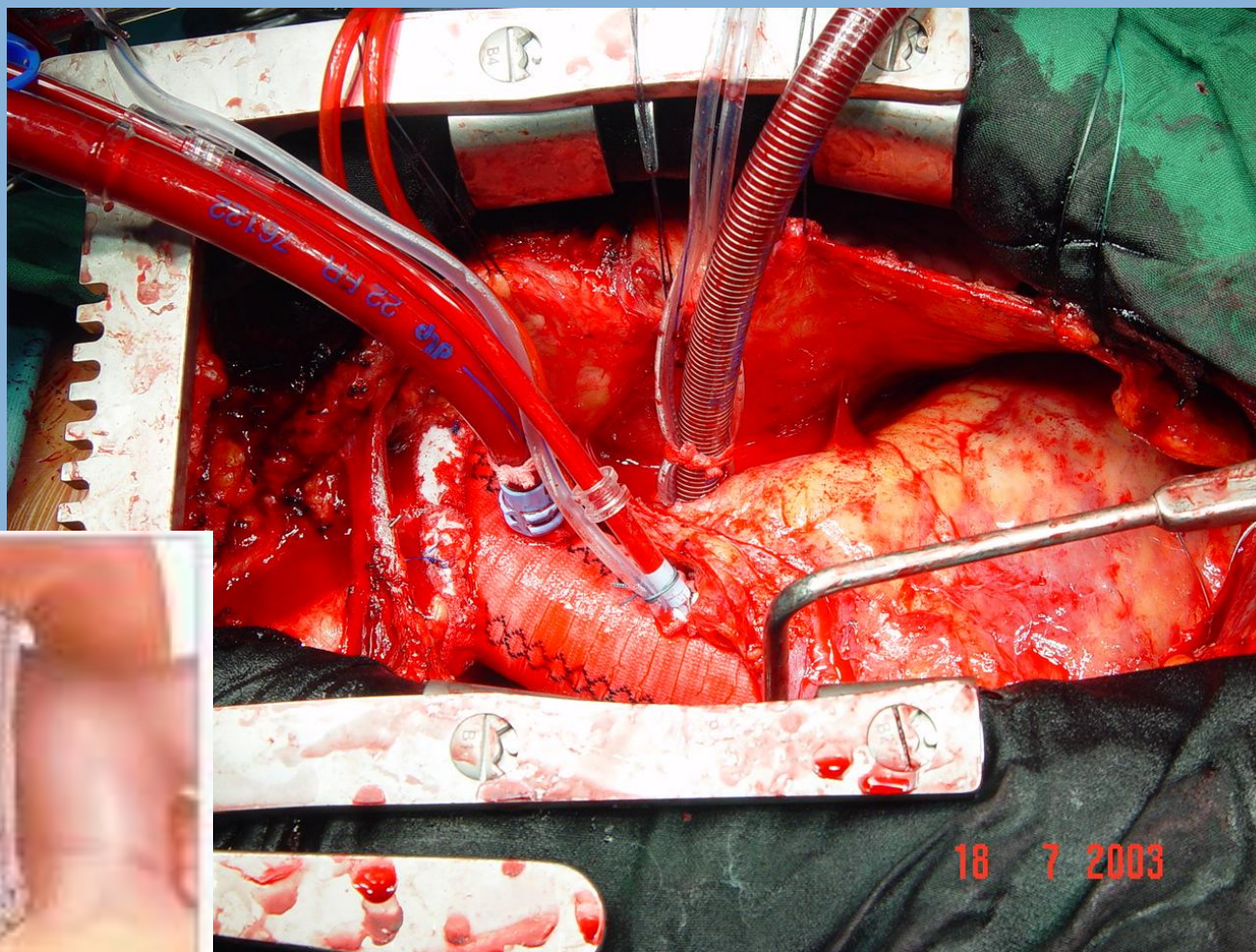
Off pump



Kalk.....en dan?

- Tussen de kalkschotsen door
- Liescanulatie? (“Kärcher in de aorta”)
- Off pump (CABG)?
- Aorta ascendens vervanging onder circulatie arrest?

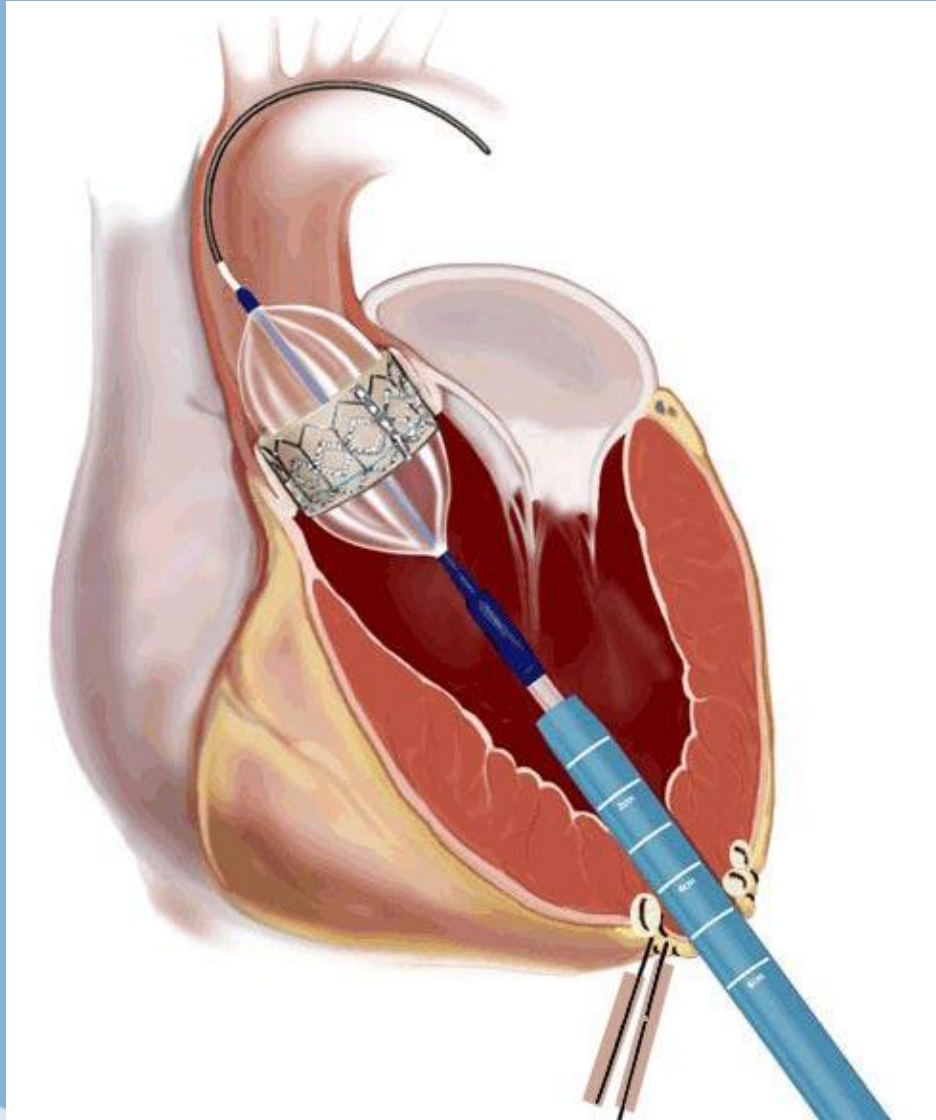
Aorta ascendens vervanging



Kalk.....en dan?

- Tussen de kalkschotsen door
- Liescanulatie? (“Kärcher in de aorta”)
- Off pump (CABG)?
- Aorta ascendens vervanging onder circulatie arrest?
- Sluiten en toch TAVI (aortaklep)?

Trans Apicale Aortaklep (TAVI)



Vragen???