



Tamponade



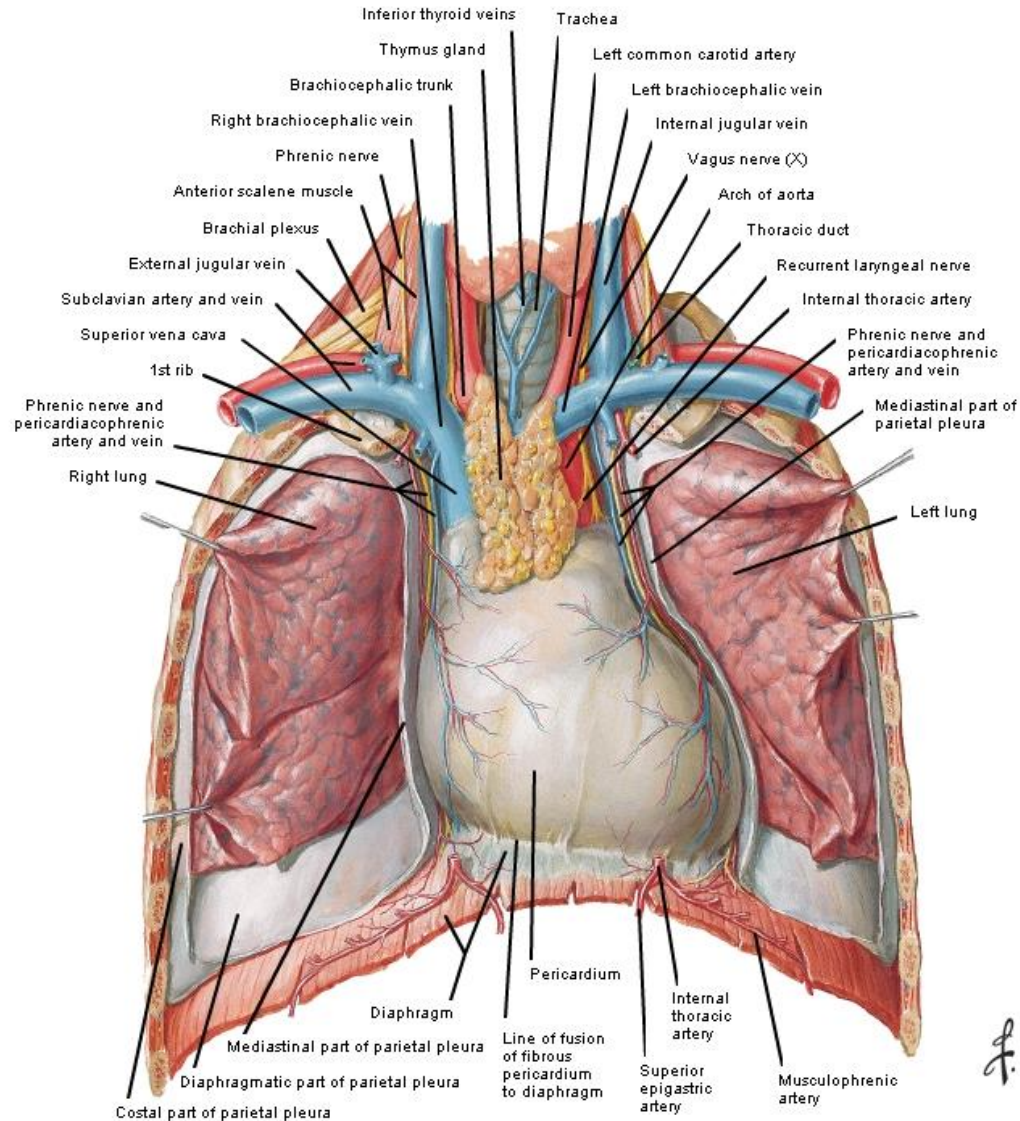
Nederlandse Vereniging
voor Hart en Vaat Verpleegkundigen

15 april 2014

Thanasie Markou
Cardio-thoracaal chirurg

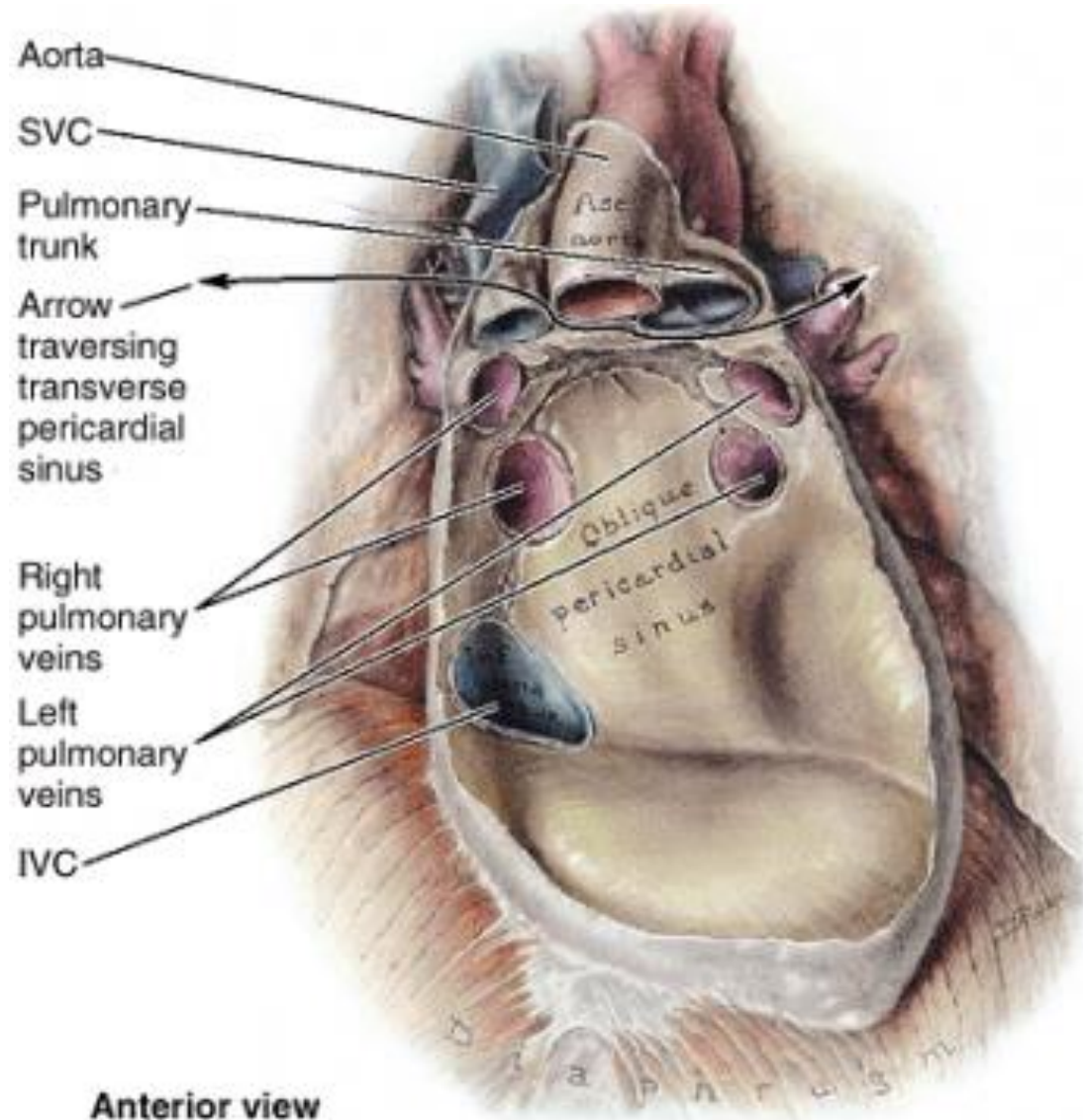
Anatomie

Heart In Situ

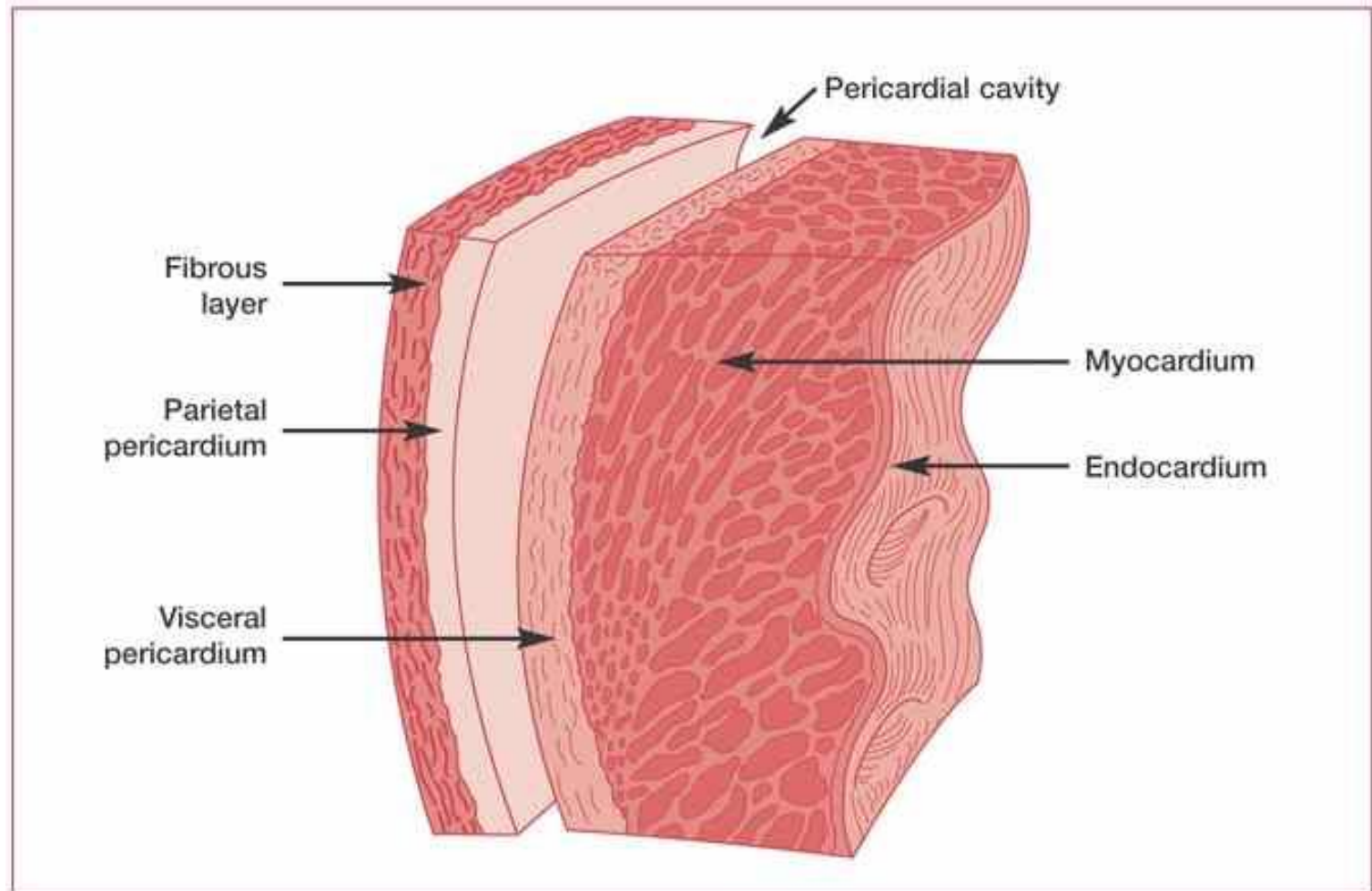


F. Netter
M.D.
© IGM

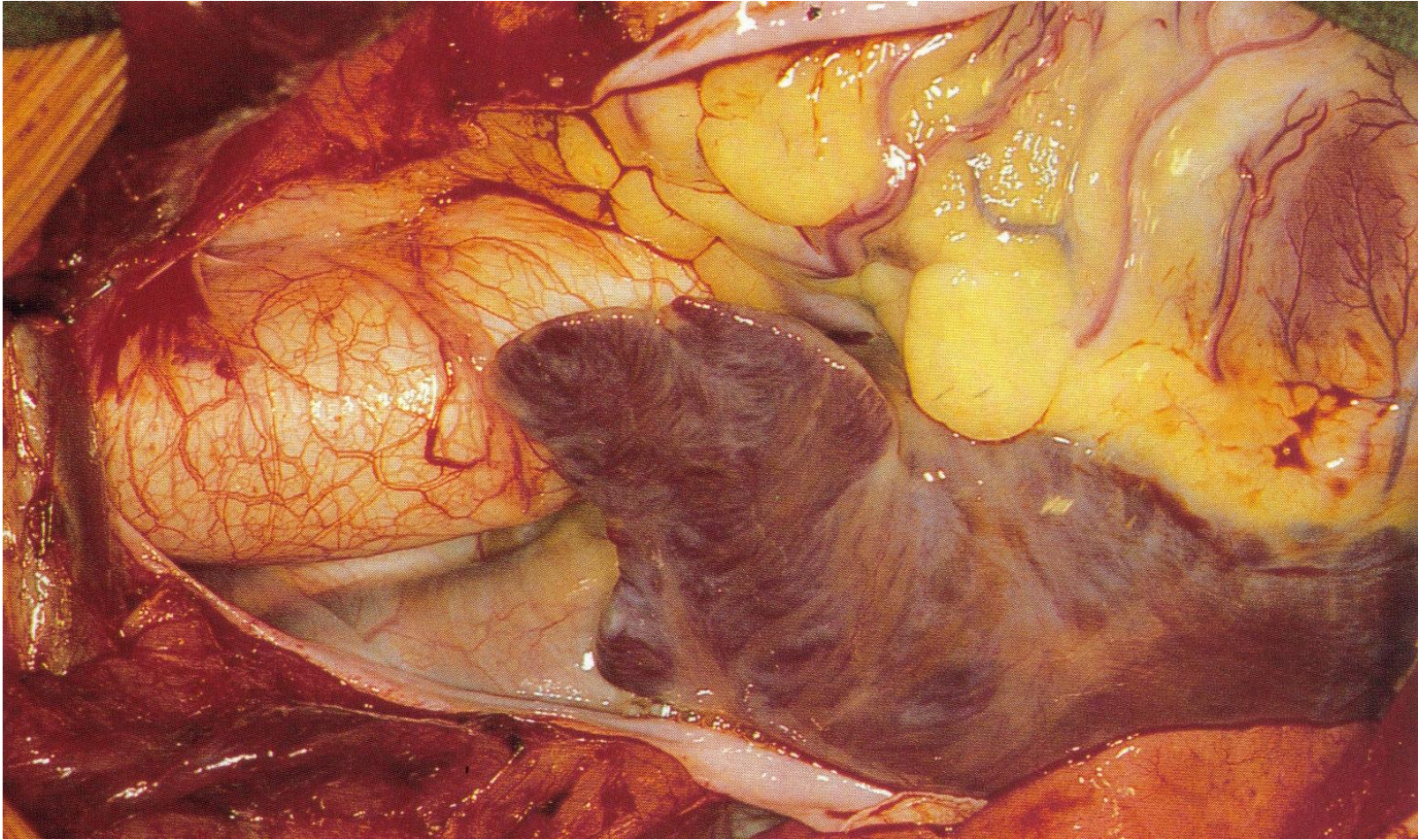
Sinus transversus- en obliquus pericardii



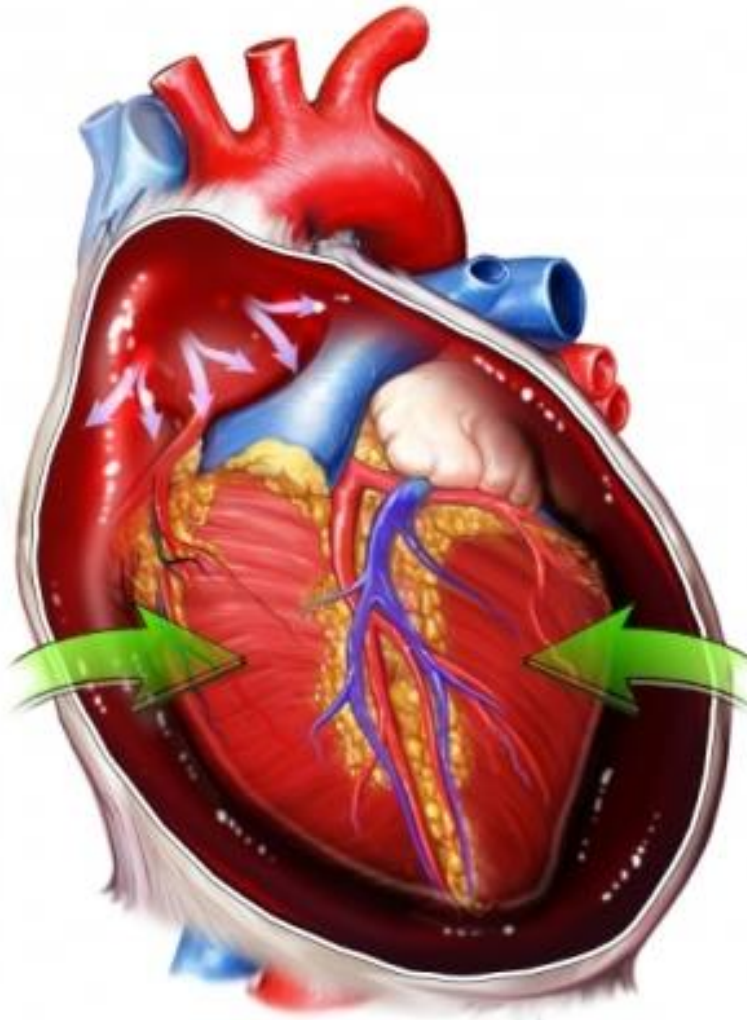
Pericard



Geopend pericard



Pericard effusie ≠ Tamponade

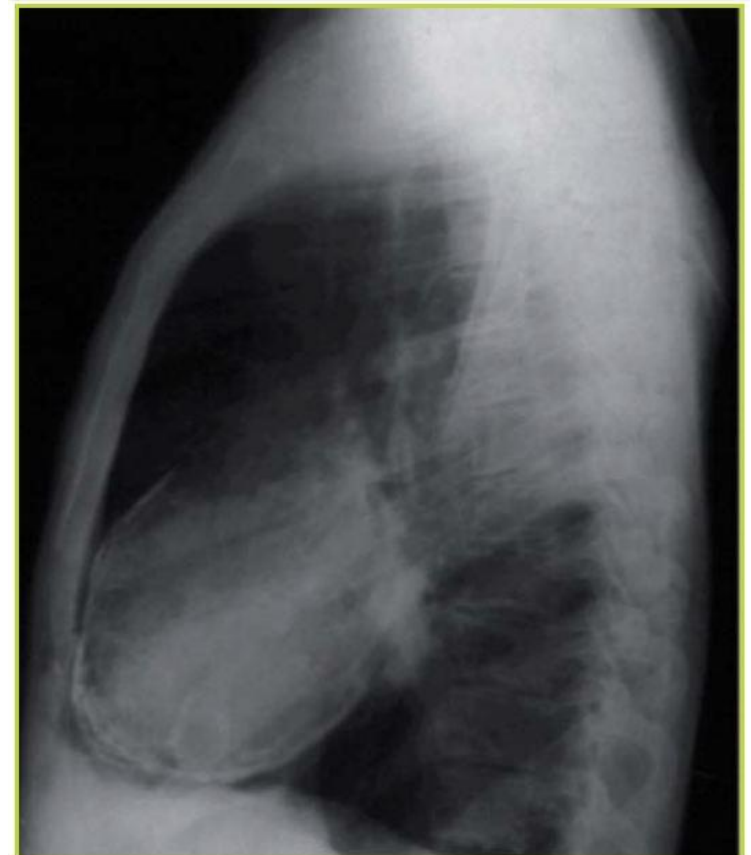
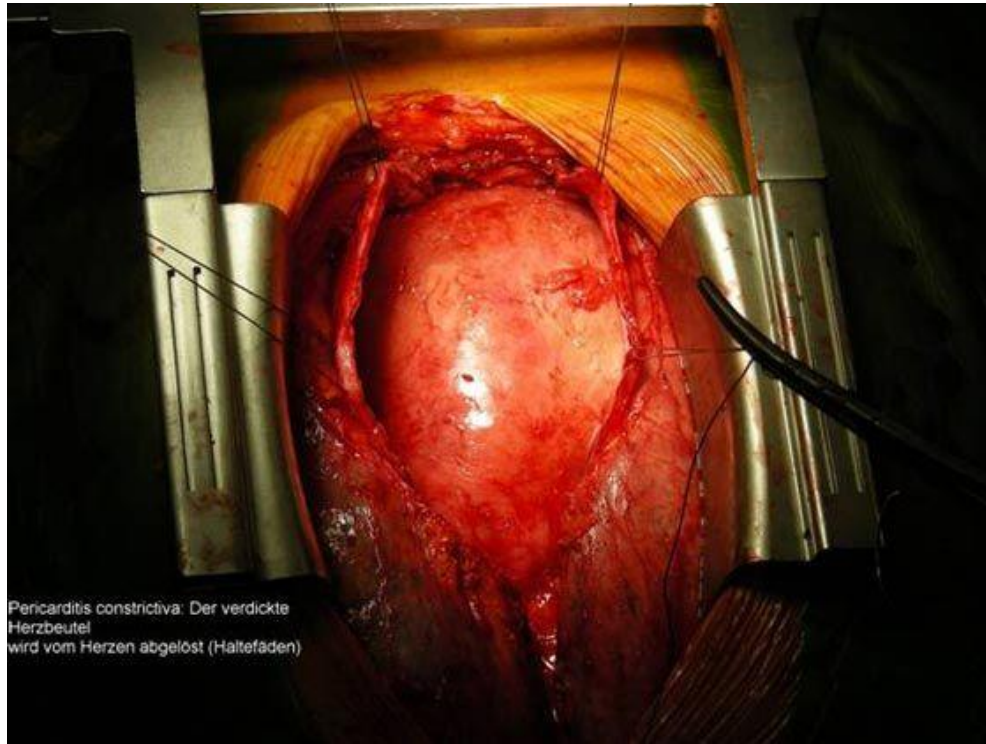

= snelle of langzame opvulling van de pericardiale holte met vocht, bloed, stolsels, lucht of pus

- Haemopericardium
- Pneumopericardium
- Pyopericardium

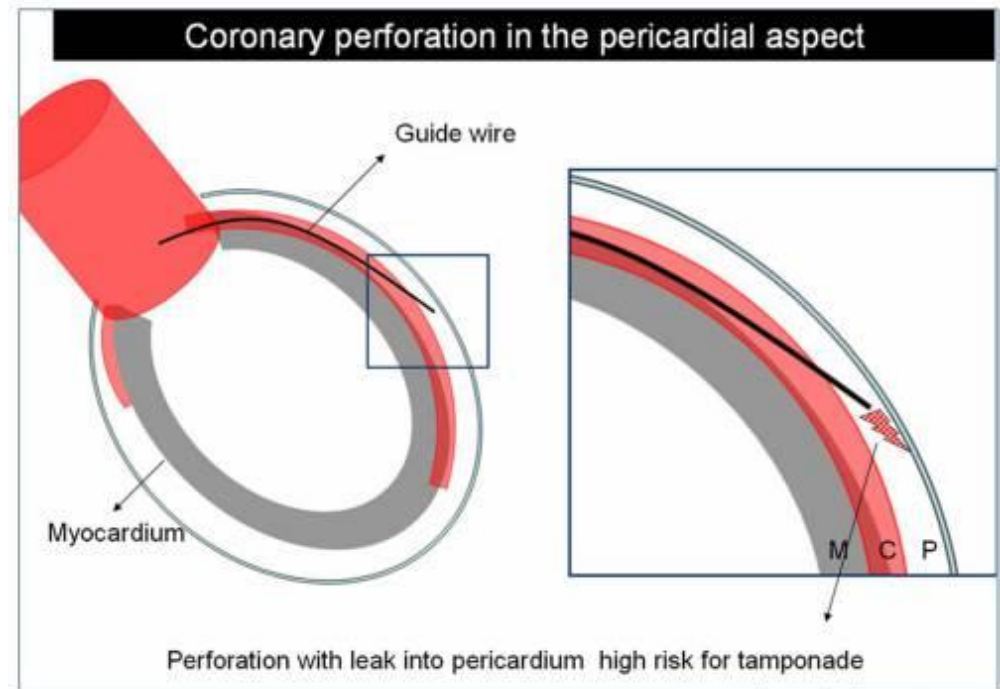
Pericarditis constrictiva

Verlittekening en verlies van elasticiteit van het pericard

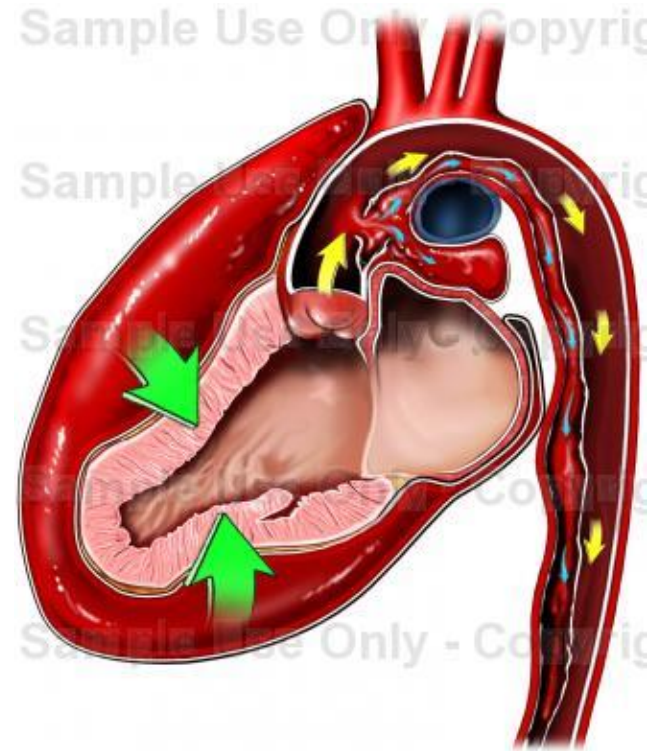
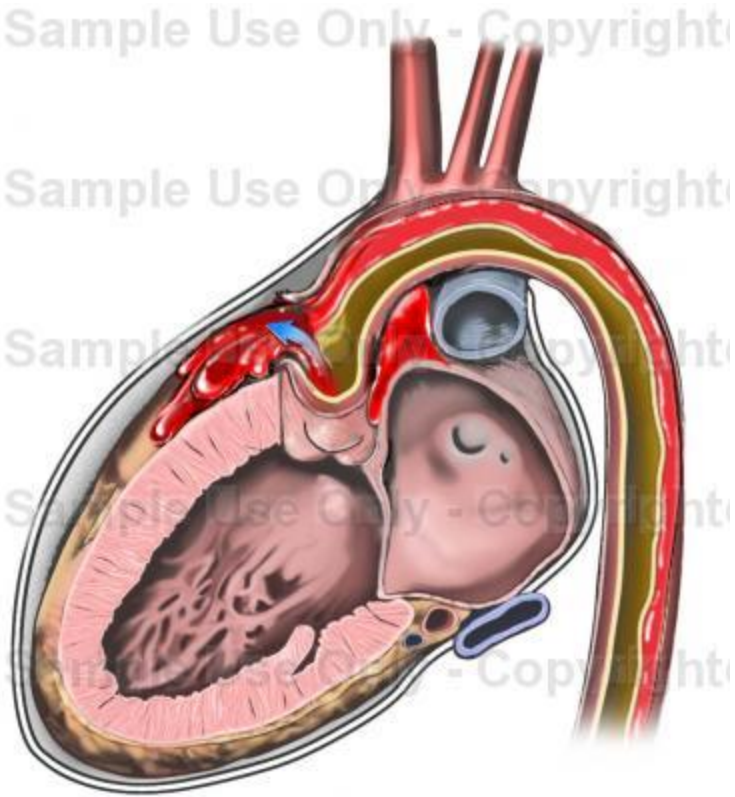


Oorzaken acute tamponade

- **Hartchirurgie**
- Hartinfarct vrije wand ruptuur
- Thoraxtrauma penetrerend/ stomp
- Aorta dissectie Type A
- Na PCI
- Pericarditis
- Maligniteit
- Uremie



Type A aorta dissectie en tamponade

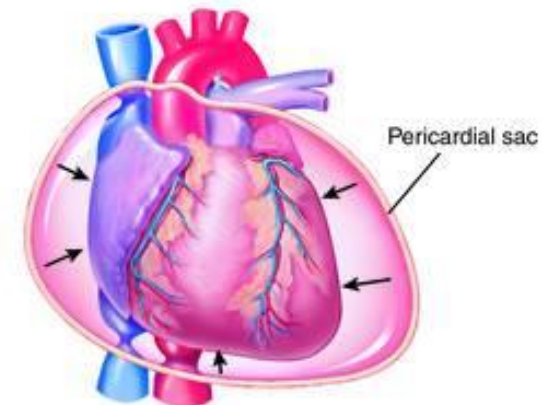
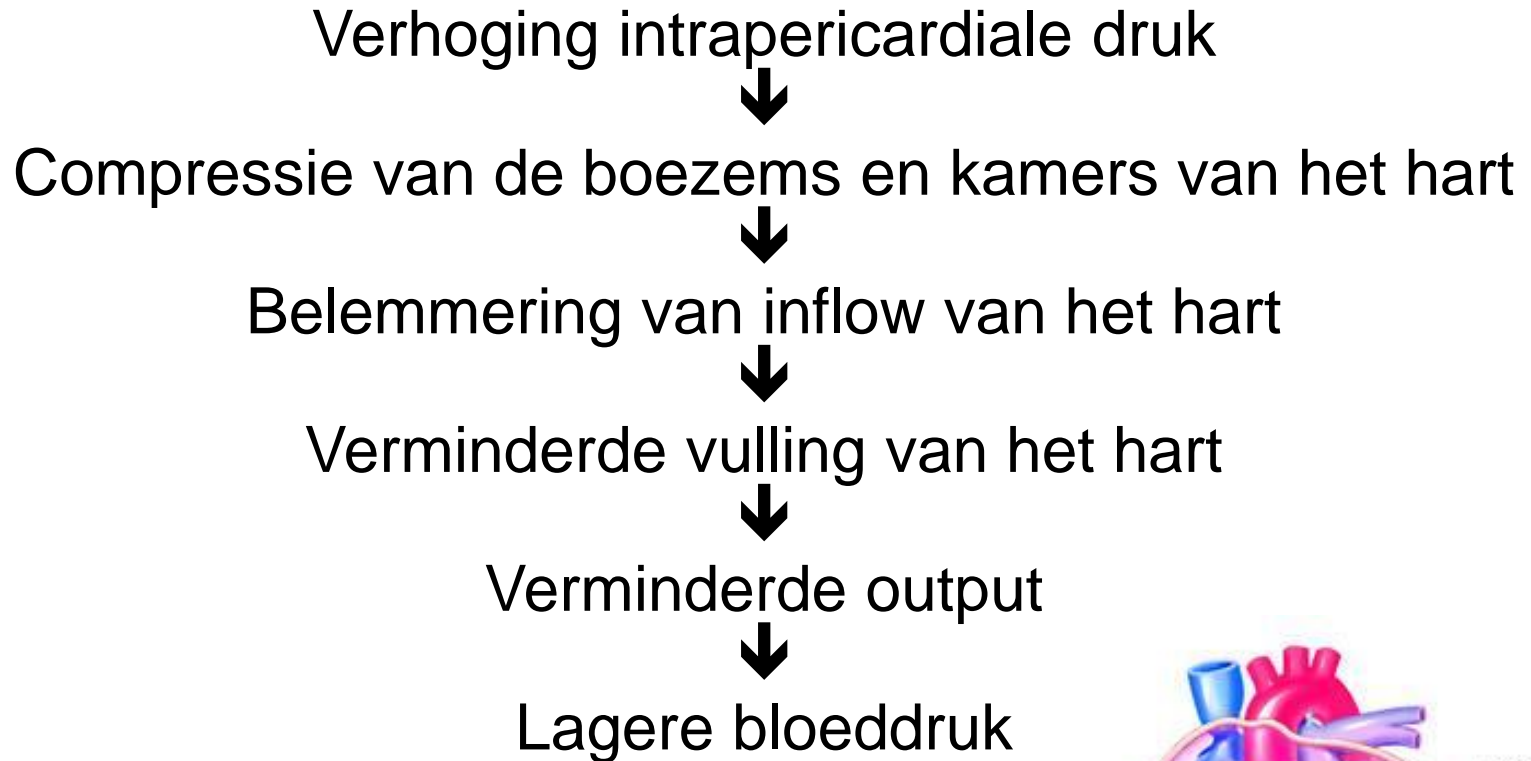


Oorzaken subacute tamponade

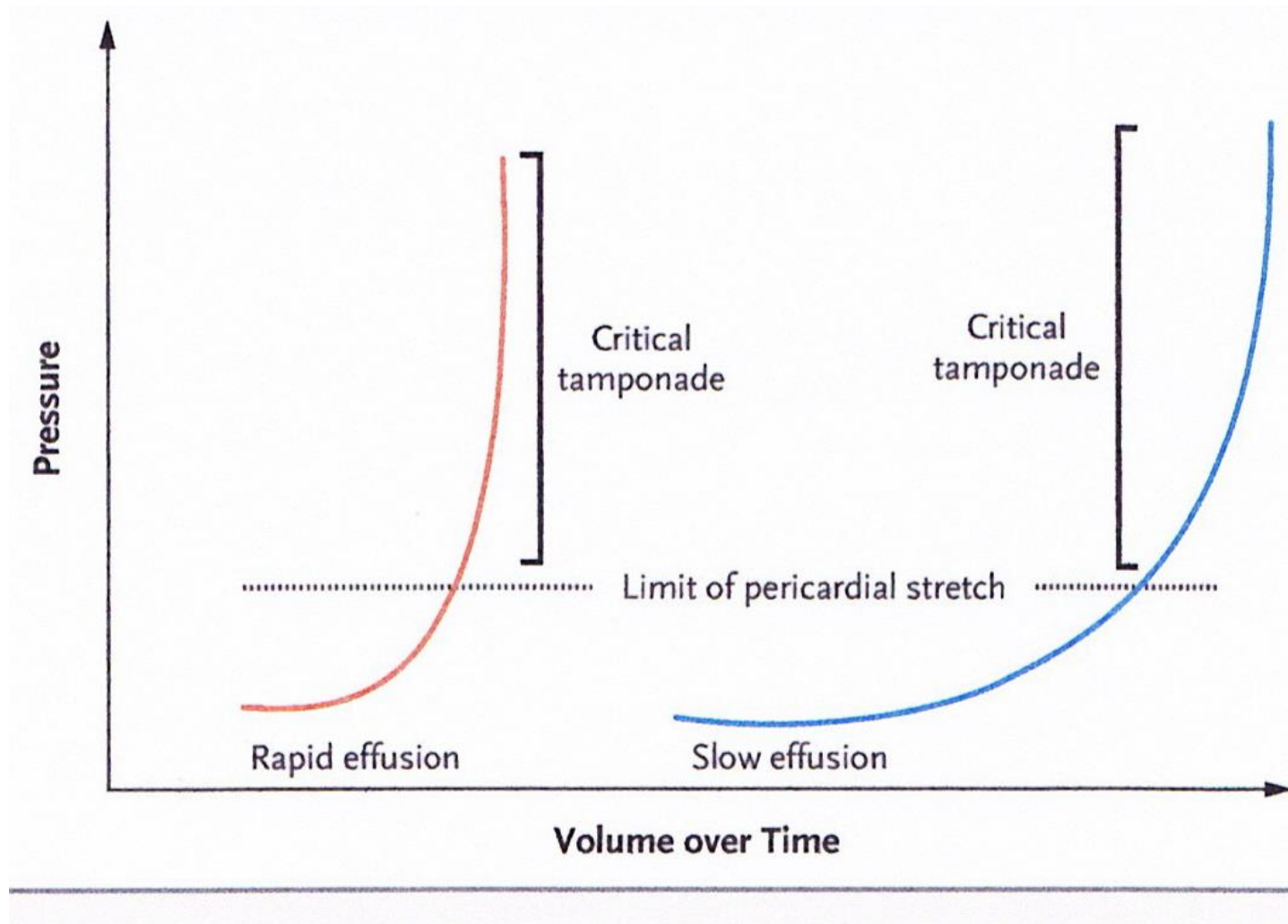
- Dressler syndroom (post MI/ post hartchirurgie)
 - > Pericard effusie post myocardinfarct
 - > Post pericardiotomie
- Infectieus (TBC)
- Maligniteit
- Uremie
- SLE
- HIV
- Idiopathisch

Het hart went **geleidelijk** aan de intrapericardiale druk

Pathofysiologie

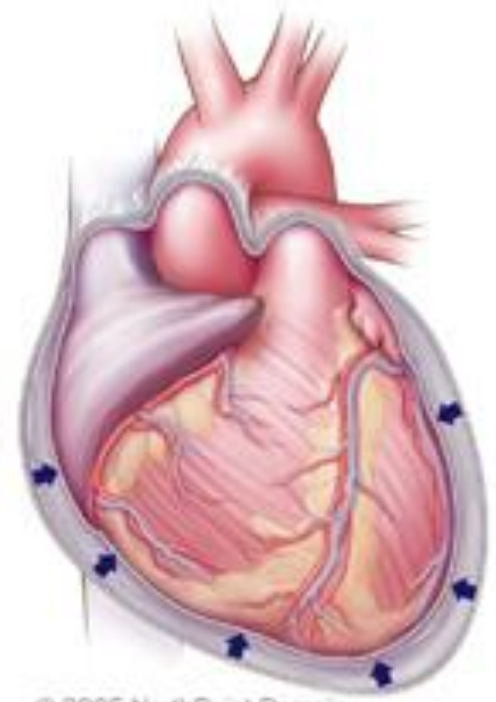

Acute vs. Subacute



Tamponade is.....

1. Een klinische diagnose
2. (Potentieel) levensbedreigend



© 2005 NorthPoint Domain

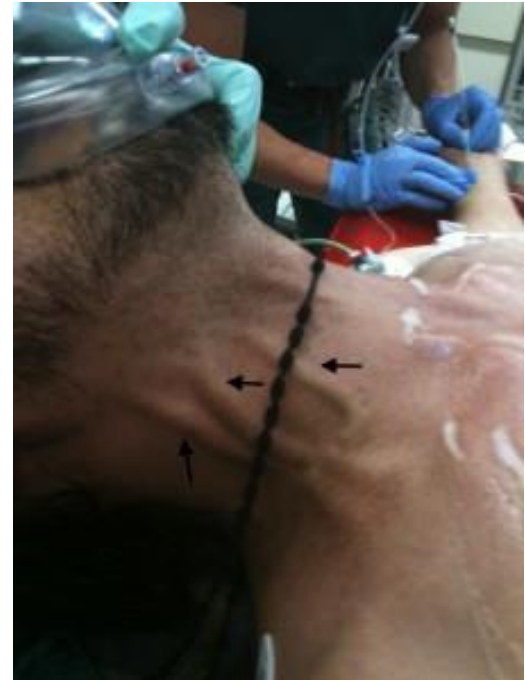Klinisch beeld

Beck's triade

Verlaagde arteriële bloeddruk (laat symptoom)

Verhoogde centraal veneuze druk (liggende patient)

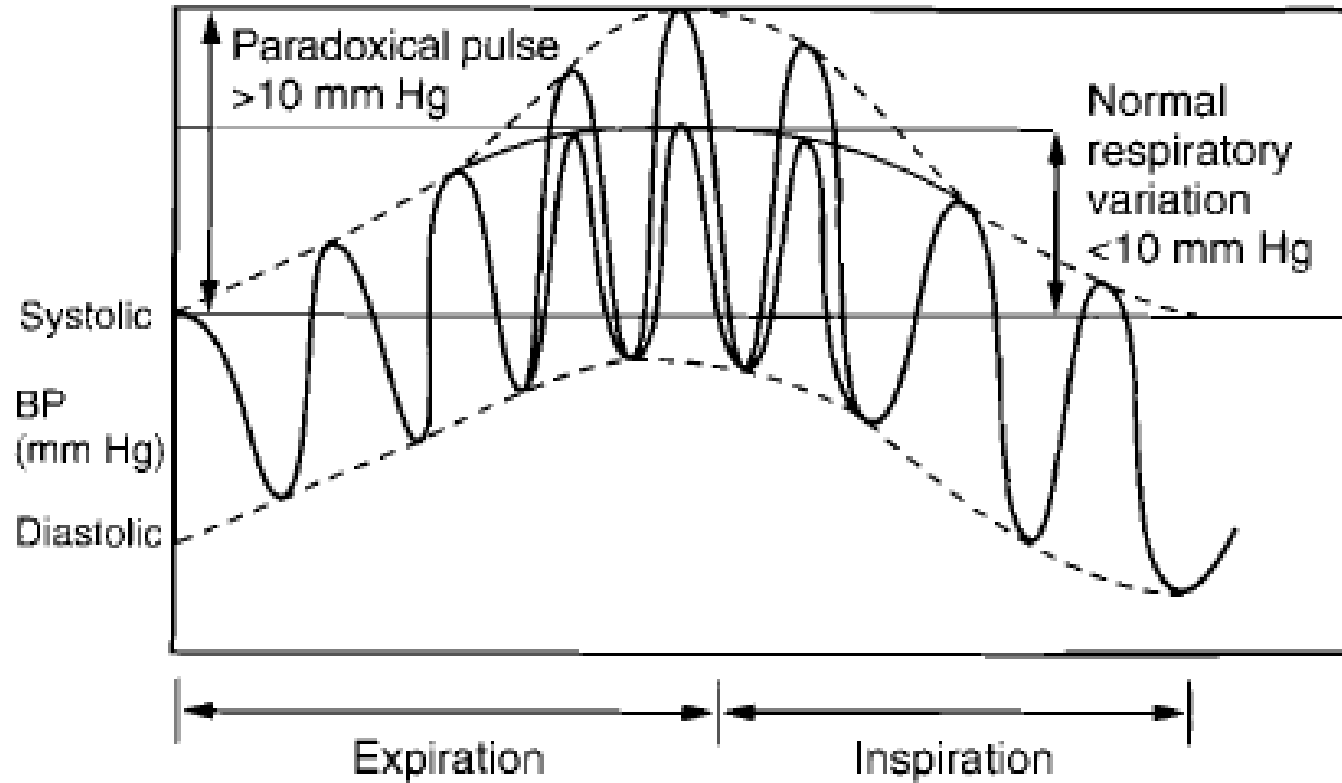
Zachte cortonen (demping)



Klinisch beeld

- Pulsus paradoxus > 10 mmHg RR syst. verlaging bij inademing
- Perifeer koud handen, voeten, acra
- Progressieve dyspnoe
- Verminderde diurese oligurie
- Tachycardie
- Tachypnoeïsch
- Transpireren/ klam

Pulsus paradoxus



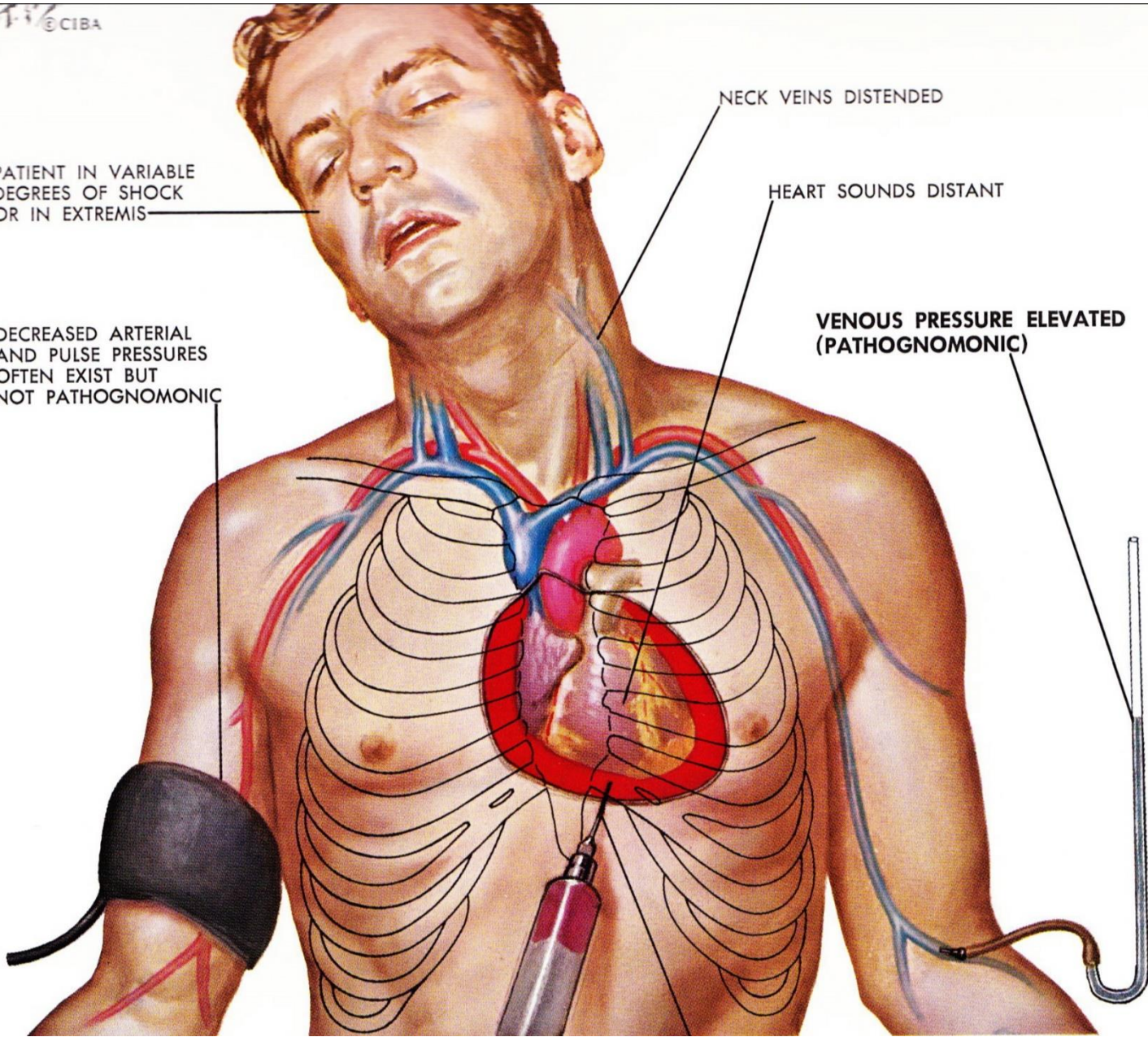
PATIENT IN VARIABLE DEGREES OF SHOCK OR IN EXTREMIS

DECREASED ARTERIAL AND PULSE PRESSURES OFTEN EXIST BUT NOT PATHOGNOMONIC

NECK VEINS DISTENDED

HEART SOUNDS DISTANT

VENOUS PRESSURE ELEVATED (PATHOGNOMONIC)



Diagnostiek: ECG, Lab, ABG

ECG Lage voltages/ microvoltages

Lab Verhoogde leverenzymen

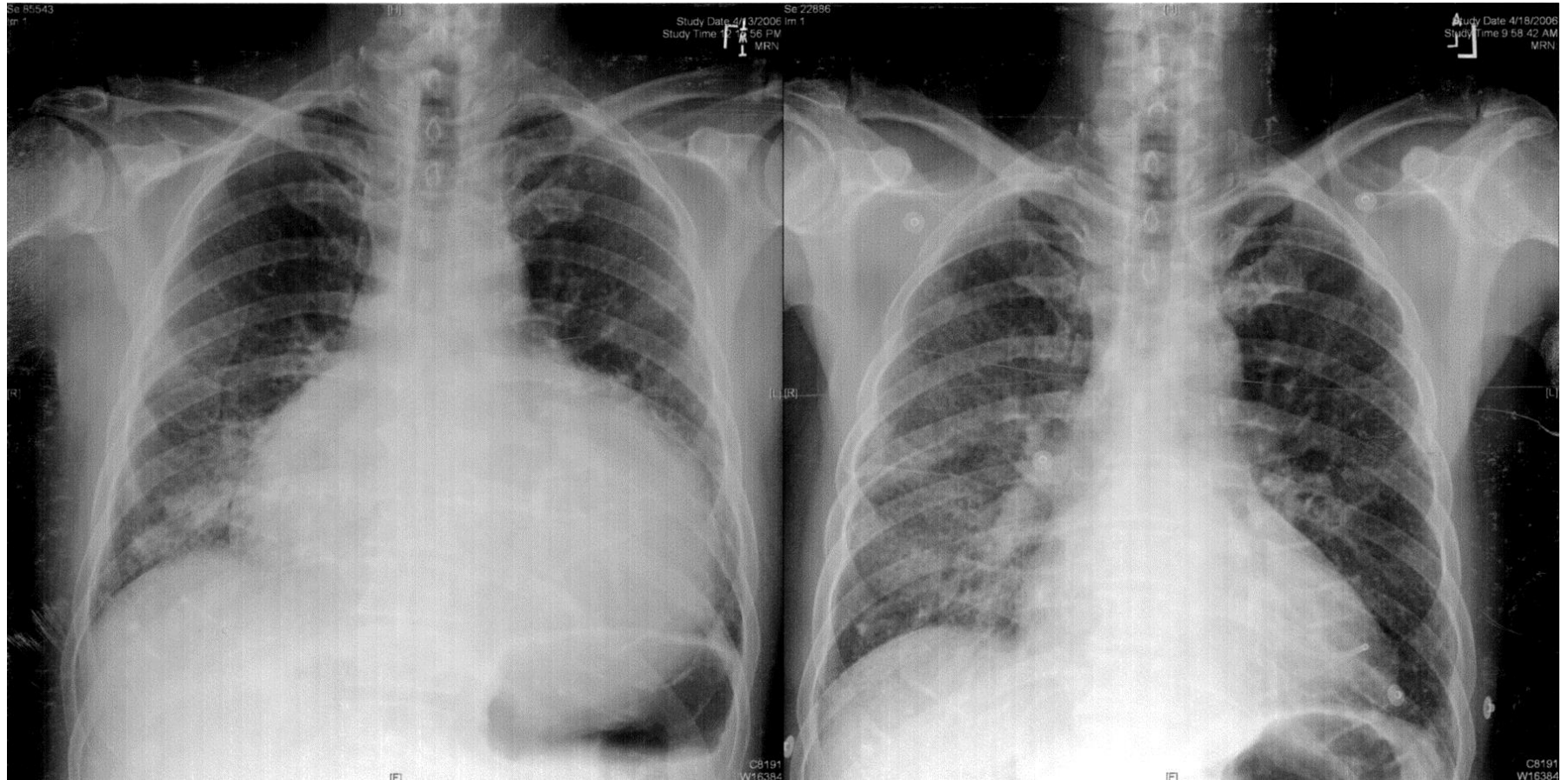
Stijging nierfunctie

Verlaging Hb-gehalte

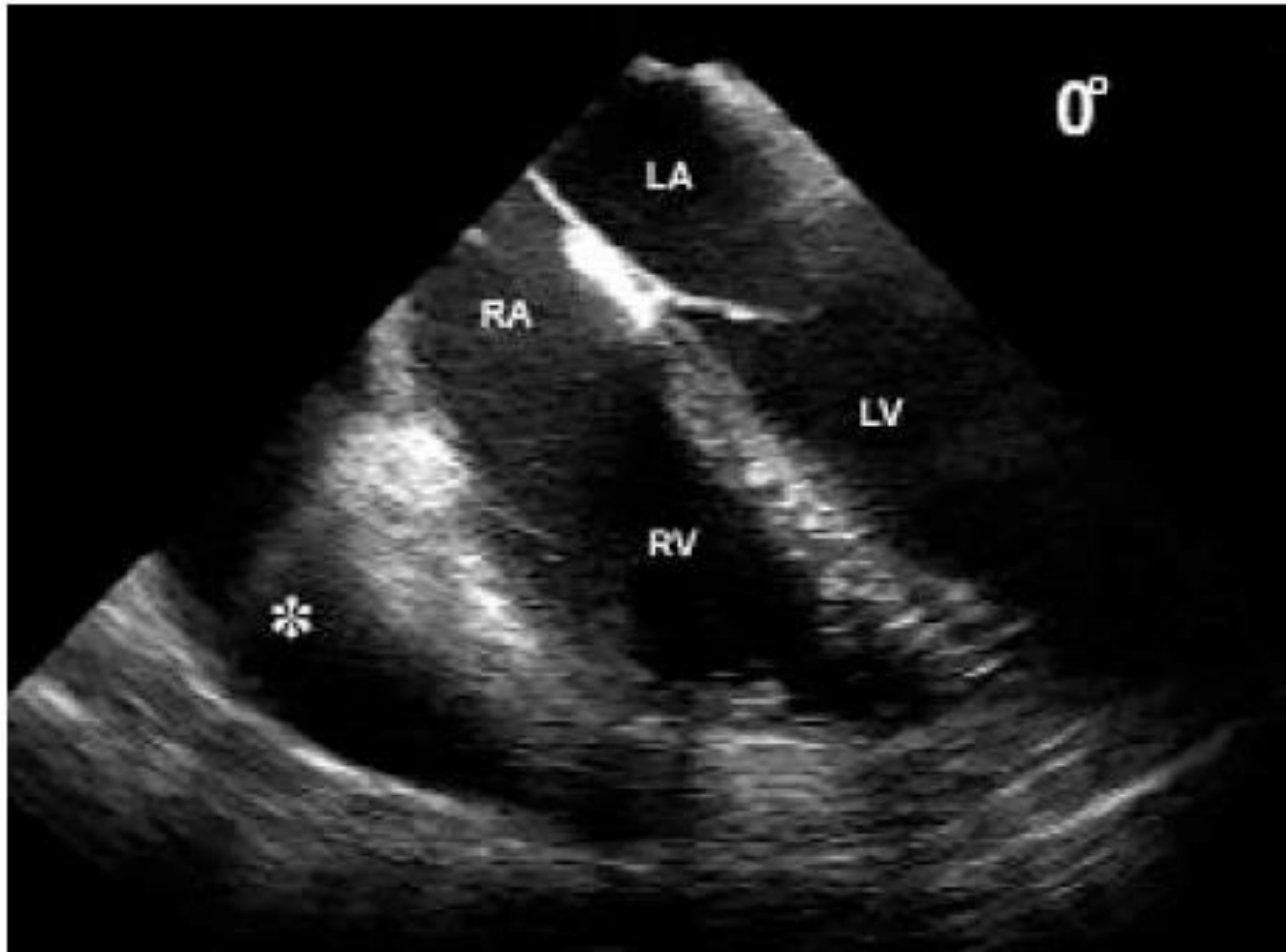
Stijging lactaat

ABG Verzuring, lage pH, lage pCO₂

Diagnostiek: X-Thorax



Diagnostiek: TTE of TEE





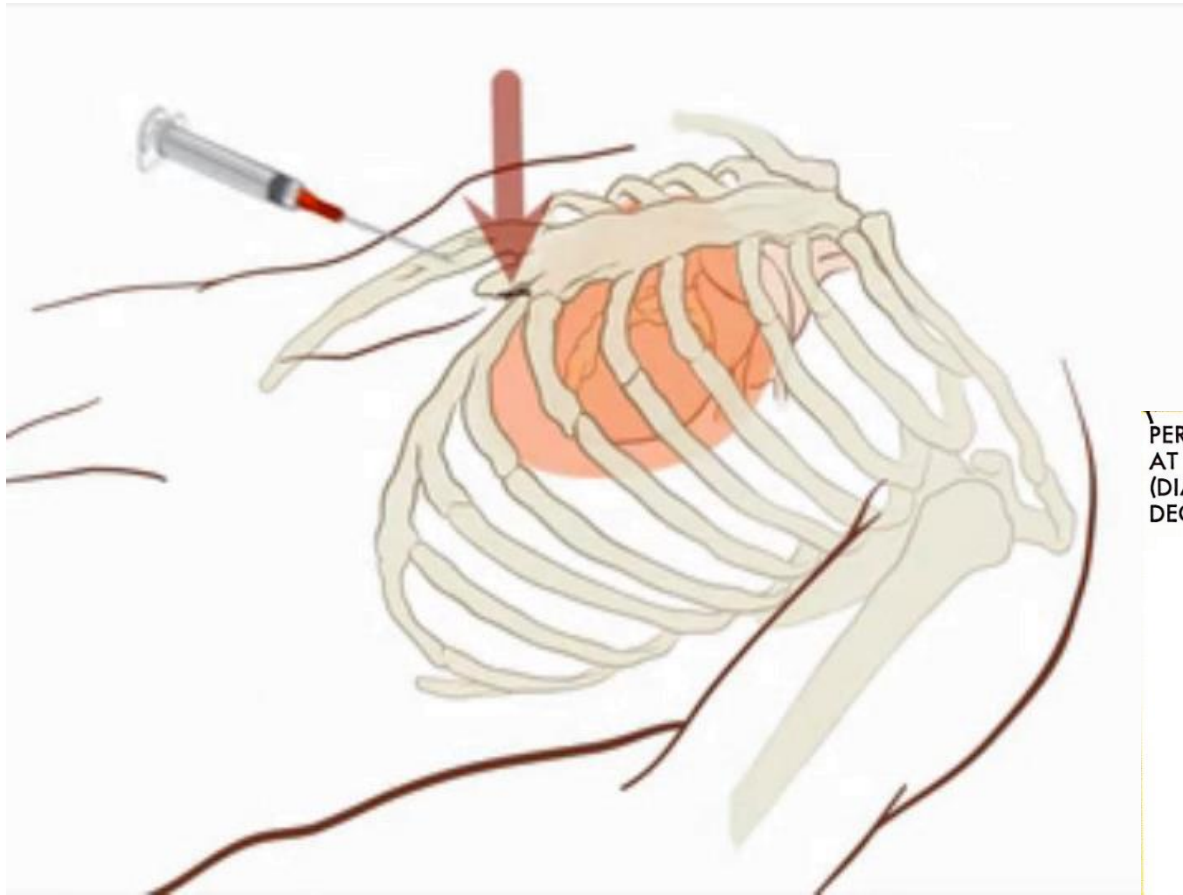
Behandeling Op de afdeling

Vu | | een
Vu | | een
Vu | | een
Vu | | een
Vu | | een

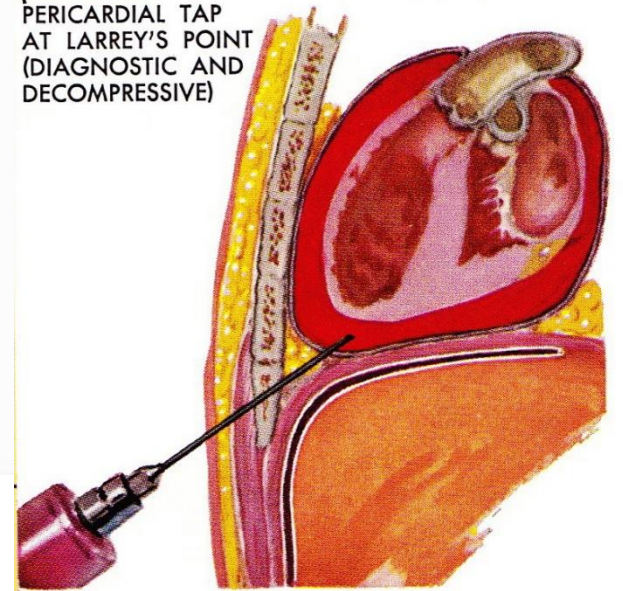
Vu | | een
Vu | | een
Vu | | een
Vu | | een
Vu | | een




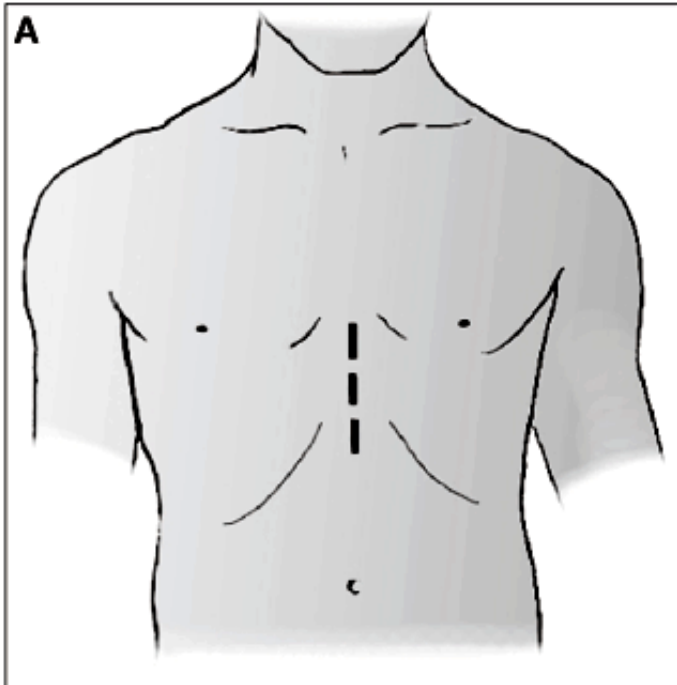
Behandeling pericardiocentese



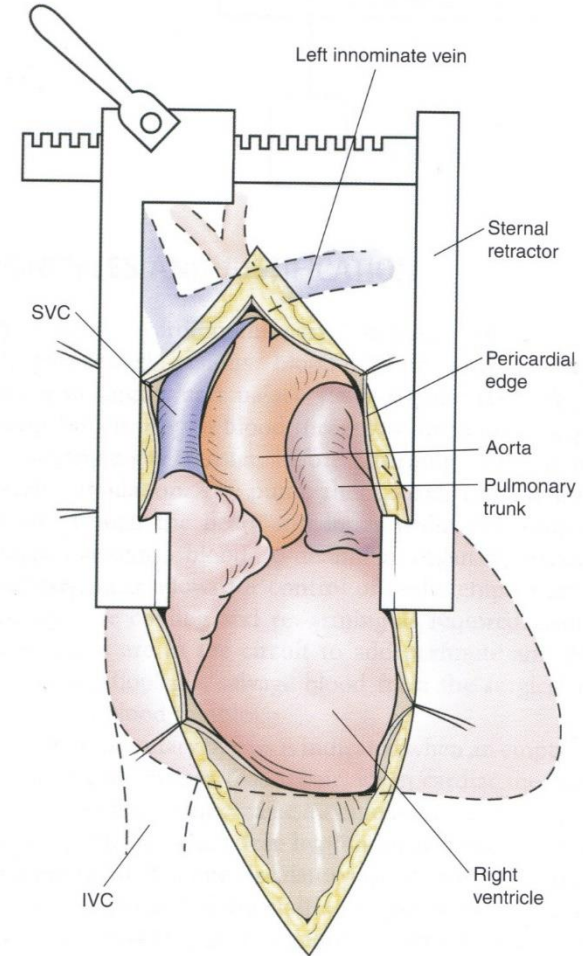
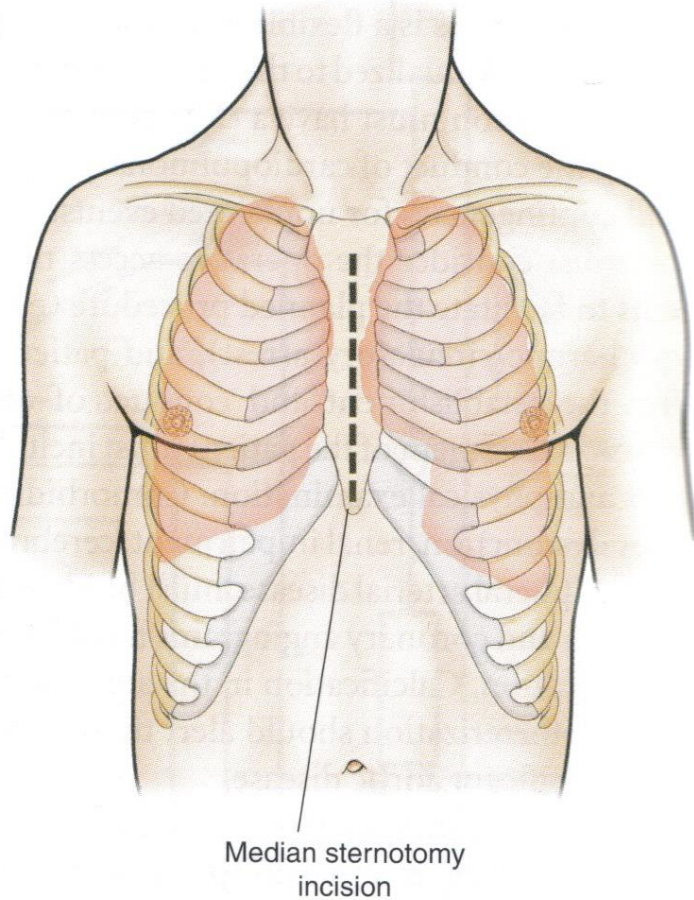
PERICARDIAL TAP
AT LARREY'S POINT
(DIAGNOSTIC AND
DECOMPRESSIVE)



Behandeling subxiphoidale pericarddrainage

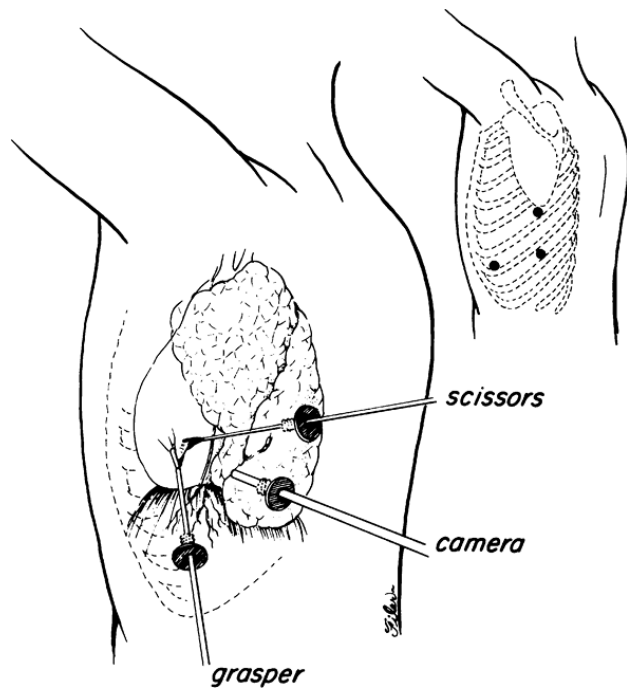


Behandeling: rethoracotomie en pericarddrainage

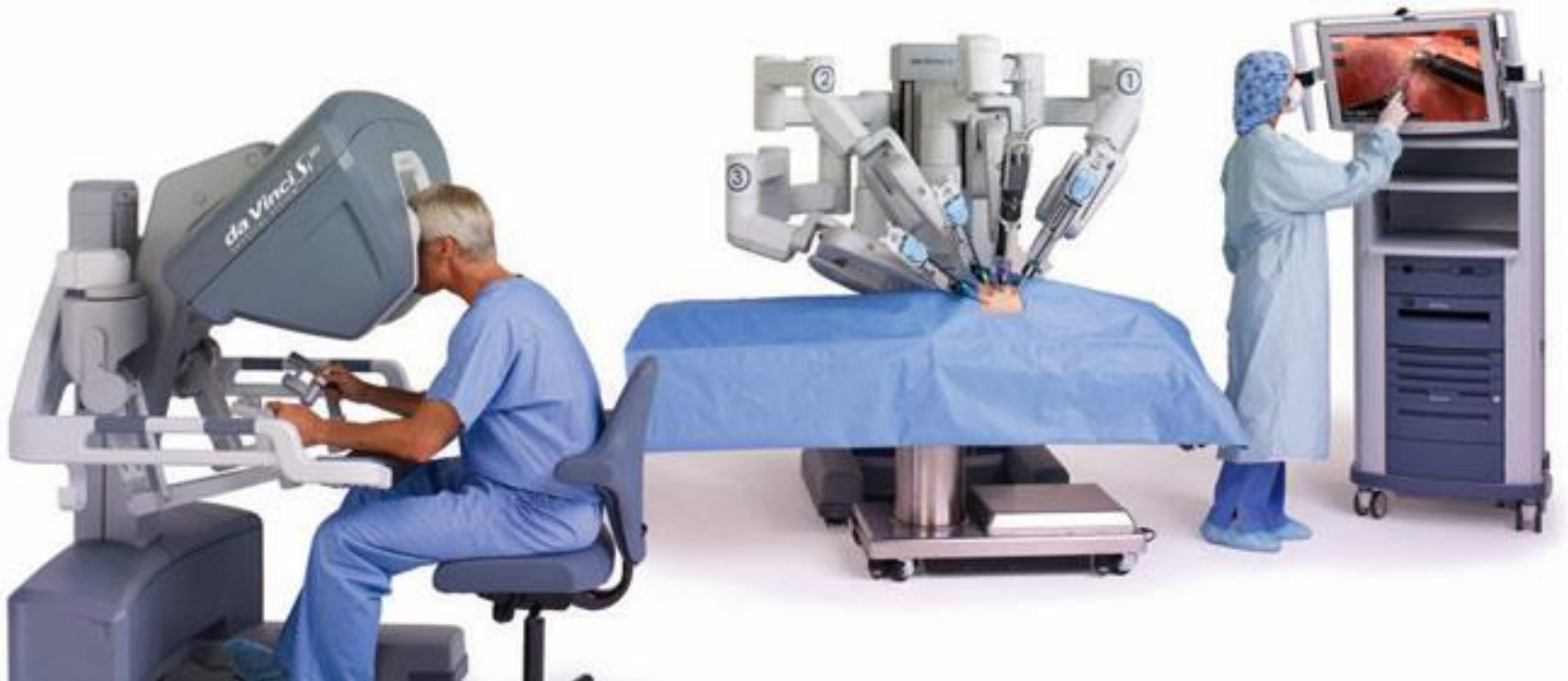

Scopische drainage pericard

Subacute pericardeffusie



Robot geassisteerde pericarddrainage



Take Home Message!!

