



Complicaties van acuut myocardinfarct

diagnostiek middels echocardiografie

CNE Acute Cardiale Zorg

10-05-2016

Dr. O.Bondarenko, cardioloog

mcl

■ medisch centrum
leeuwarden



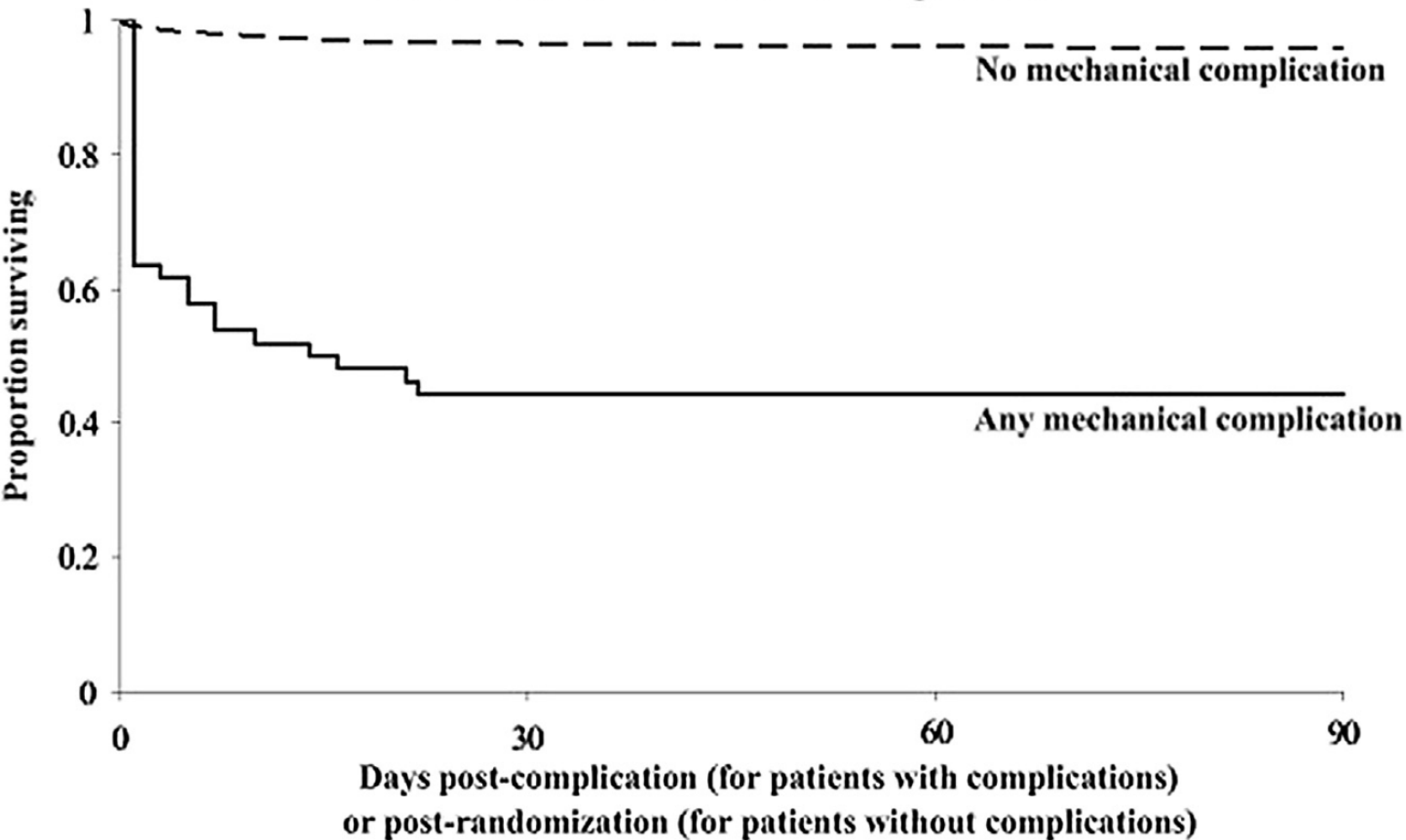
Complicaties AMI

- Ischemisch
- Mechanisch
- Arrhythmie
- Embolie
- Inflammatie

Mechanische complicaties

- **Ventrikel septum ruptuur**
- **Papillair spier ruptuur**
- **Vrije wand ruptuur**
- **Cardiogene shock**
- **LV outflow tract obstructie**
- **RV infarct**

Survival after mechanical complication

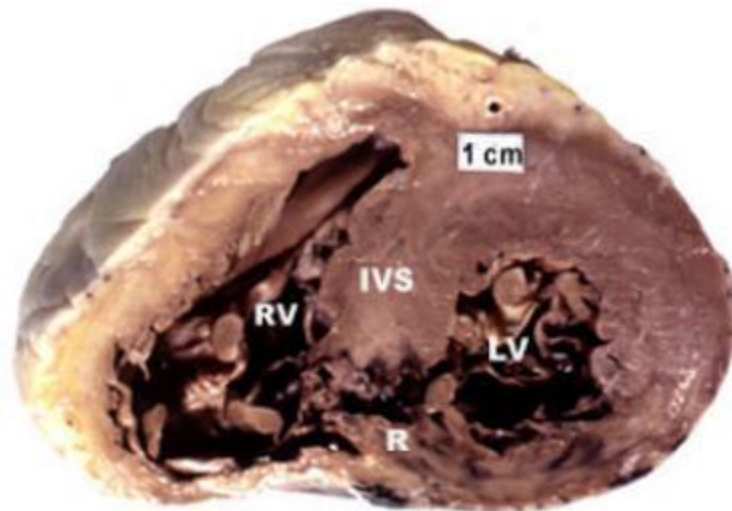


mcl

medisch centrum
leeuwarden



VSR



mcl

medisch centrum
leeuwarden

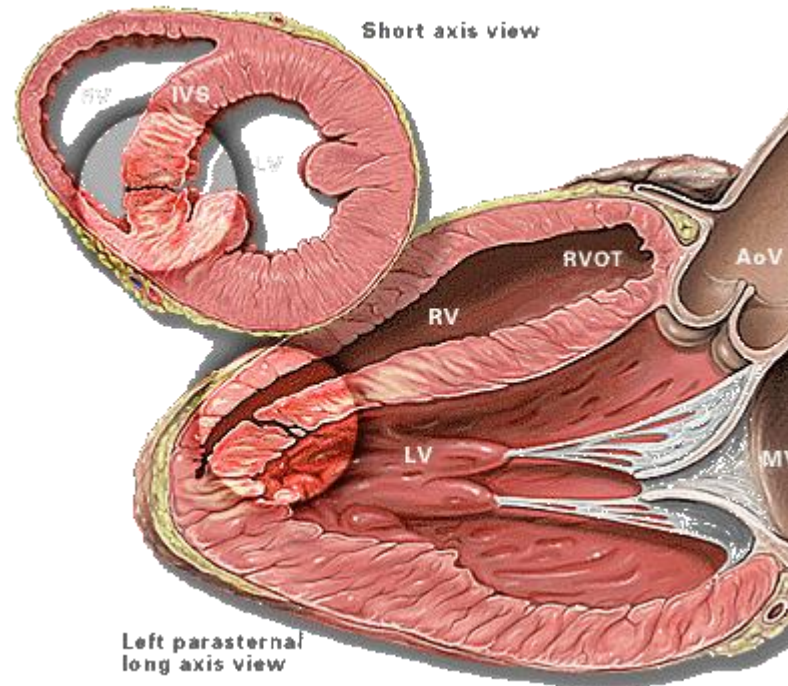


Table I Ventricular septal rupture incidence, time to identification, and resultant mortality in four contemporary clinical series compared with historical data

Source	MI treatment (overall cohort)	Incidence of VSR, % (n)	Time to VSR identification	Mortality, %
Historical data	Pre-thrombolysis	1–2	3–5 days	With surgery: 45 Without: 90
MIDAS ² 1990–2007 n = 148 881 patients with STEMI	PCI (19%)	0.25–0.31 (408)	Not reported	In-hospital: 1990–92: 41 2005–07: 44 1-year: 1990–92: 60 2005–07: 56
GUSTO-1 ³ 1990–1993 n = 41 021 patients with STEMI	Thrombolysis (100%)	0.20 (84)	1 day (range 0–47) (94% ≤ 1 week)	30-day: with VSR: 73.8 without VSR: 6.8
GRACE ⁴ 2000–2007 n = 60 198 patients with ‘ACS’	Primary PCI (15% overall; 38% for STEMI) Lysis (12% overall; 28% for STEMI)	0.25 (155)	Not reported	In-hospital: 41
APEX-AMI ⁵ 2004–2006 n = 5745 patients with STEMI	Primary PCI (94%)	0.17 (10)	7.7 h (range 5.5–23.5)	30-day: 80

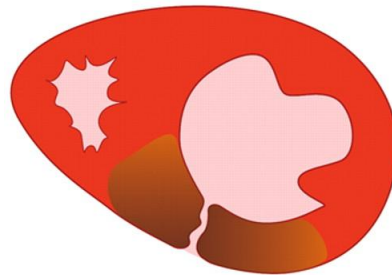VSR, ventricular septal rupture; MI, myocardial infarction; PCI, percutaneous coronary intervention.

VSR Lokalisatie

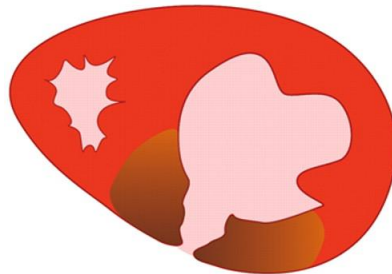

Classificatie

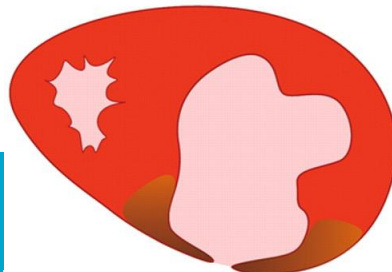Free Wall Rupture



Type 1



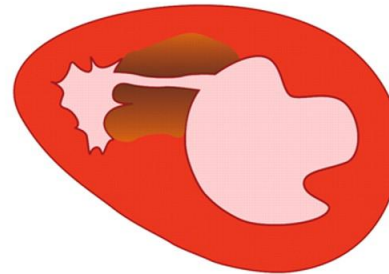
Type 2



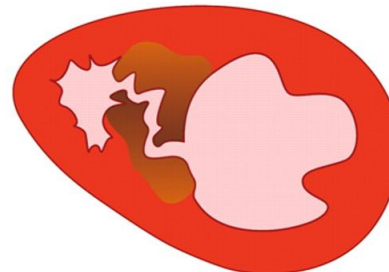
Type 3

Ventricular Septal Rupture

Simple



Complex



Klinische presentatie

- Hemodynamische stabiliteit



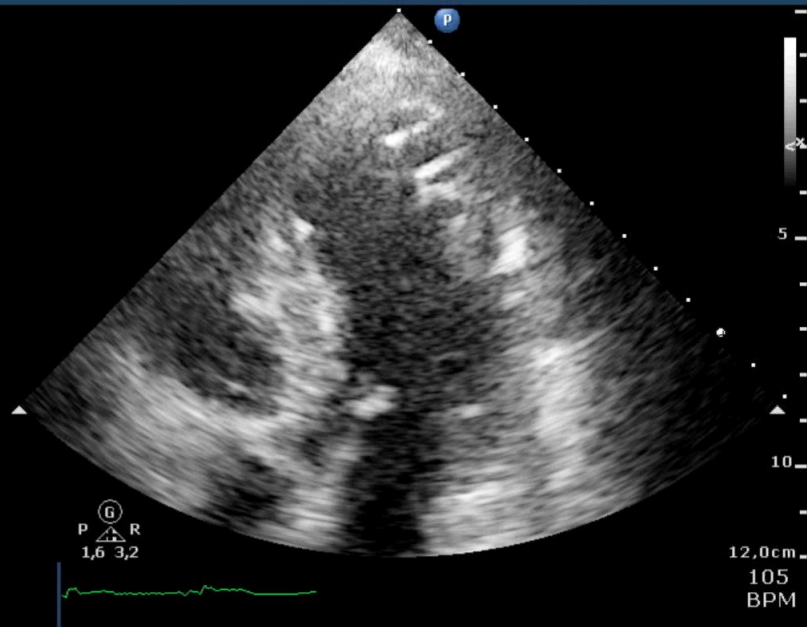
- Circulatoire collaps

Diagnostiek

- Auscultatie
- Echo
- Hartcatheterisatie

MCL
S5-1
39 Hz
12,0cm

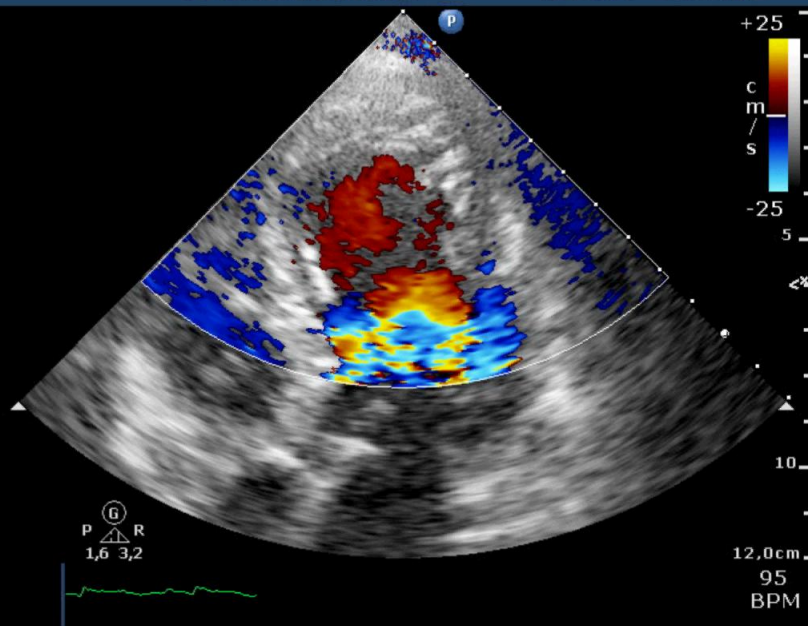
2D
HGen
Gn 44
C 52
3 / 2 / 1
50 mm/s



MCL
S5-1
11 Hz
12,0cm

2D
HGen
Gn 44
C 52
3 / 2 / 0
50 mm/s

Color
2,5 MHz
Gn 67
4 / 4 / 0
Fltr High

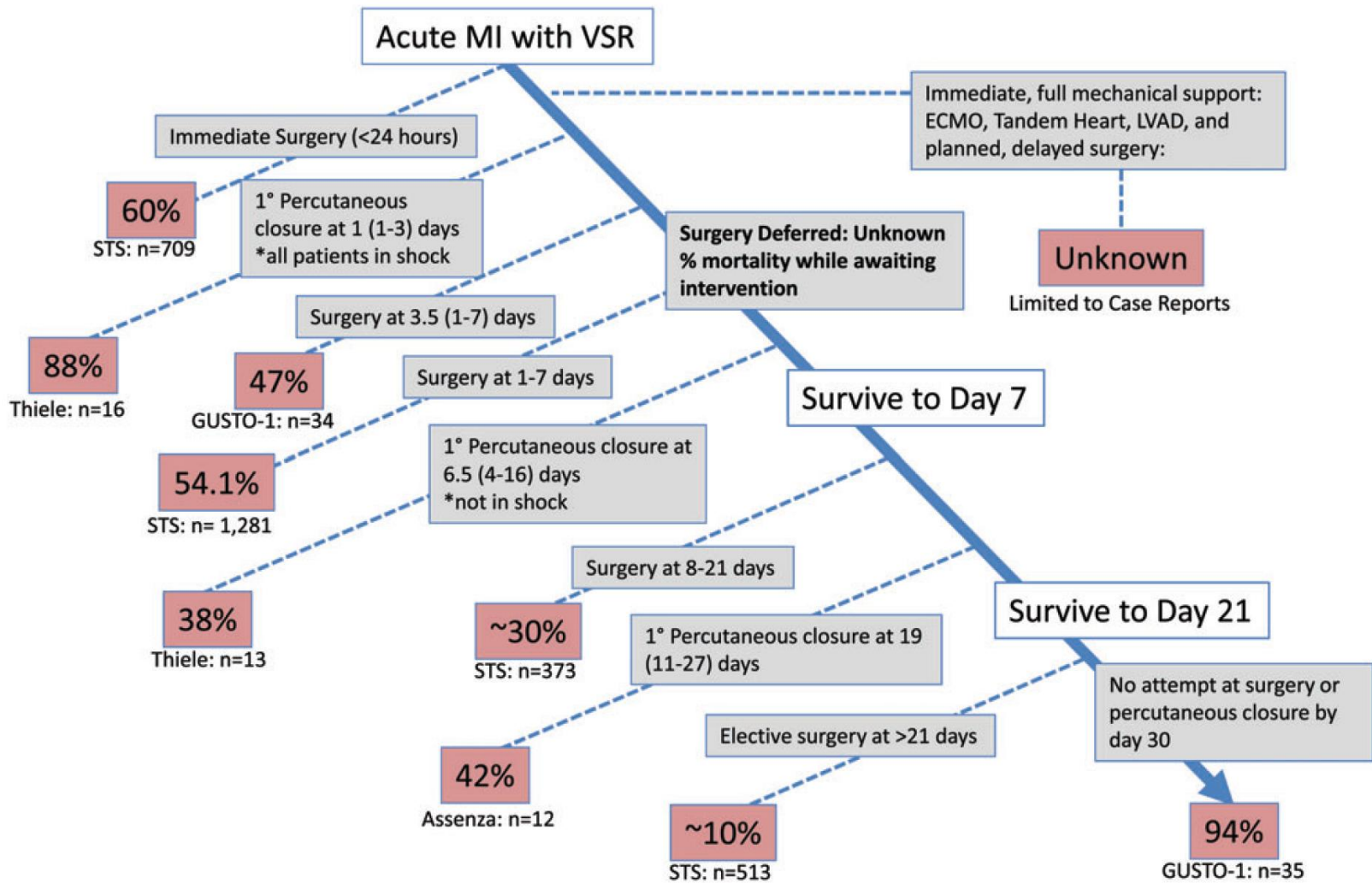


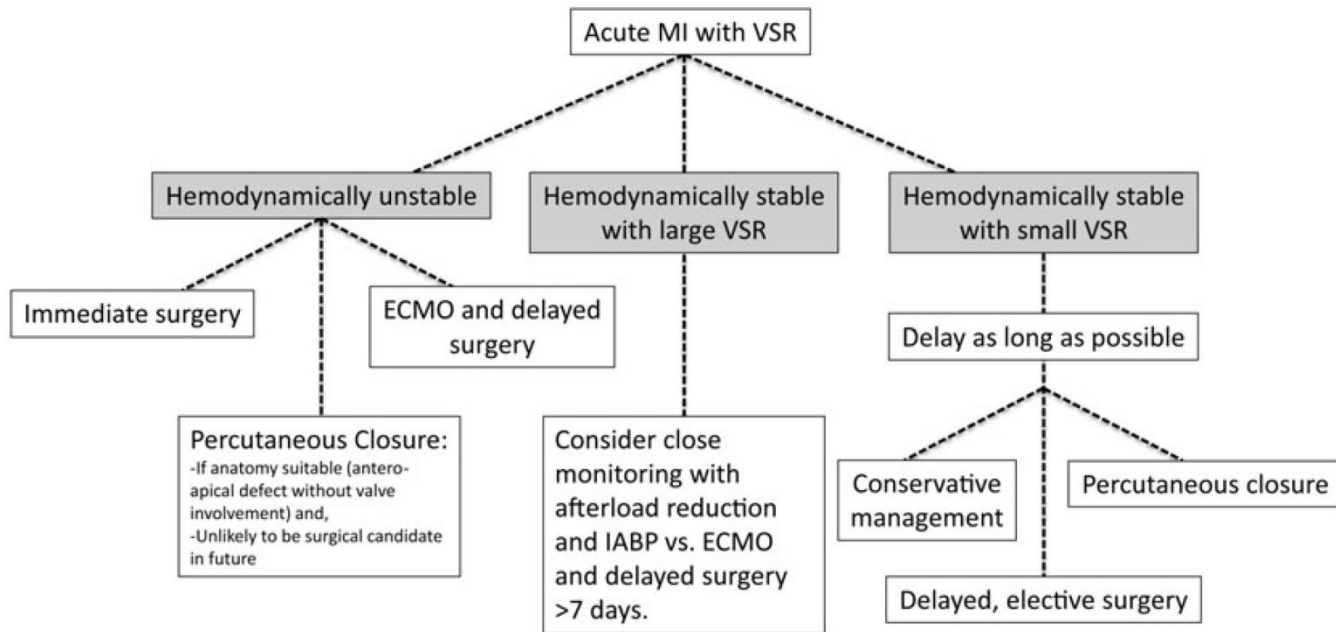
mcl

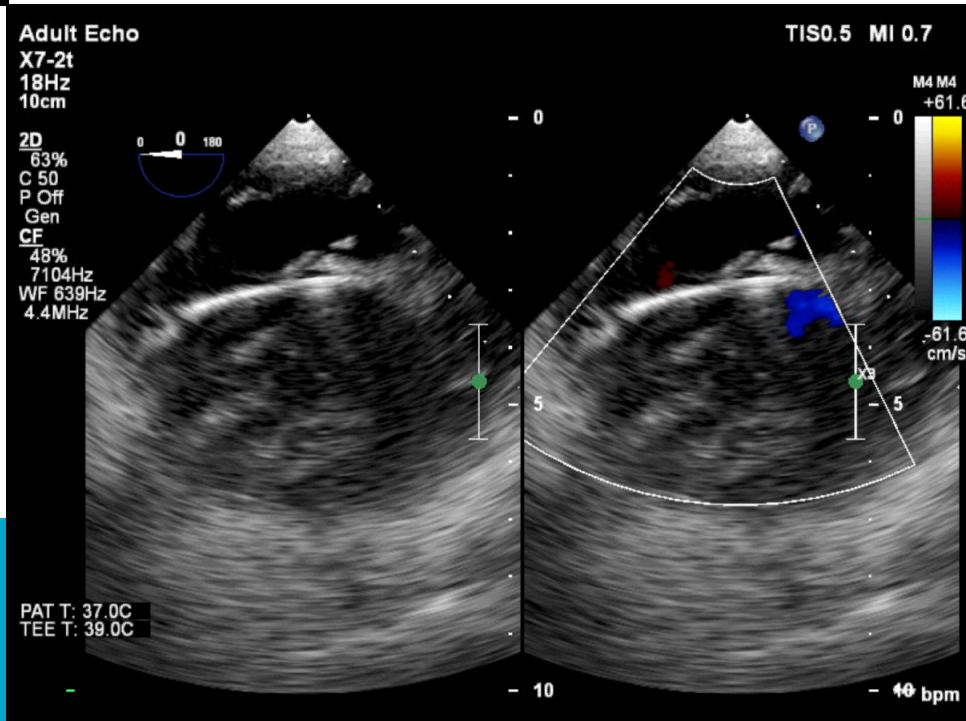
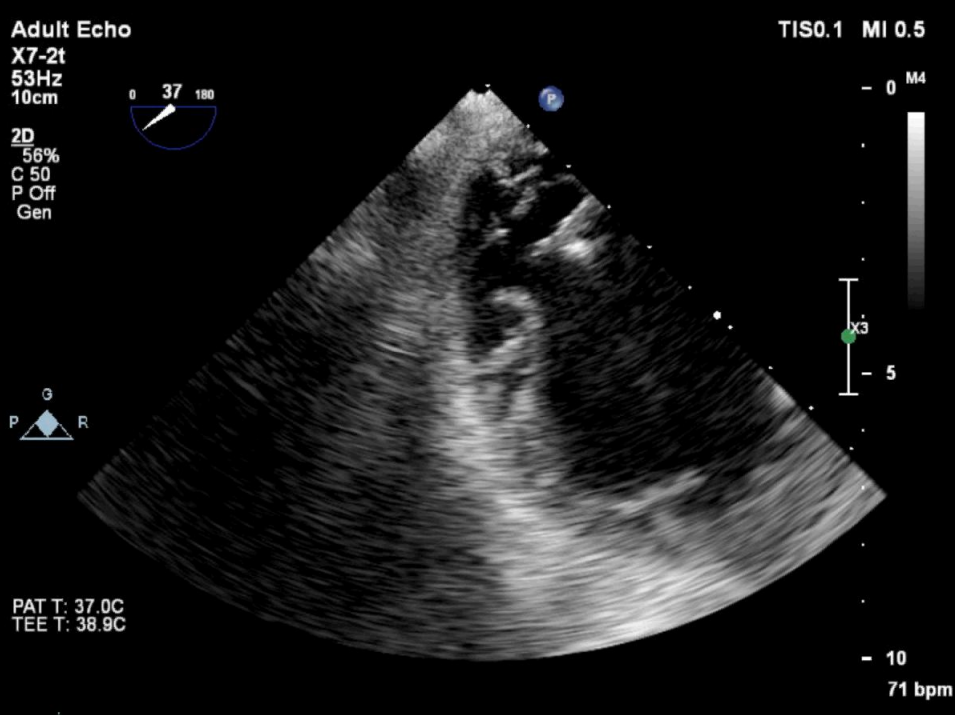
medisch centrum
leeuwarden

Behandeling

- Chirurgisch
- Percutaan



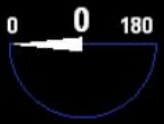



Adult Echo
X7-2t
12Hz
4.6cm


3D Beats 1

TIS0.1 MI 0.4

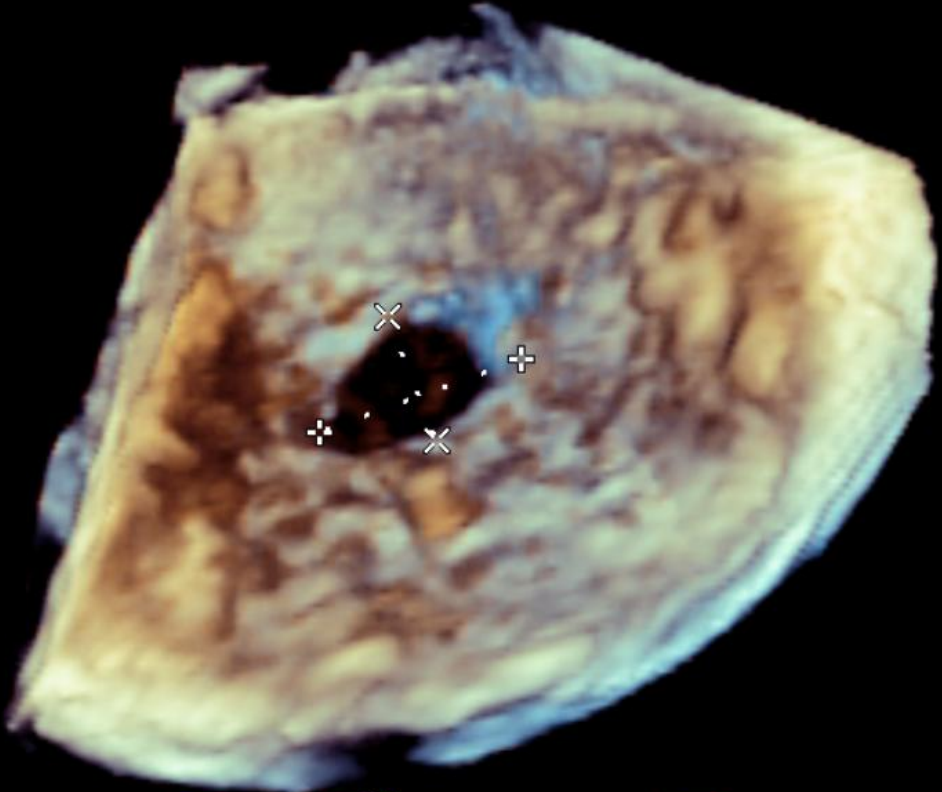
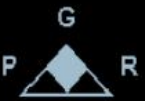

+ Dist 1.06 cm
x Dist 0.659 cm

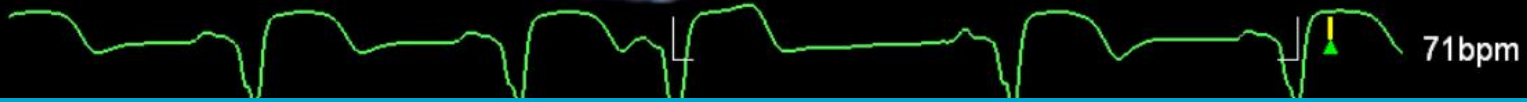M4



3D Zoom
2D / 3D
% 57 / 55
C 50 / 30
Gen



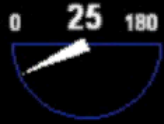PAT T: 37.0C
TEE T: 38.5C



Adult Echo

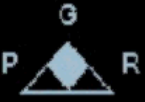TIS0.5 MI 0.7

X7-2t
17Hz
8.1cm



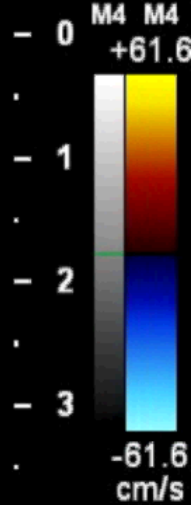
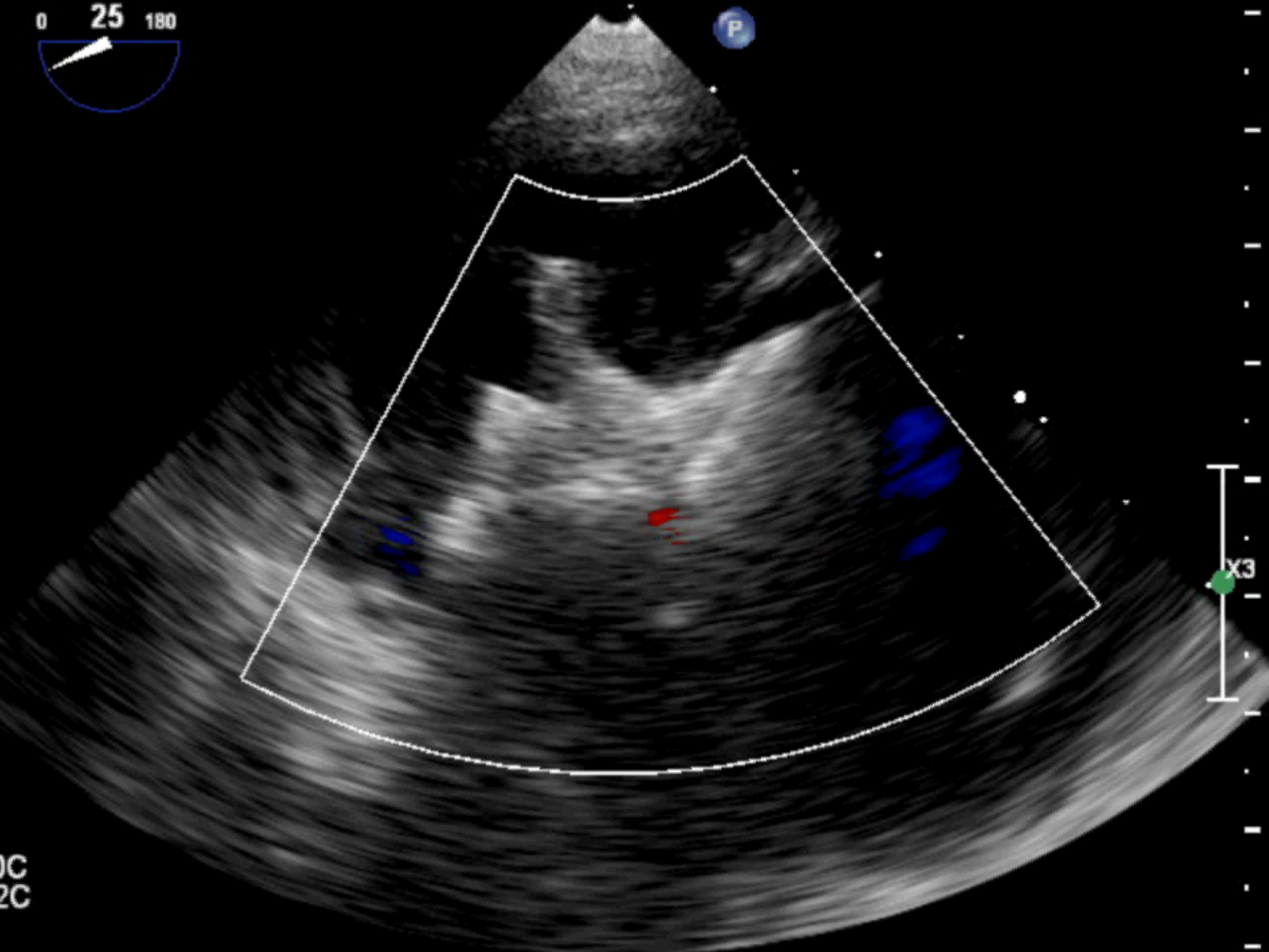
2D
58%
C 50
P Off
Gen

CF
48%
7104Hz
WF 639Hz
4.4MHz



PAT T: 37.0C
TEE T: 39.2C

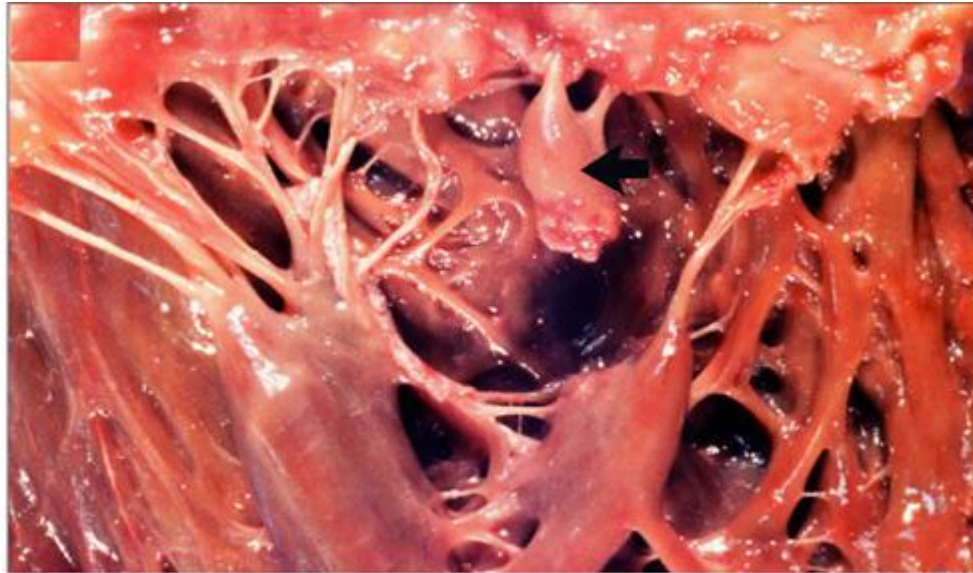
mcl
medisch centrum
leeuwarden



72 bpm



Papillairspierruptuur

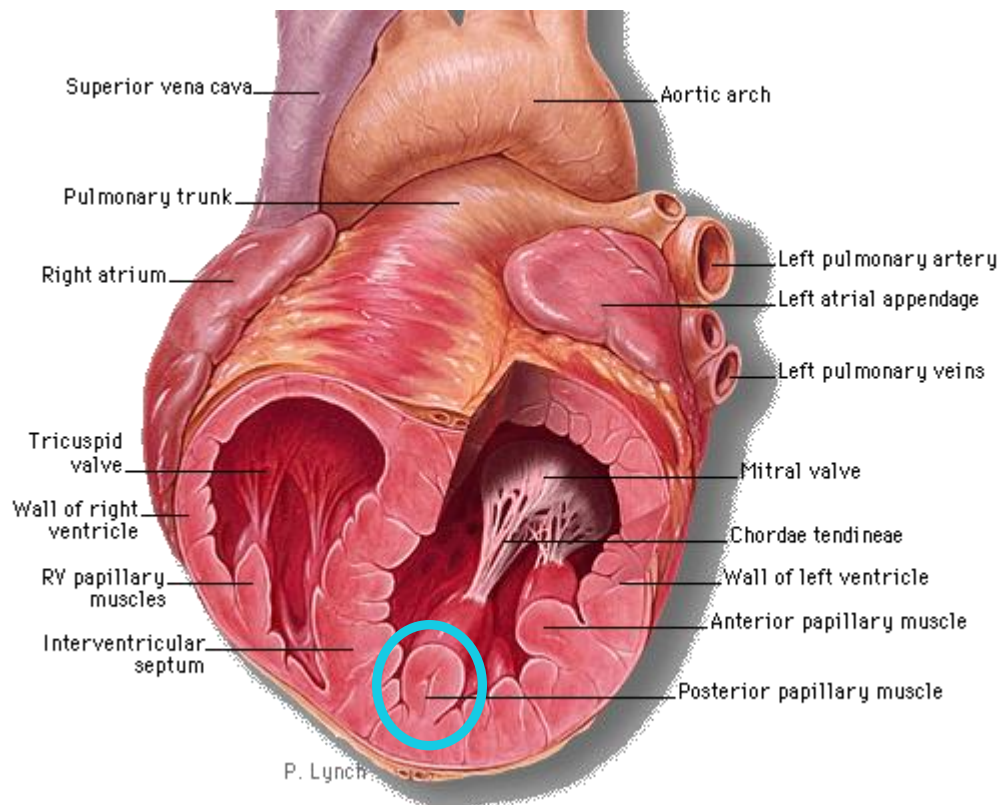


mcl

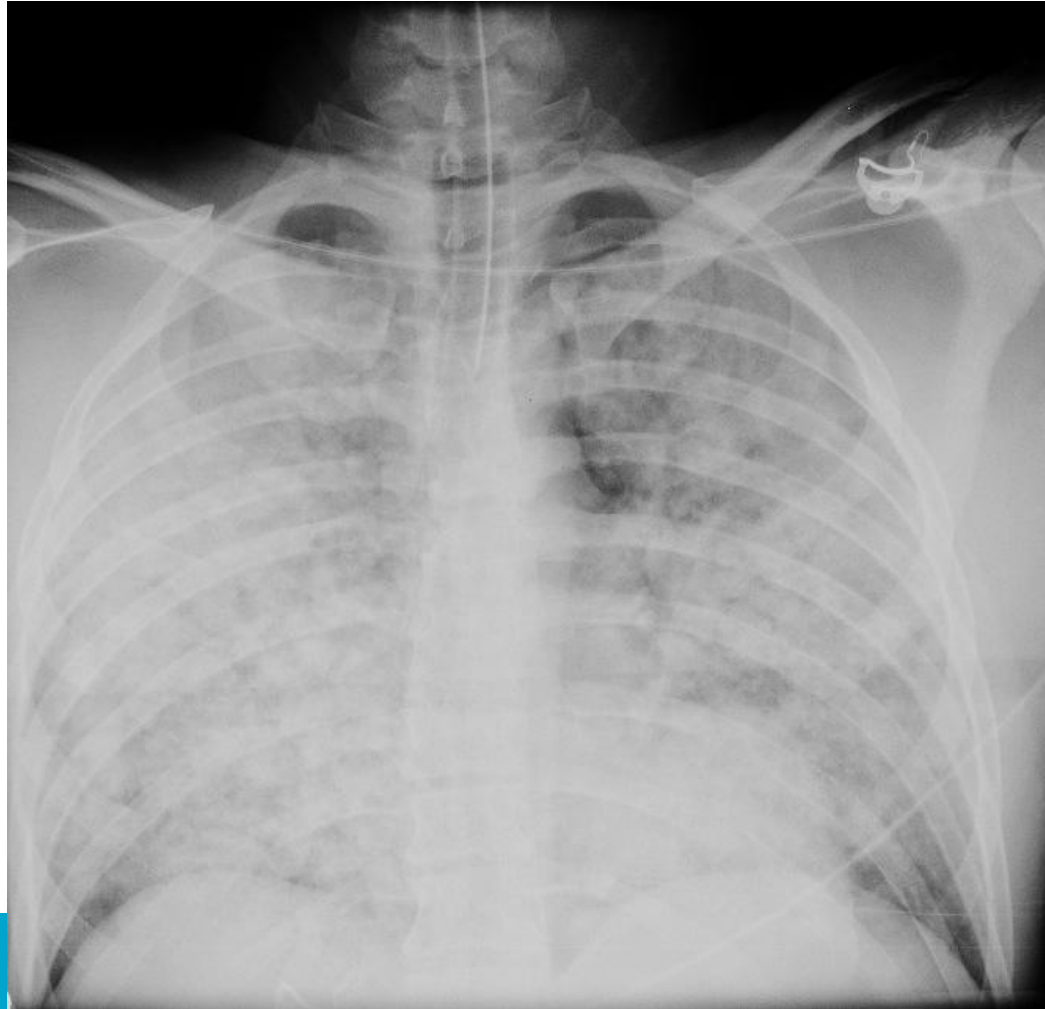
■ medisch centrum
leeuwarden



Lokalisatie



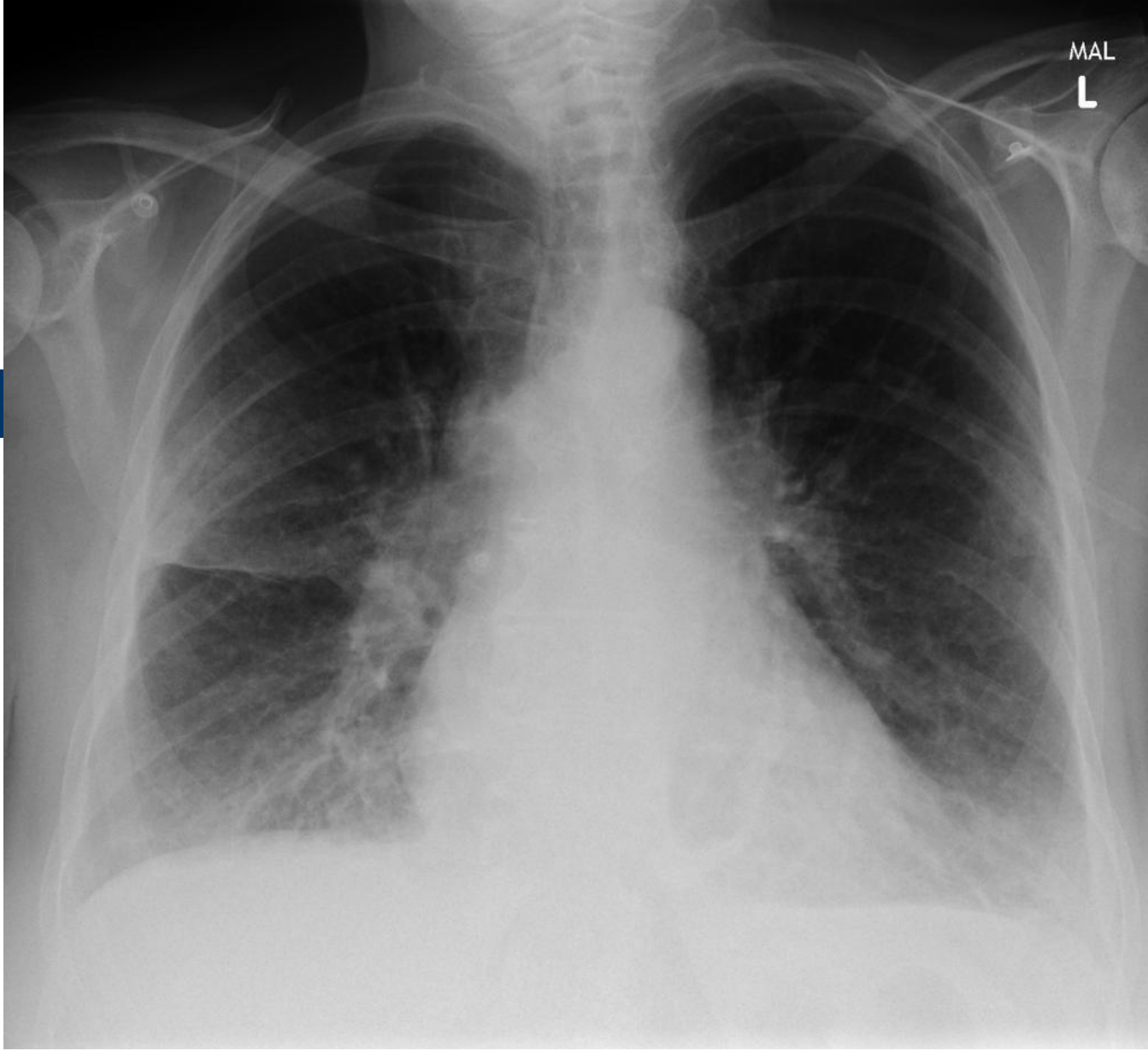
Klinische presentatie



mcl

■ medisch centrum
leeuwarden





mcl

■ medisch centrum
leeuwarden



Case courtesy of Dr Charlie Chia-Tsong Hsu, Radiopaedia.org, rID: 20939

Diagnostiek

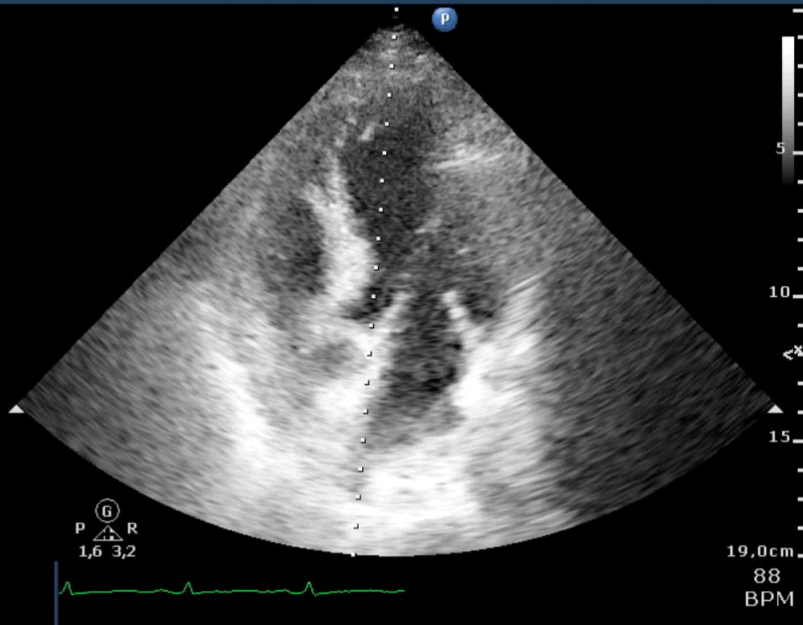


Diagnostiek

- Auscultatie
- Echo
- Hartcatheterisatie

MCL
S5-1
27 Hz
19,0cm

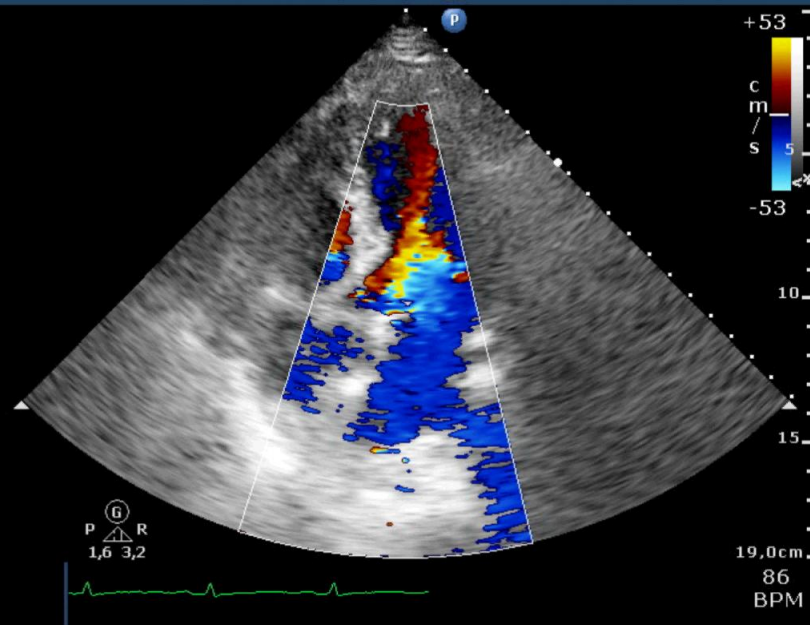
2D
HGen
Gn 57
C 52
3 / 2 / 1
50 mm/s



MCL
S5-1
17 Hz
19,0cm

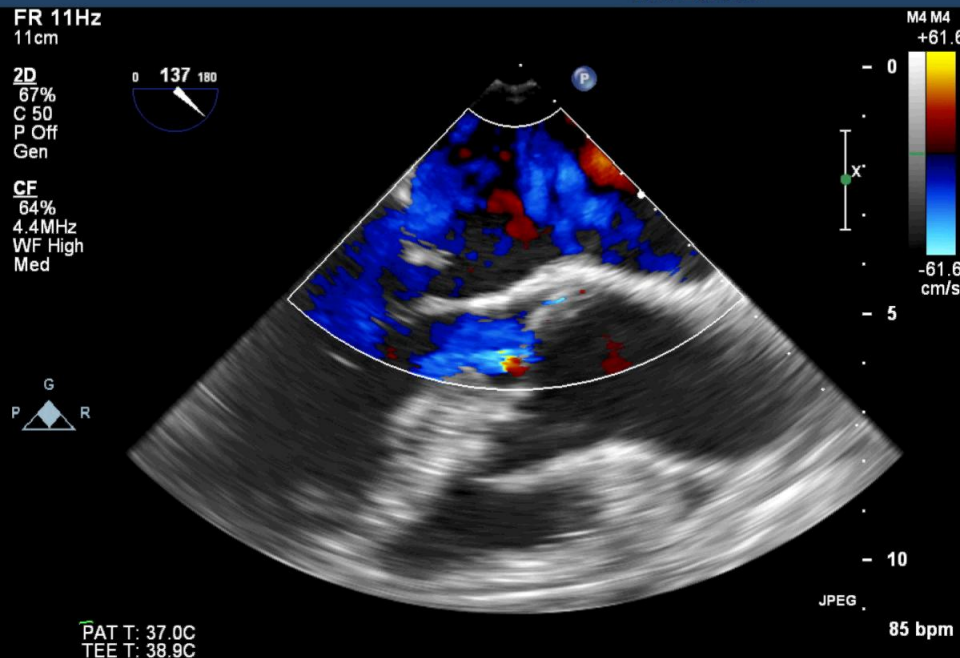
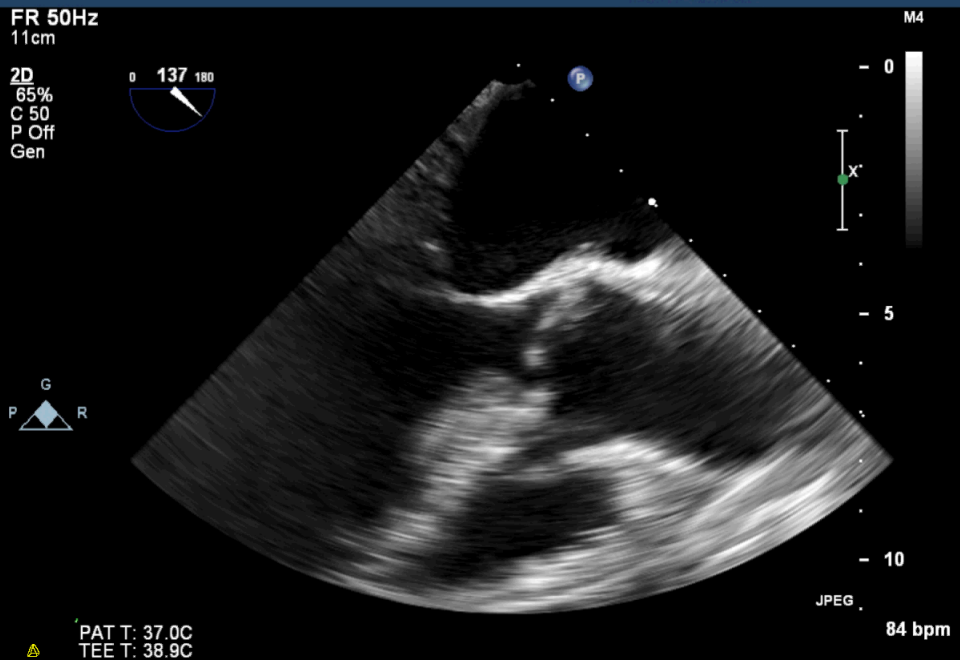
2D
HGen
Gn 57
C 52
3 / 2 / 0
50 mm/s

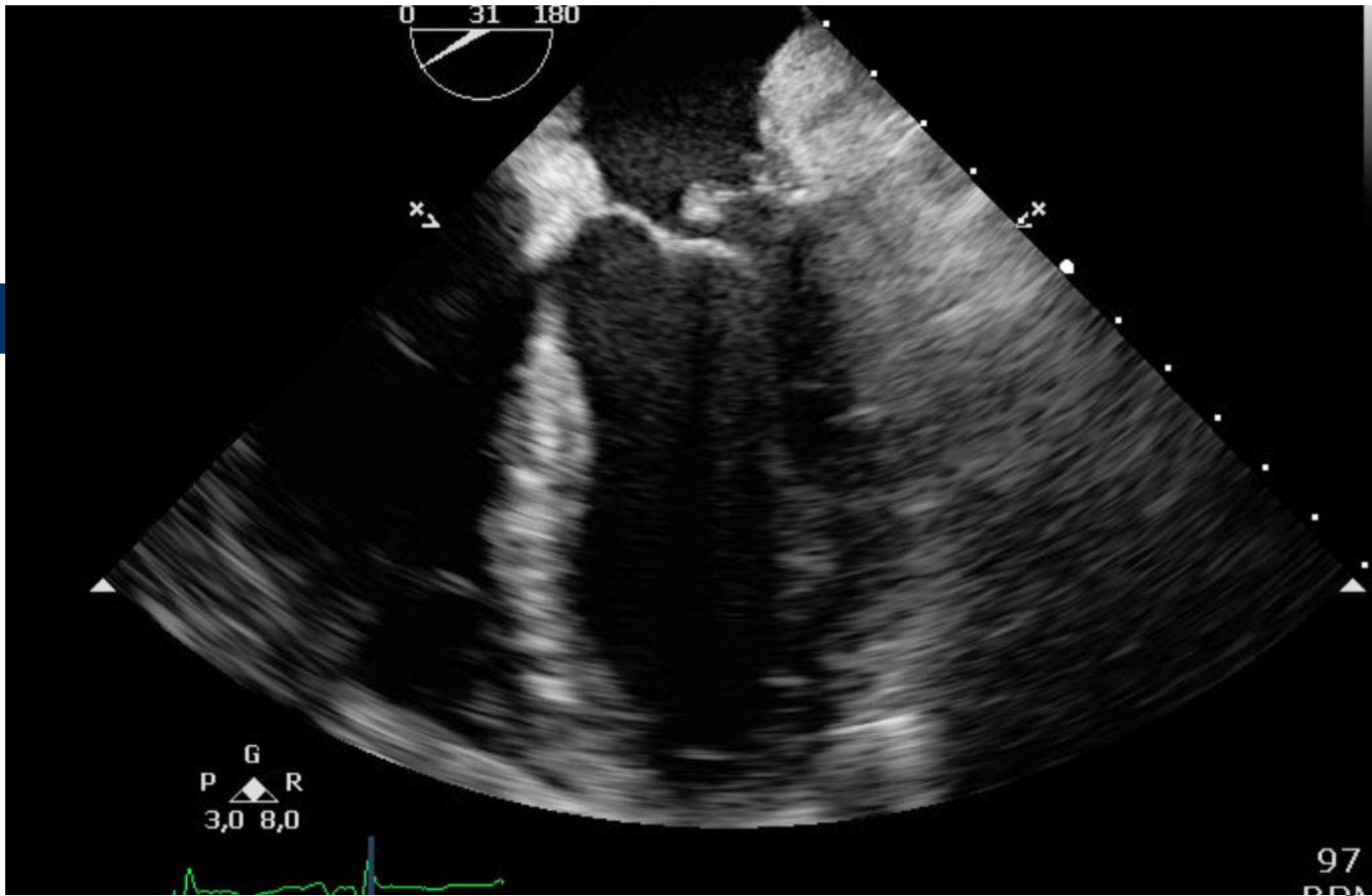
Color
2,5 MHz
Gn 67
4 / 4 / 0
Fltr High



mcl

medisch centrum
leeuwarden





mcl

■ medisch centrum
leeuwarden

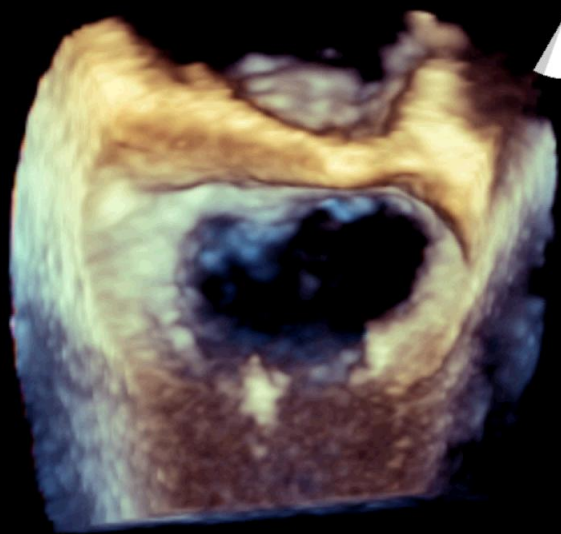
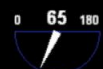
FR 8Hz
6.4cm

3D Beats 1

M4

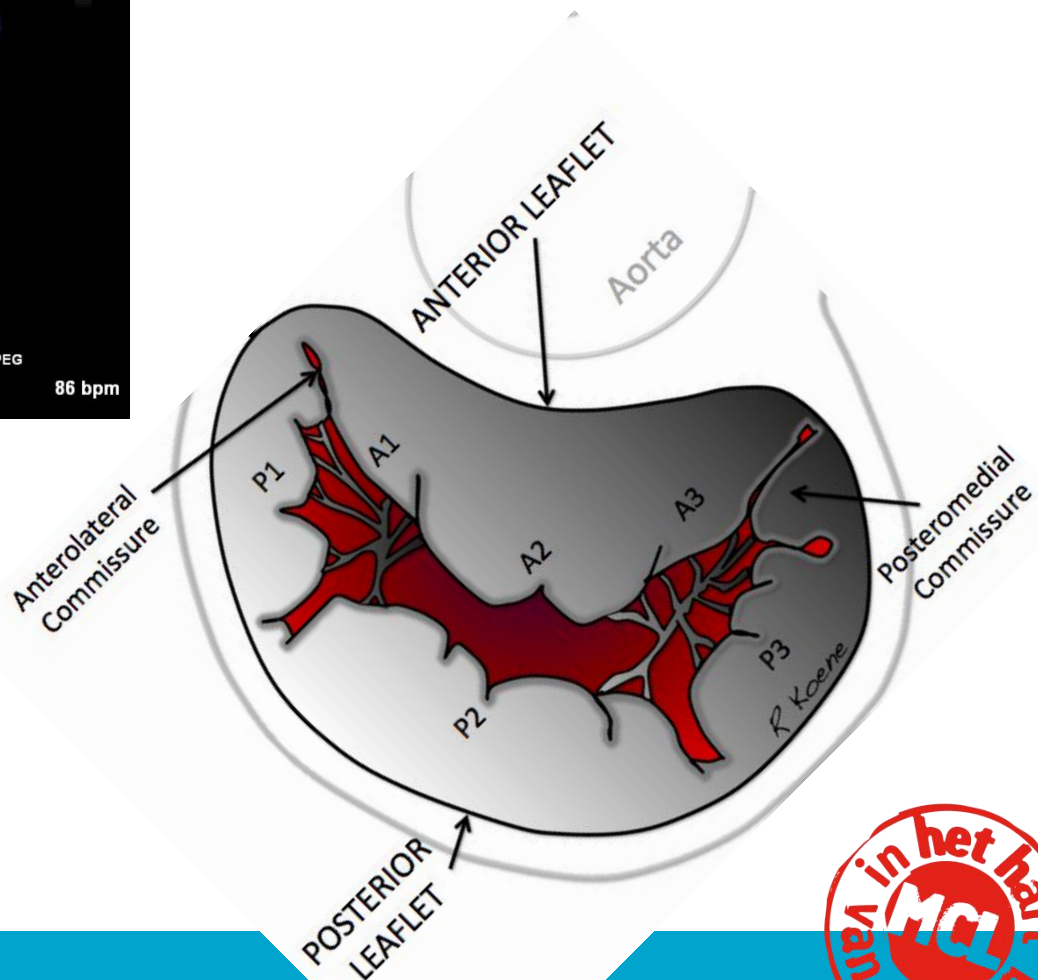
3D
3D 52%
3D 40dB



JPEG

86 bpm

PAT T: 37.0C
TEE T: 38.9C



mcl

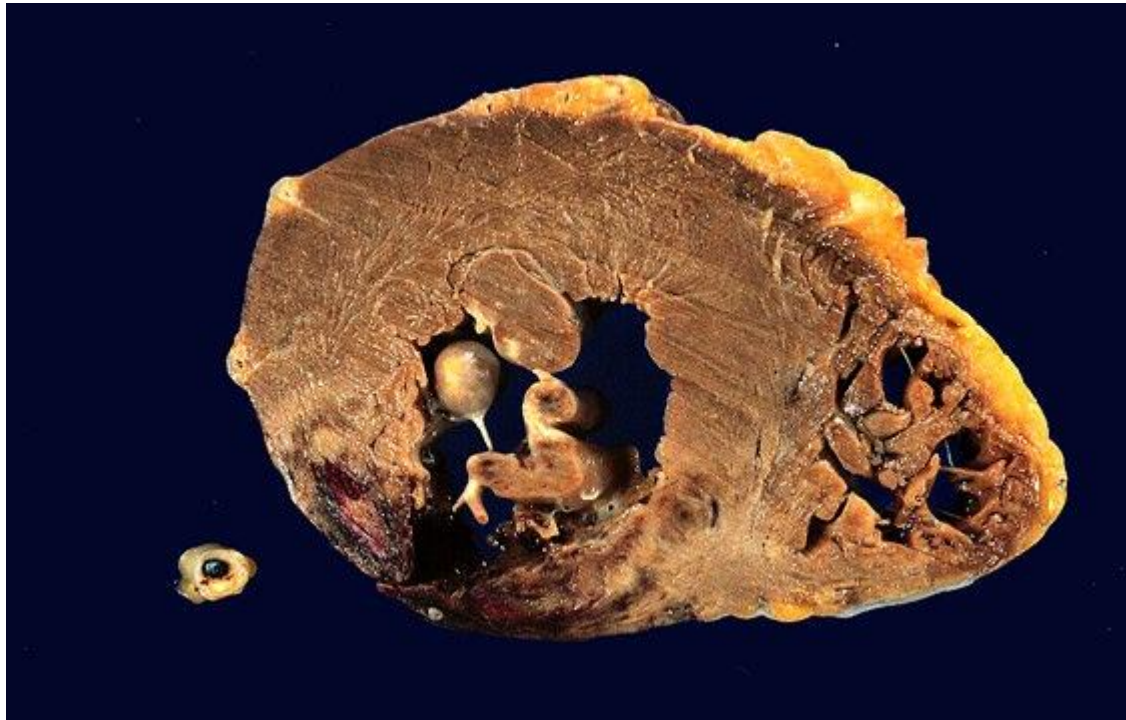
medisch centrum
leeuwarden



Therapie

- Afterload↓
- (PEEP)
- Chirurgie!

Vrije wand ruptuur



mcl

■ medisch centrum
leeuwarden



Classificatie

Free Wall Rupture



Type 1



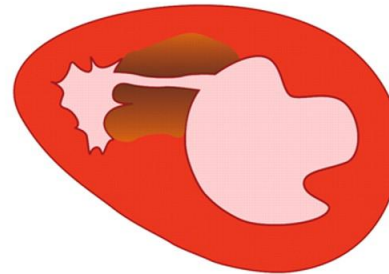
Type 2



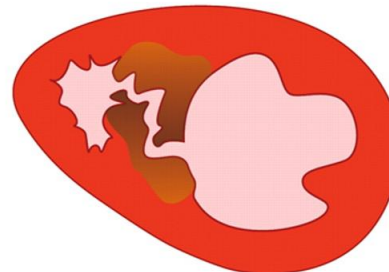
Type 3

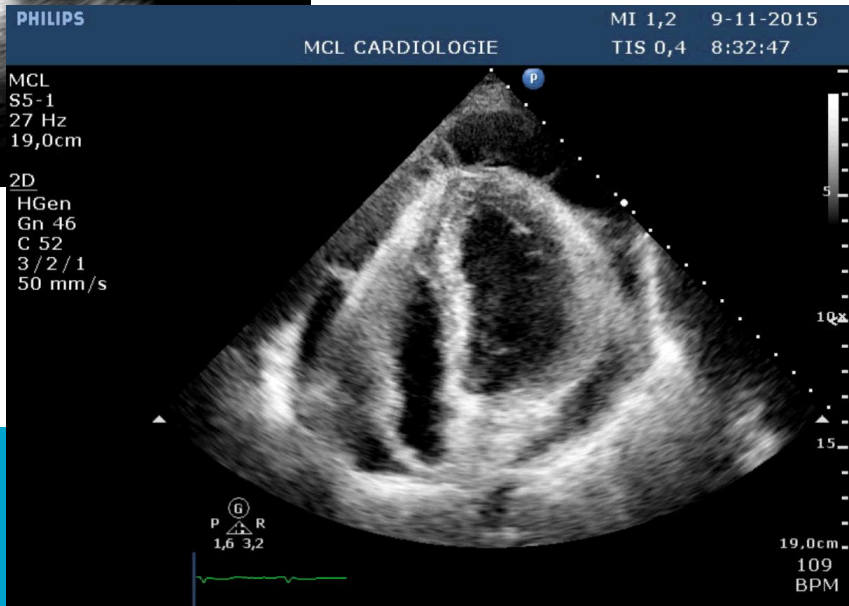
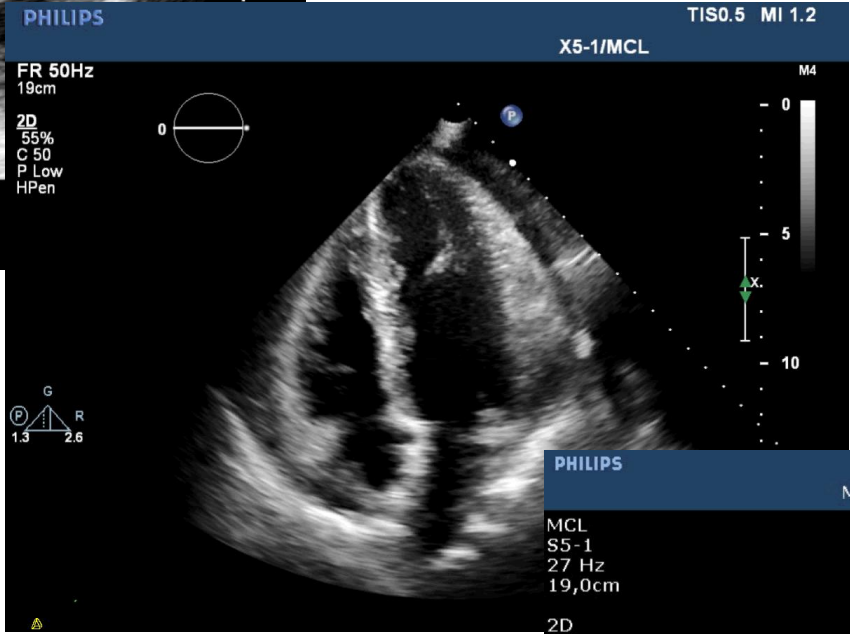
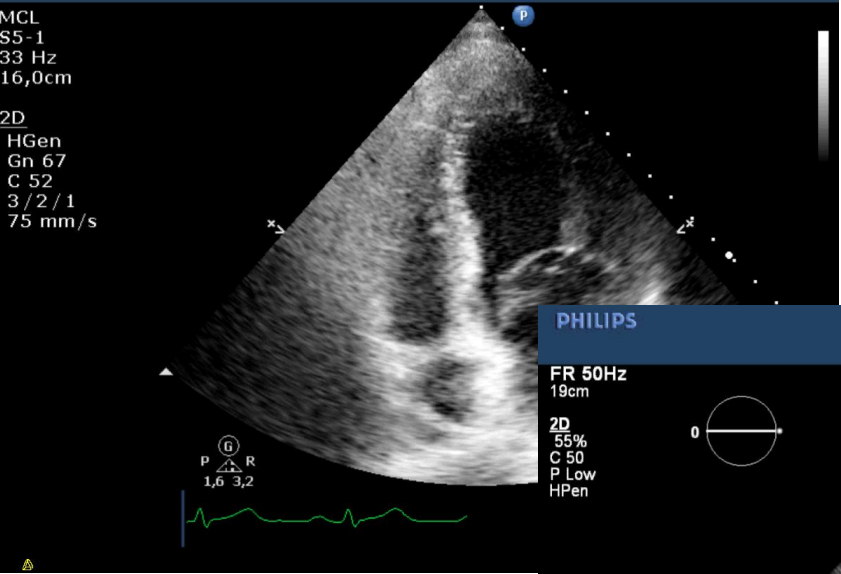
Ventricular Septal Rupture

Simple



Complex



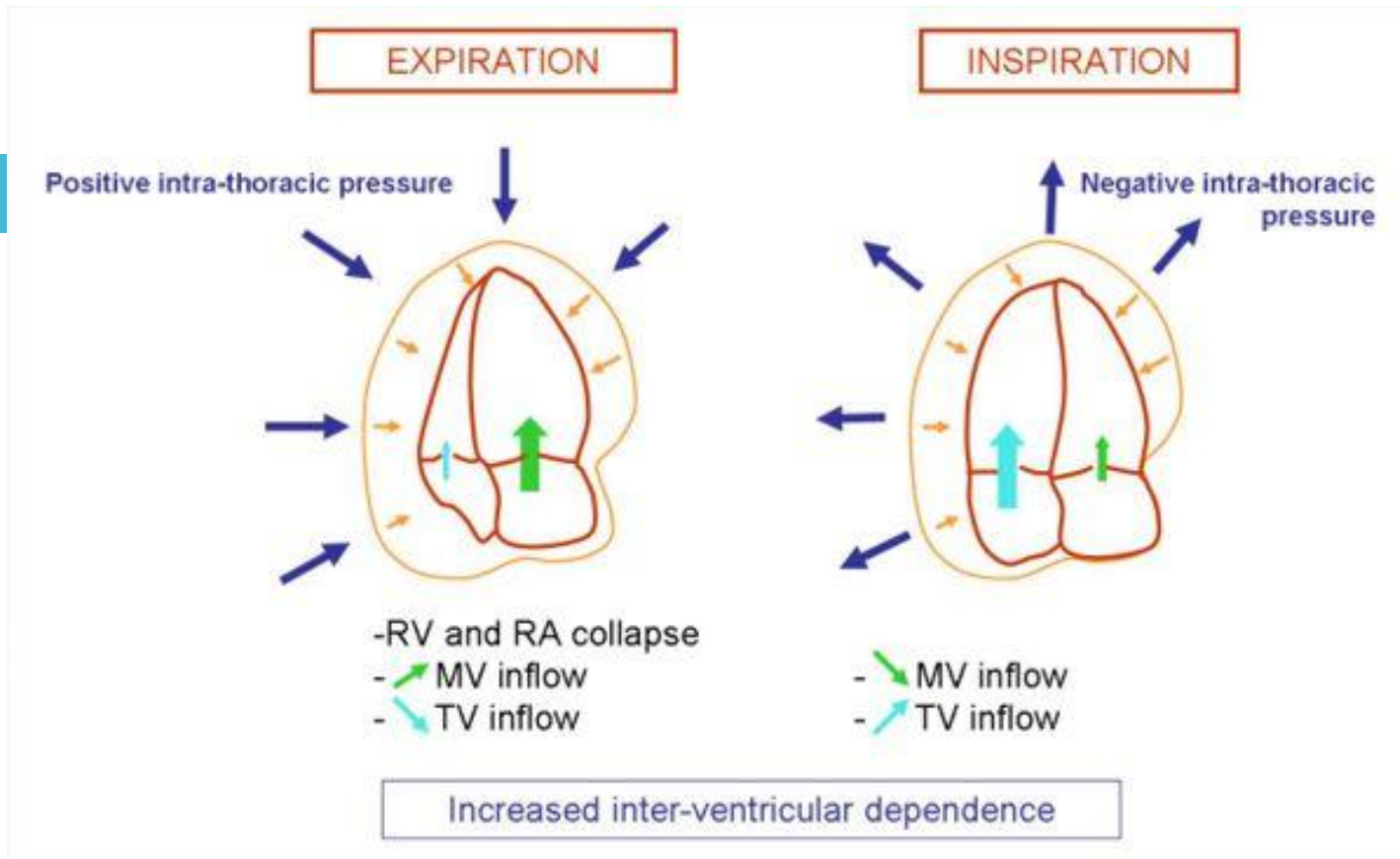


Casus

- Man, 45 jaar
- Blanco VG
- RF: roken
- Sinds enkele weken kortademig, griepigerig, pijn tussen de schouderbladen

Lichamelijk onderzoek

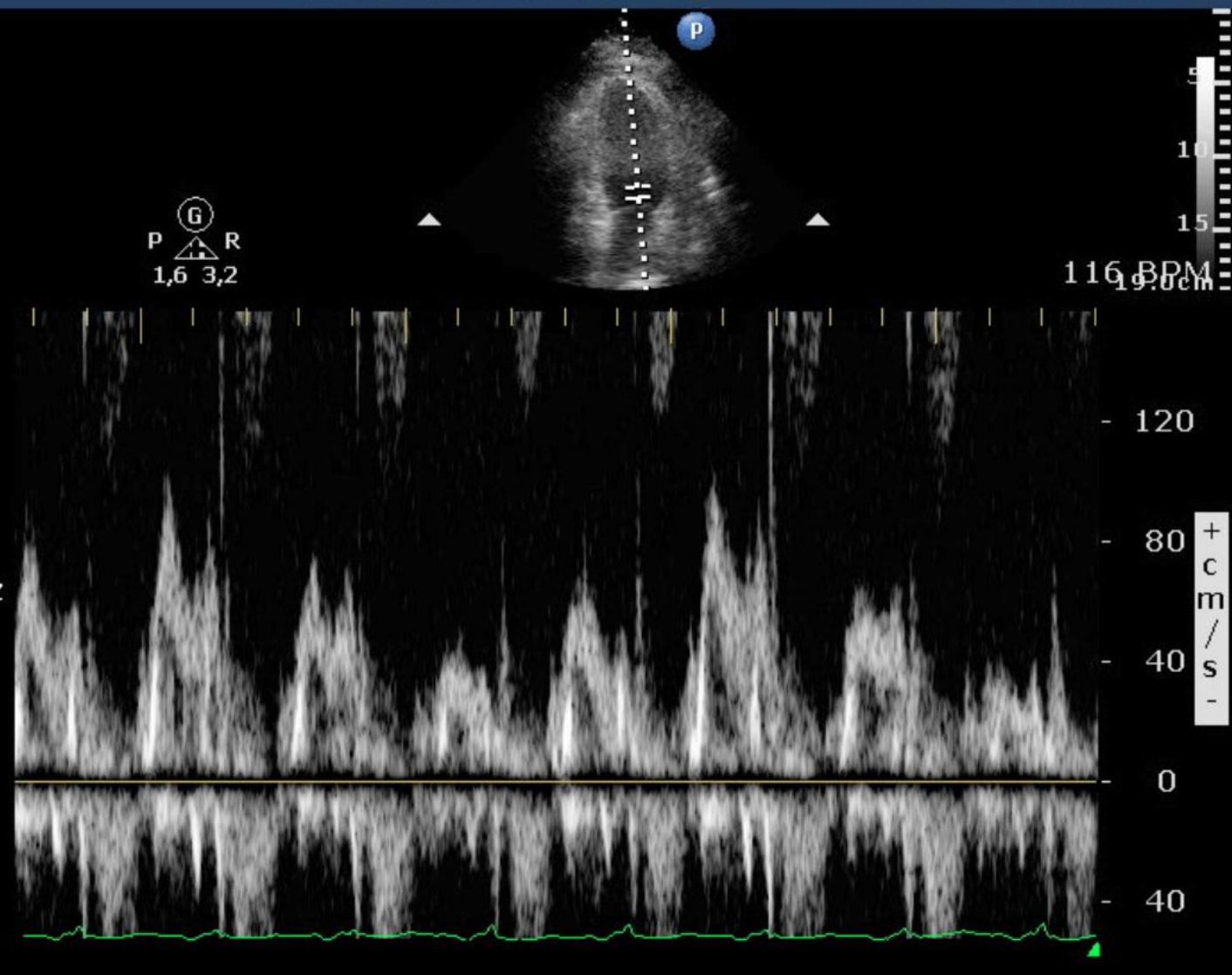
- Ziek, kortademig
- 120/80 mmHg, 120/min
- Pulsus paradoxus
- Ademhaling 40/min
- T 38°C

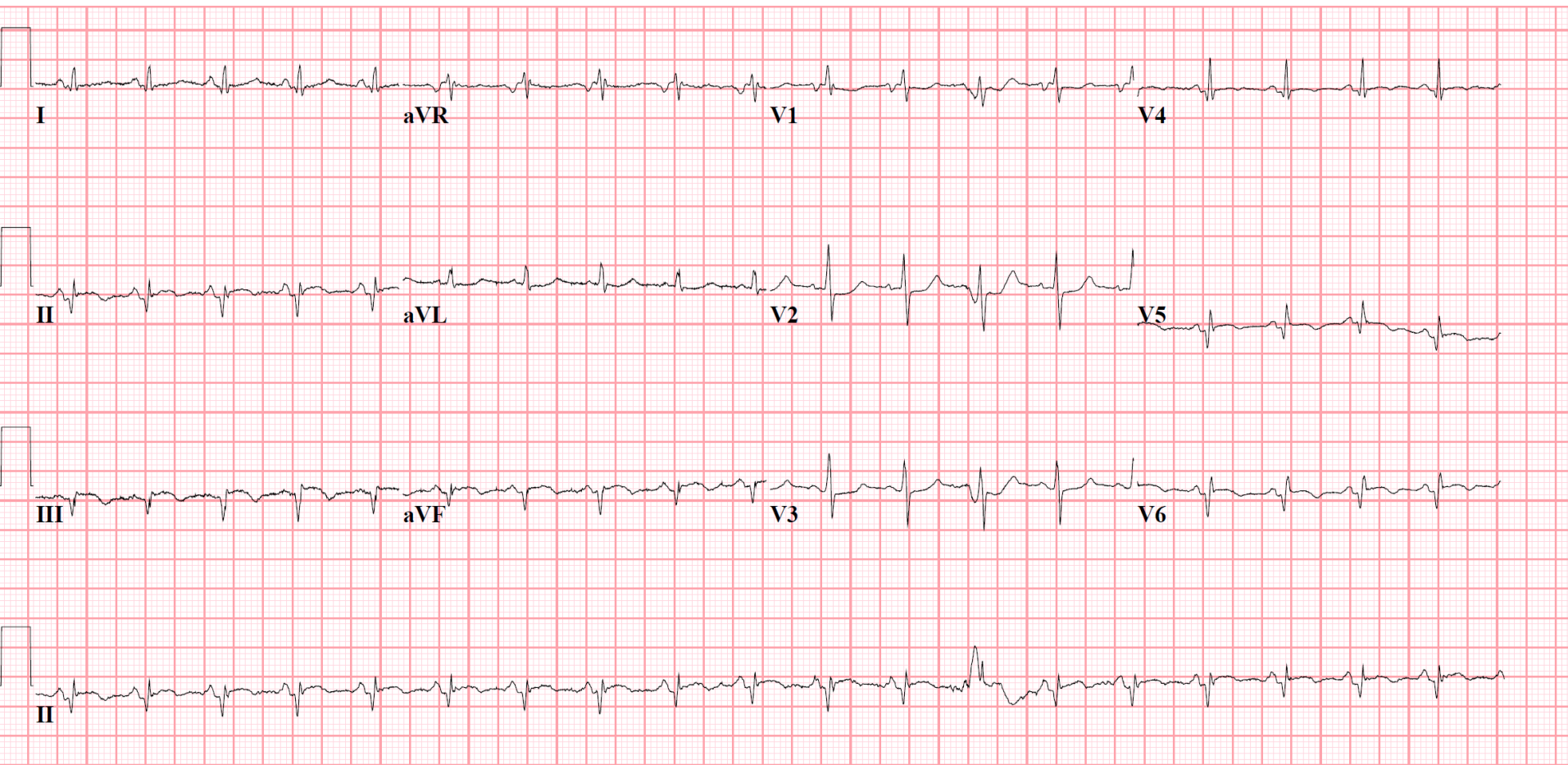


MCL
S5-1
19,0cm

2D
HGen
Gn 42
C 52
3/2/1

PW
1,8 MHz
Gn 50
12,4 cm
Angle 0°
Fltr 300Hz
50 mm/s





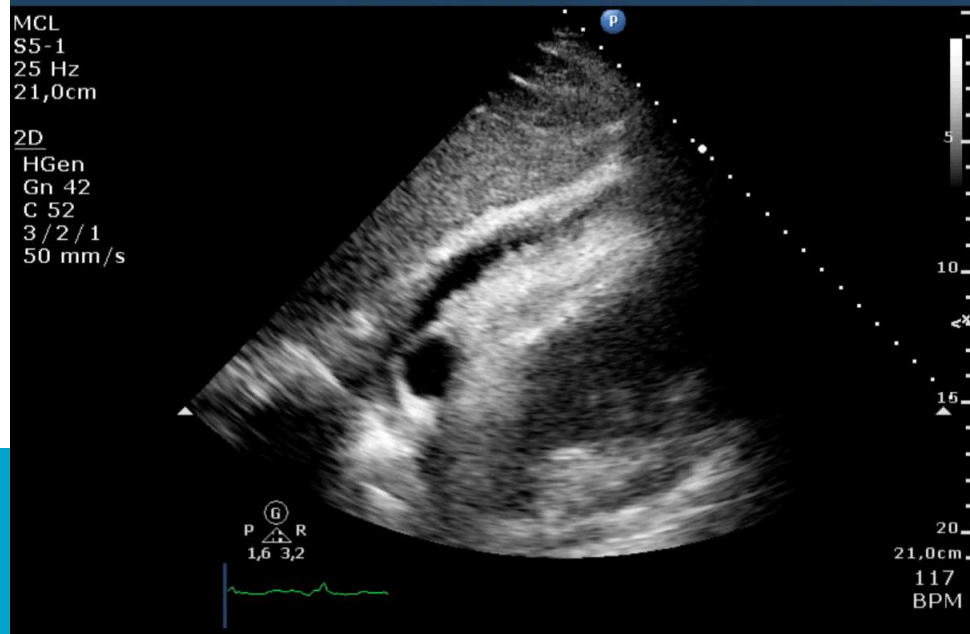
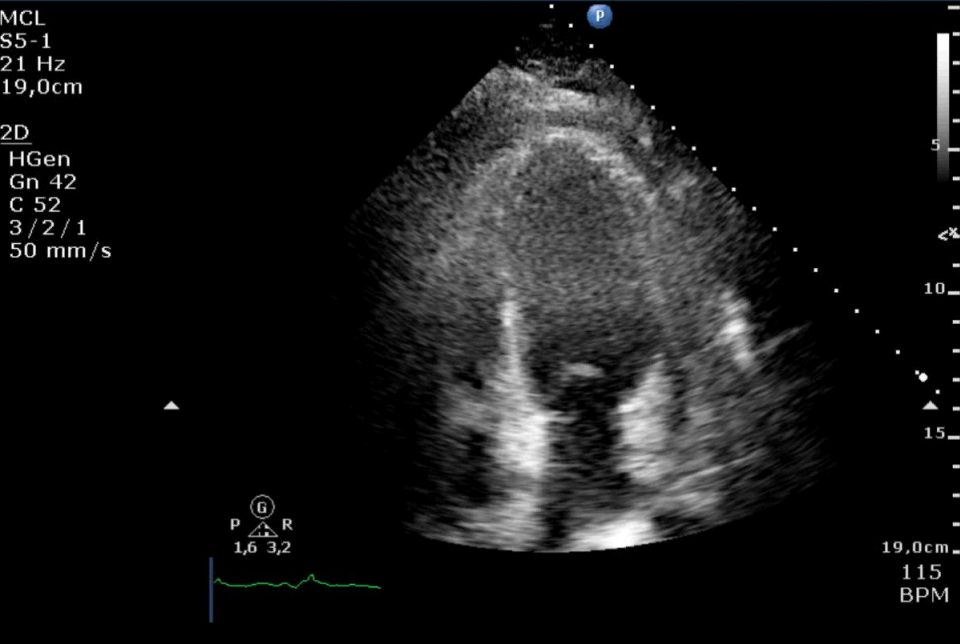
mcl

■ medisch centrum
leeuwarden



LAB

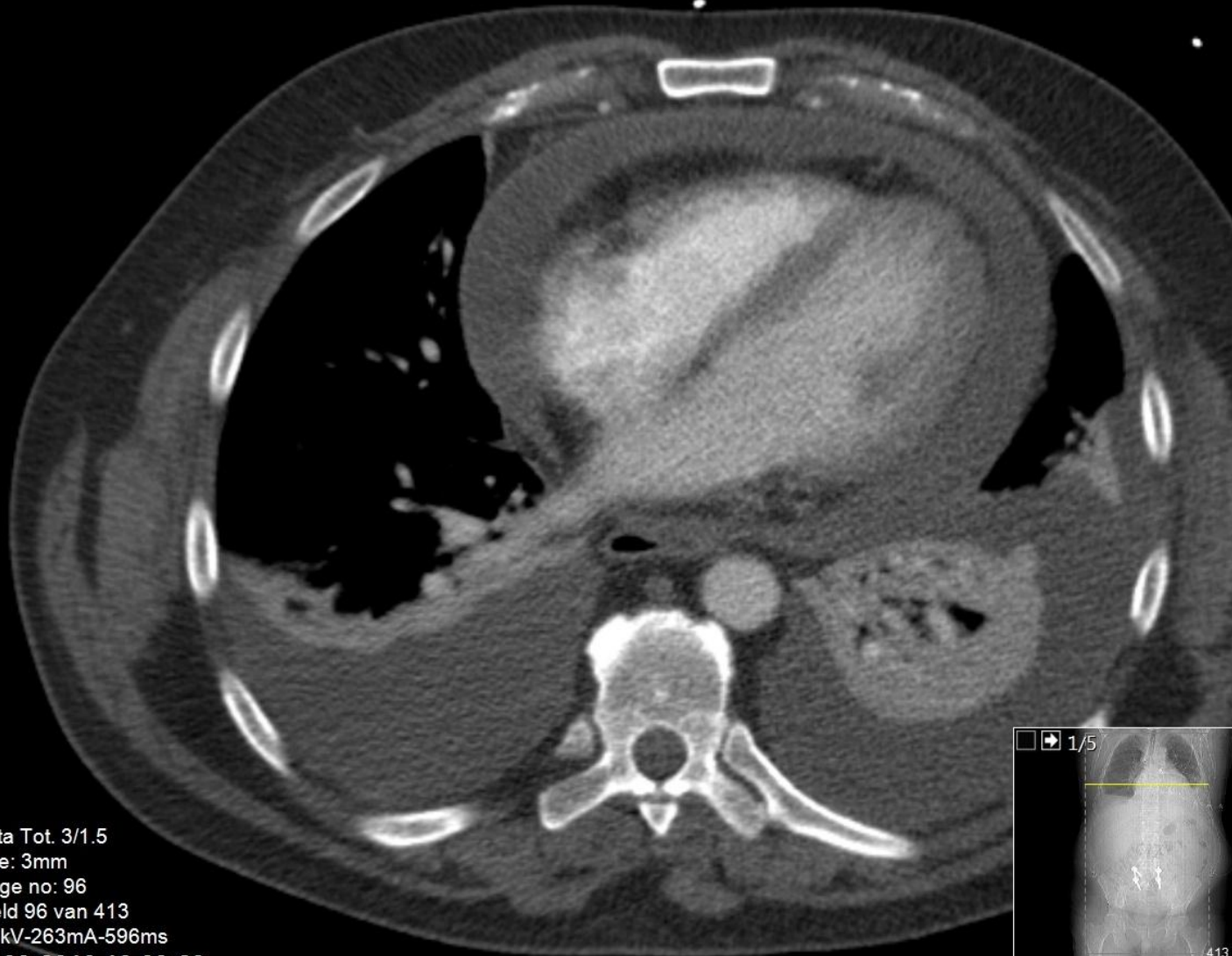
- Trop T 145
- CK/CK-MB < norm



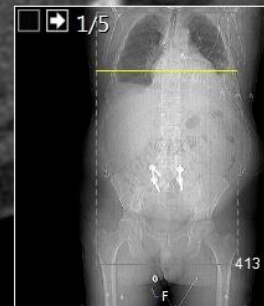
Acc.nr:200122510601
Couch: -591,3
Pos: FFS
FoV: 350 mm

C: 150,0, W: 700,0

Status: R



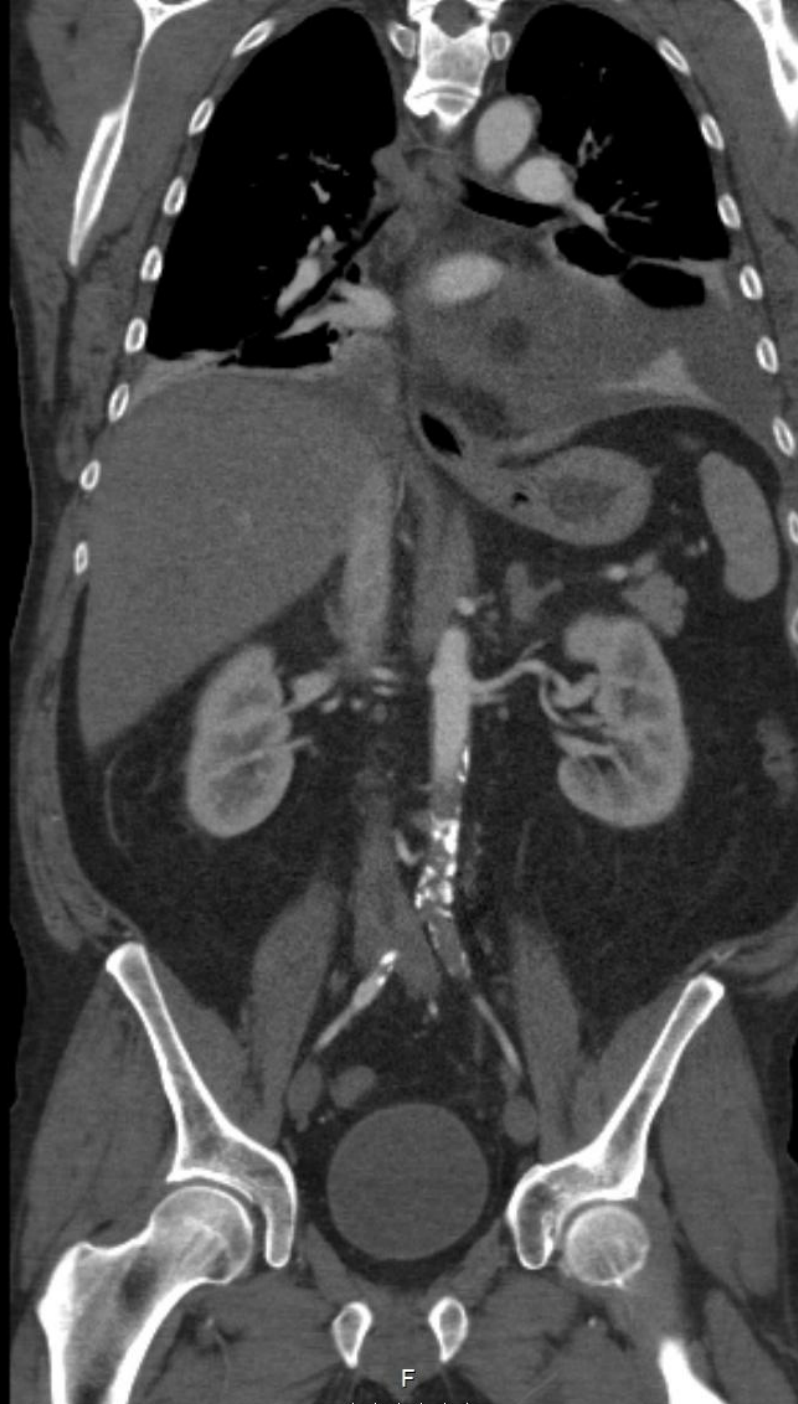Aorta Tot. 3/1.5
Slice: 3mm
Image no: 96
Beeld 96 van 413
120kV-263mA-596ms
10-03-2016 16:09:29



m

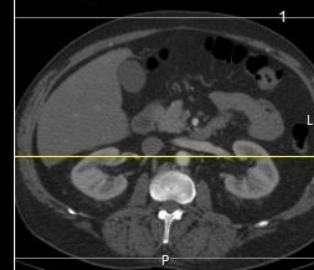
Acc.nr:200122510601
Couch: 159
Pos: FFS
FoV: 350 mm

C: 150,0, W: 700,0
Status: R
Z R L



COR 3/1,5 100/4 BPU12
Slice: 3mm
Image no: 107
Beeld 107 van 185
120kV-415mA-596ms
10-03-2016 16:09:29

1/5



9



m

Diagnose?

- Tamponade obv
 - Gedekte perforatie?
 - Pericarditis?

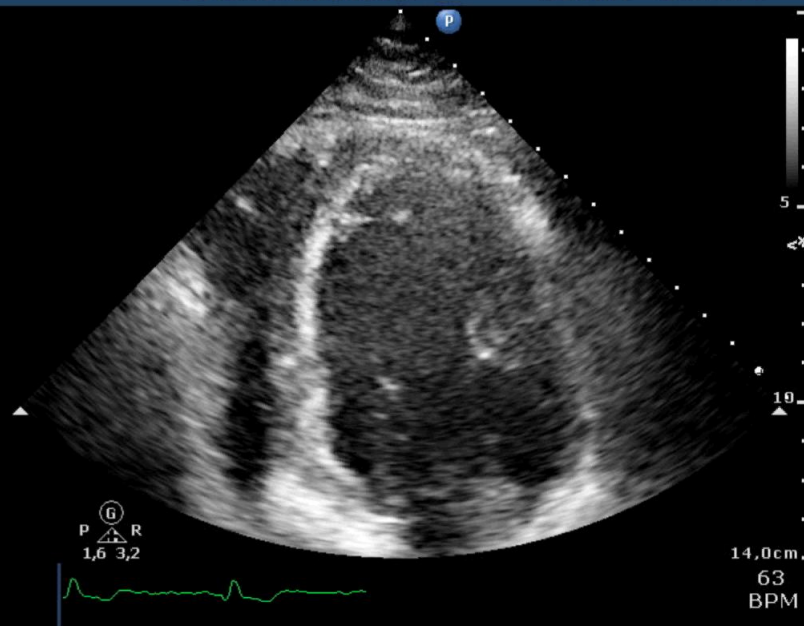
Beleid?



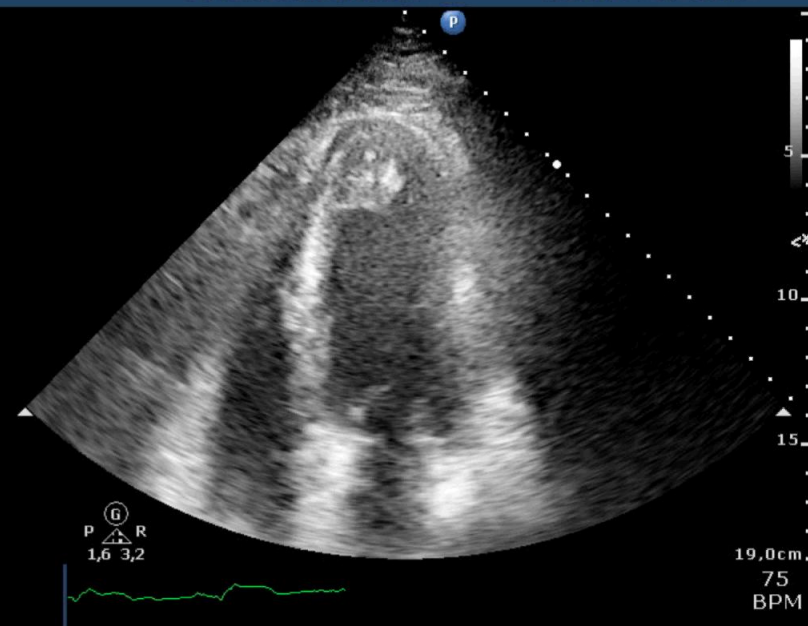
Beloop

- Chirurgie
- Sereus vocht
- Toch pericarditis?
- Echter klachten, ECG-afwijkingen en perifeer vaatlijden
- CAG volgt 12-05-2016

MCL
S5-1
35 Hz
14,0cm
2D
HGen
Gn 59
C 52
3 / 2 / 1
50 mm/s



MCL
S5-1
27 Hz
19,0cm
2D
HGen
Gn 73
C 52
3 / 2 / 1
50 mm/s



mcl

medisch centrum
leeuwarden

PHILIPS

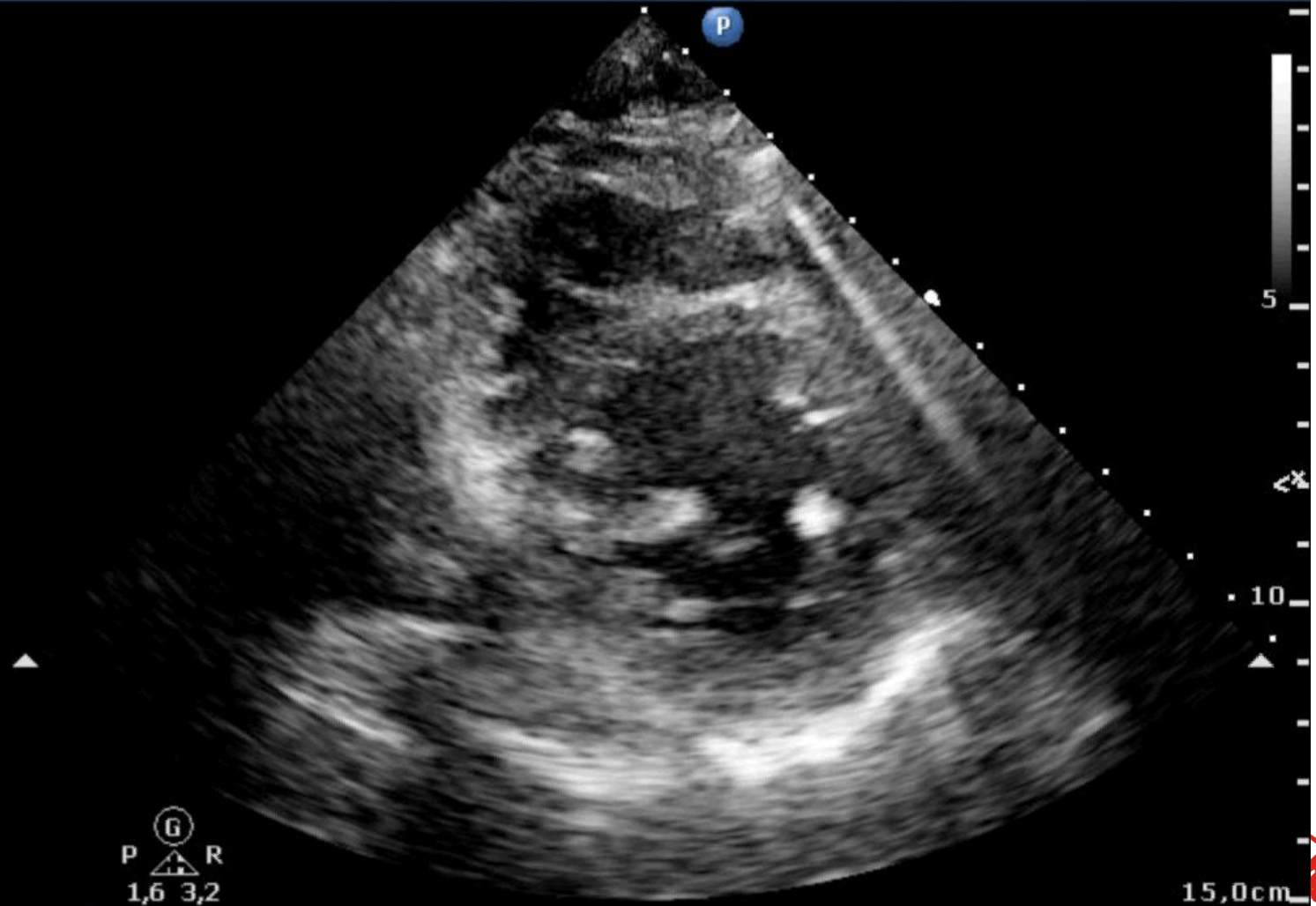
MI 1,3 27-1-2016

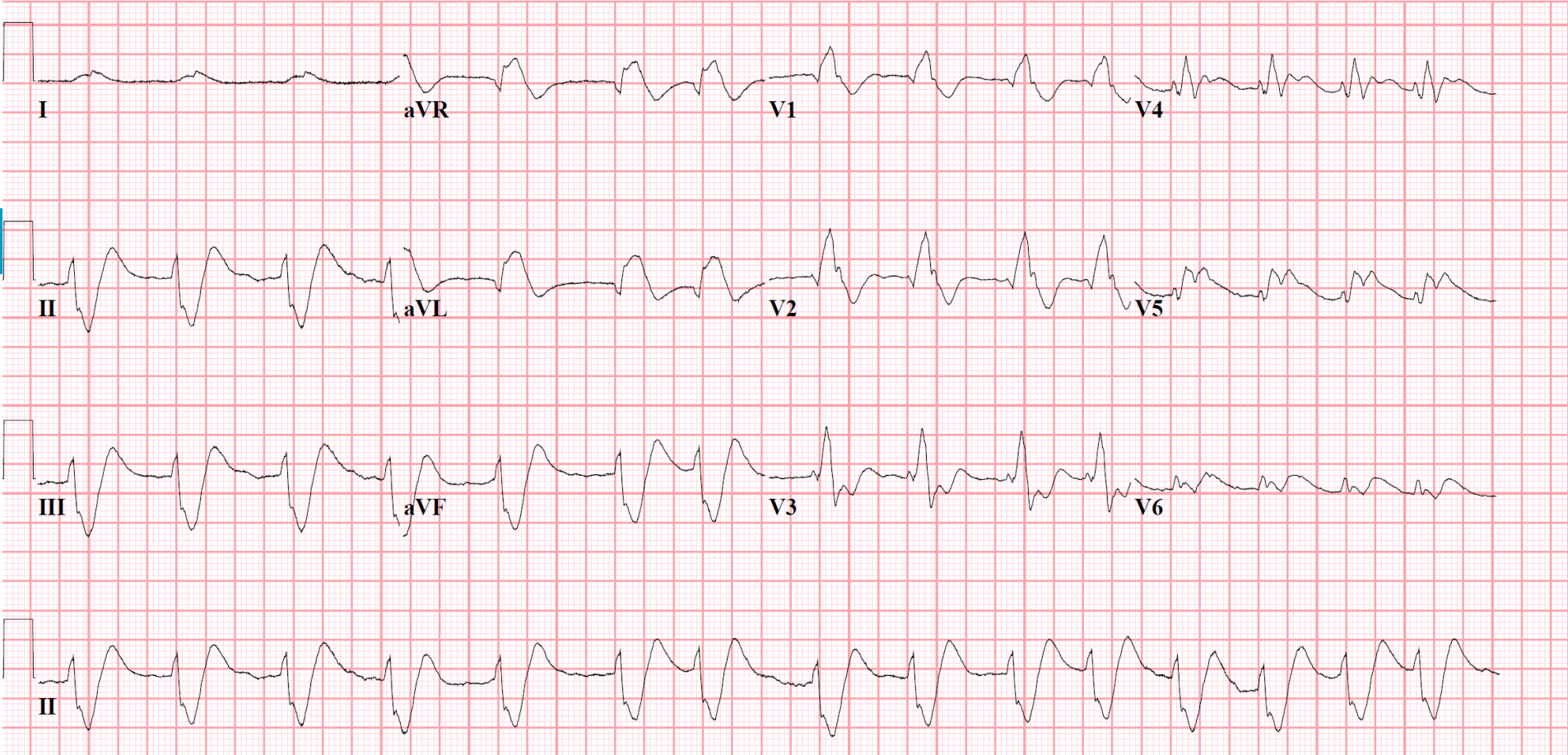
MCL CARDIOLOGIE

TIS 0,5 15:46:29

MCL
S5-1
33 Hz
15,0cm

2D
HGen
Gn 44
C 52
3 / 2 / 1
50 mm/s

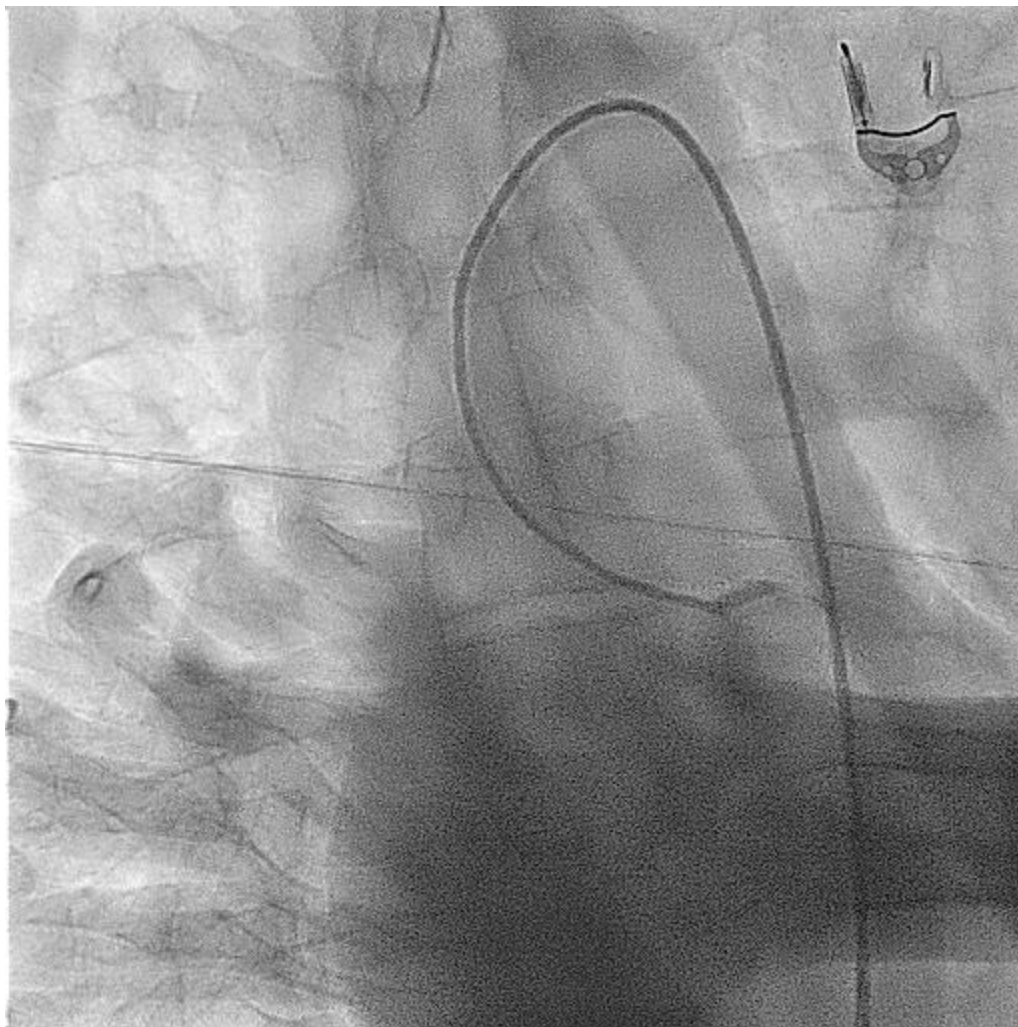




mcl

■ medisch centrum
leeuwarden





mcl

■ medisch centrum
leeuwarden



Niet besproken

- Cardiogene shock
- LV outflow tract obstructie
- RV infarct

Take home

- Echo-cor is zeer zinvol bij het diagnosticeren van complicaties van AMI
- Het levert de meeste resultaten op alleen in combinatie met overige klinische bevindingen



?

mcl

■ medisch centrum
leeuwarden

