

18 november 2022

# Linkerbundel area pacing

Alles wat u moet weten over pacing van het geleidingsstelsel

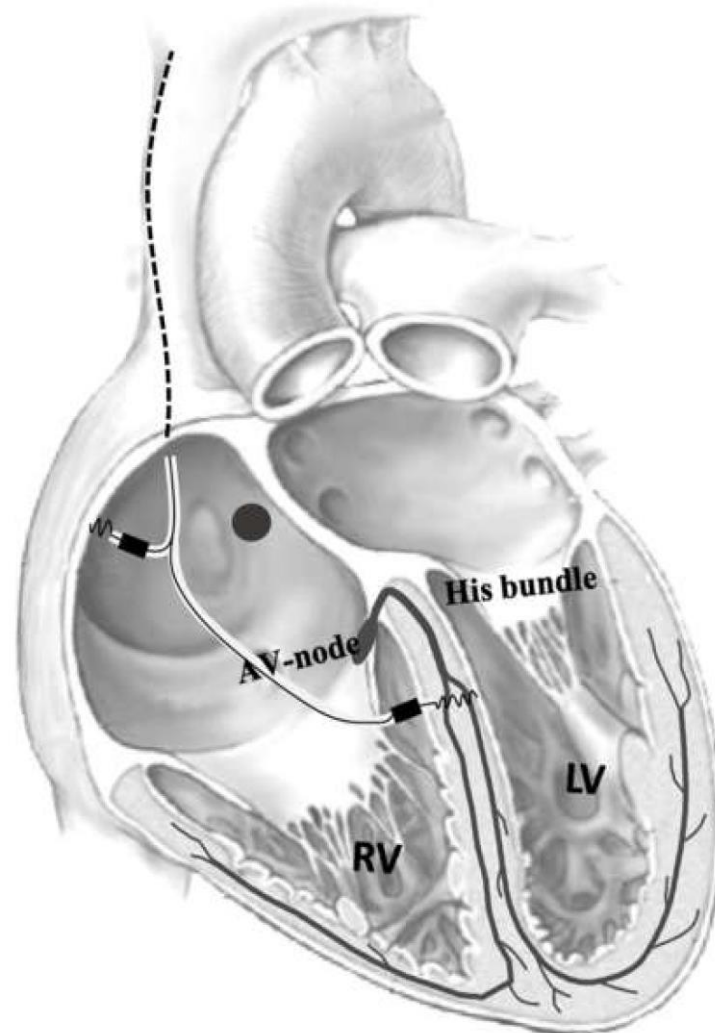
---

Marco van Gent - Cardioloog

**Albert  
Schweitzer**  
ziekenhuis

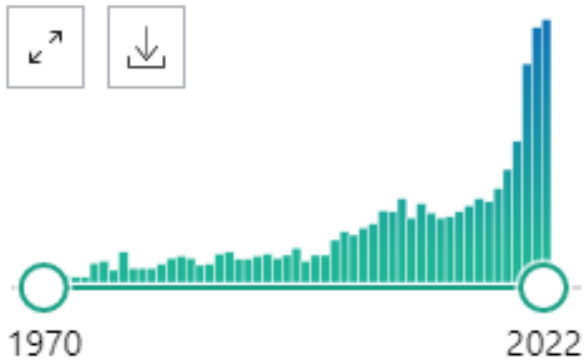


# LBA pacing



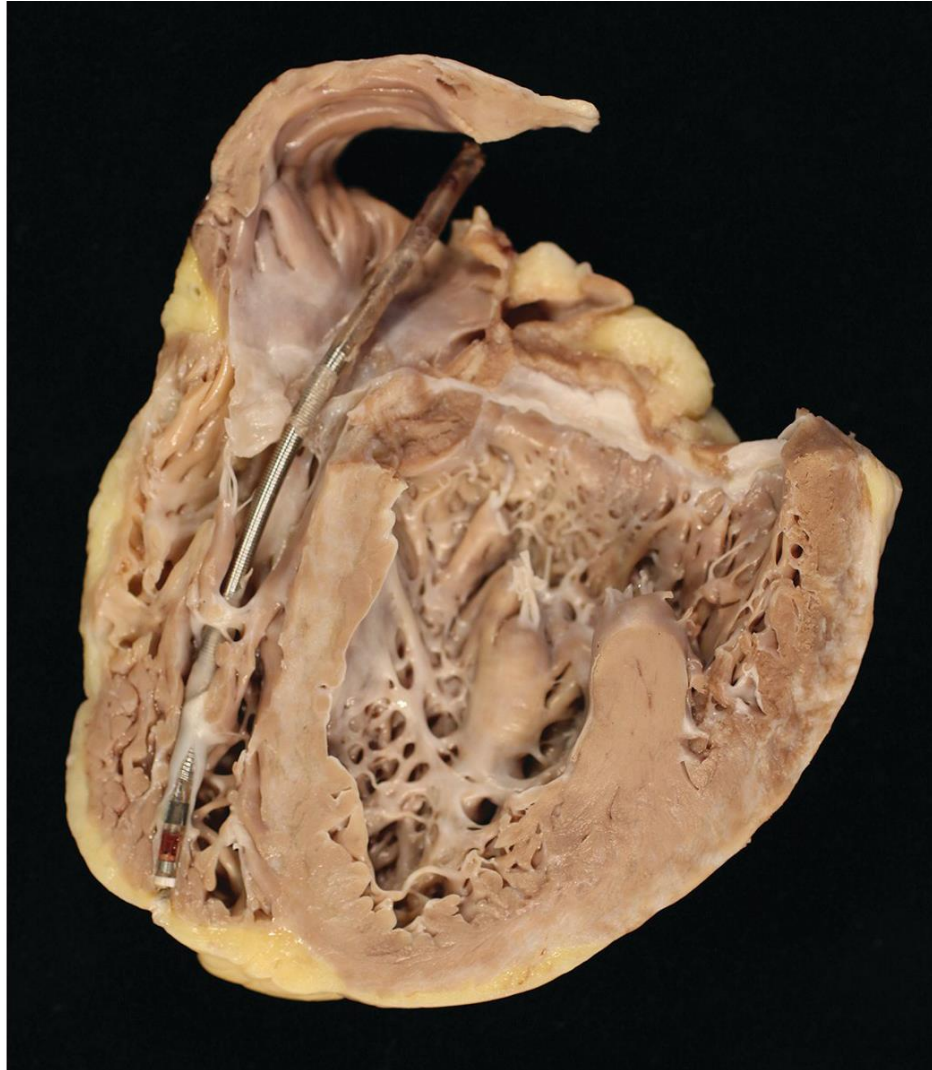# LBA pacing is hot!

RESULTS BY YEAR

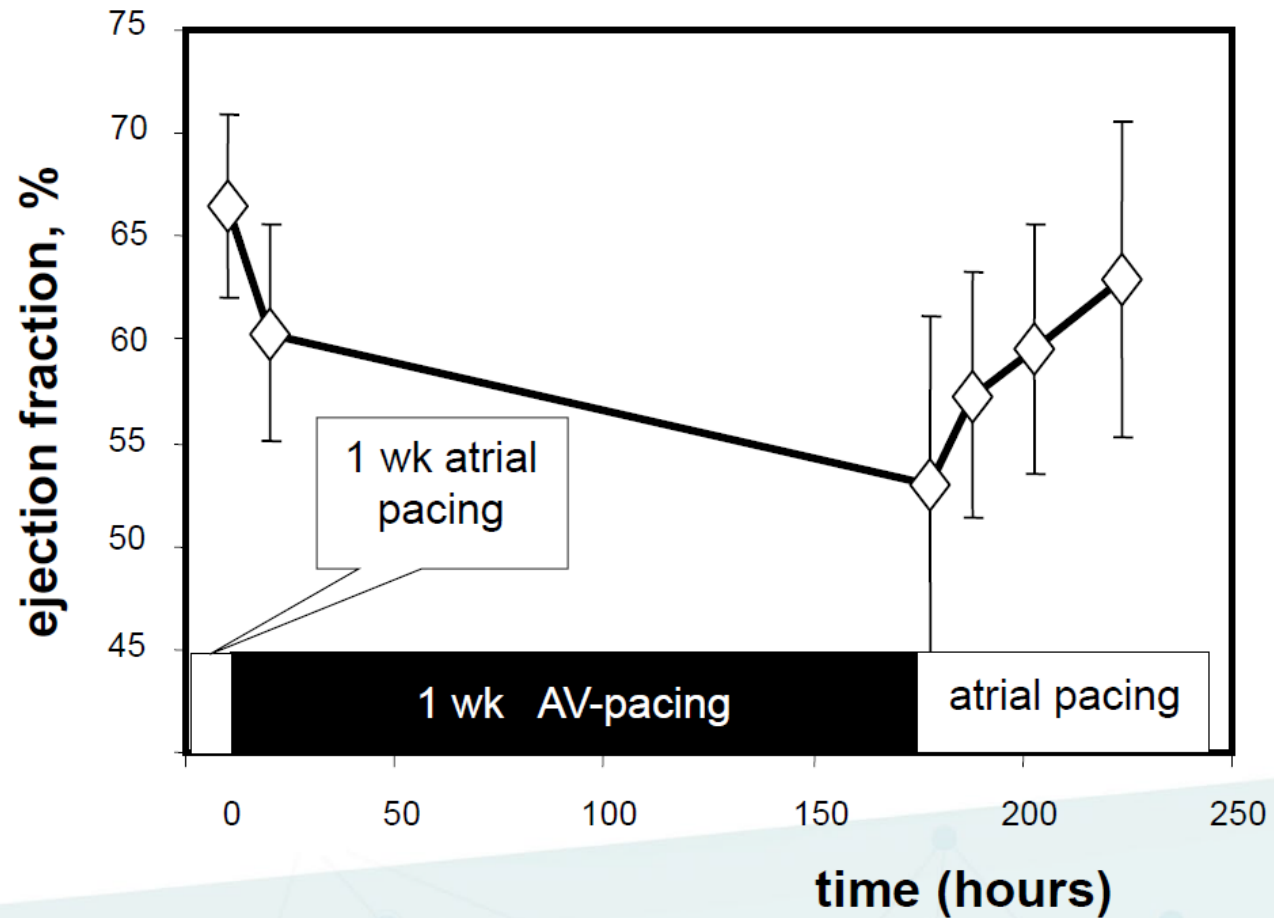


- **Wat is er mis met rechterkamer pacing?**
- **Anatomie van het geleidingssysteem**
- **Wat is fysiologische pacing of conduction system pacing en welke vormen zijn er?**
- **Linkerbundelarea pacing**
  - **Materialen**
  - **Procedure**
  - **Resultaten**
  - **Complicaties**
  - **Vervanging van CRT?**
  - **De toekomst**

# RV pacing



# RV pacing



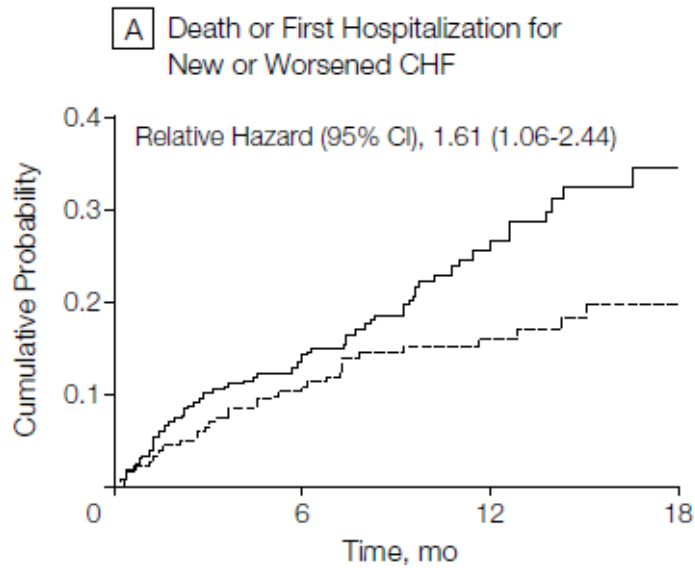
Modified after  
Nahlawi et al., 2007

# RV pacing

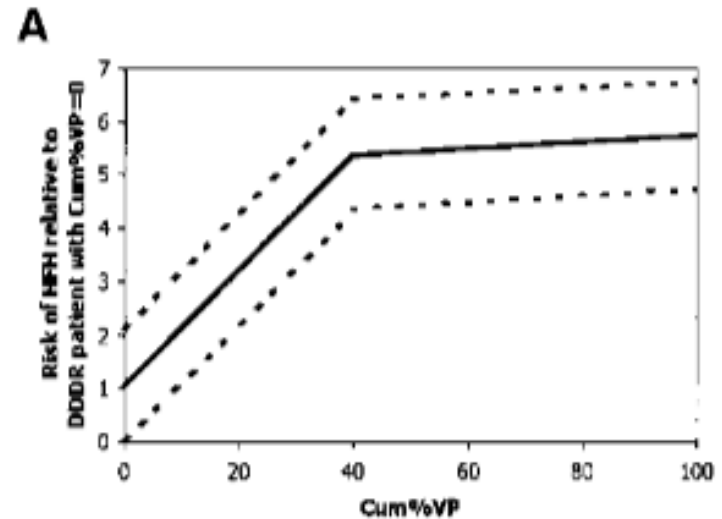
## DAVID

## MOST

— Dual-Chamber Rate-Responsive Pacing (DDDR)  
- - - Ventricular Backup Pacing (VVI)



JAMA 2002



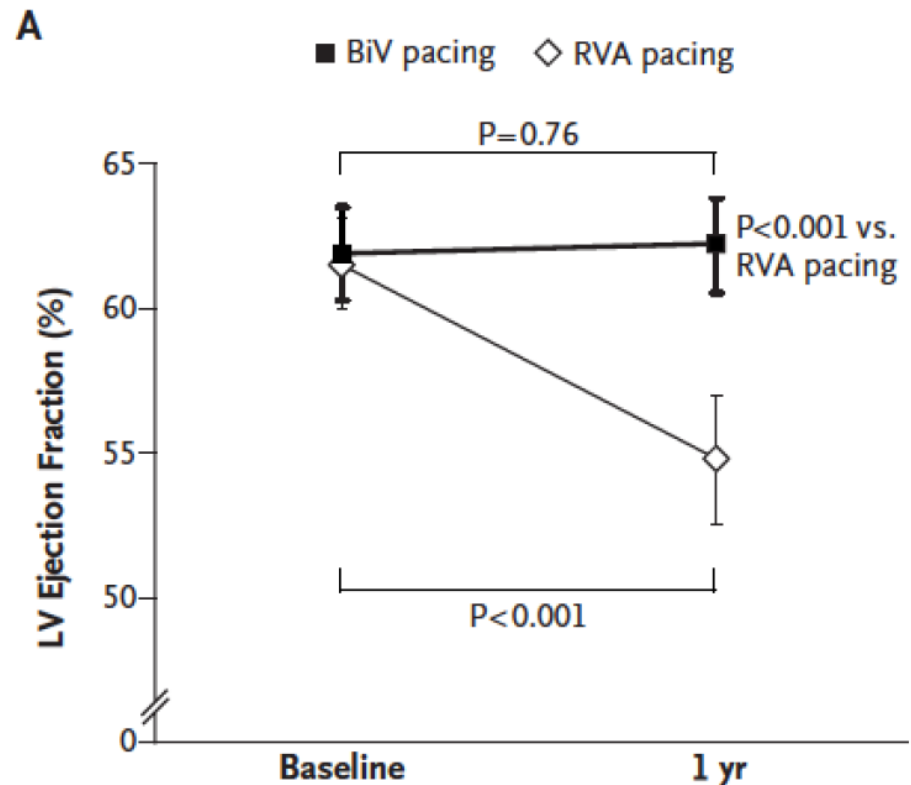
Sweeney. Circulation 2003

# RV pacing

Right ventricular pacing causes a 5-10% point reduction in EF, In ~40% > 10% points loss.

So a first (or second) “hit” towards heart failure

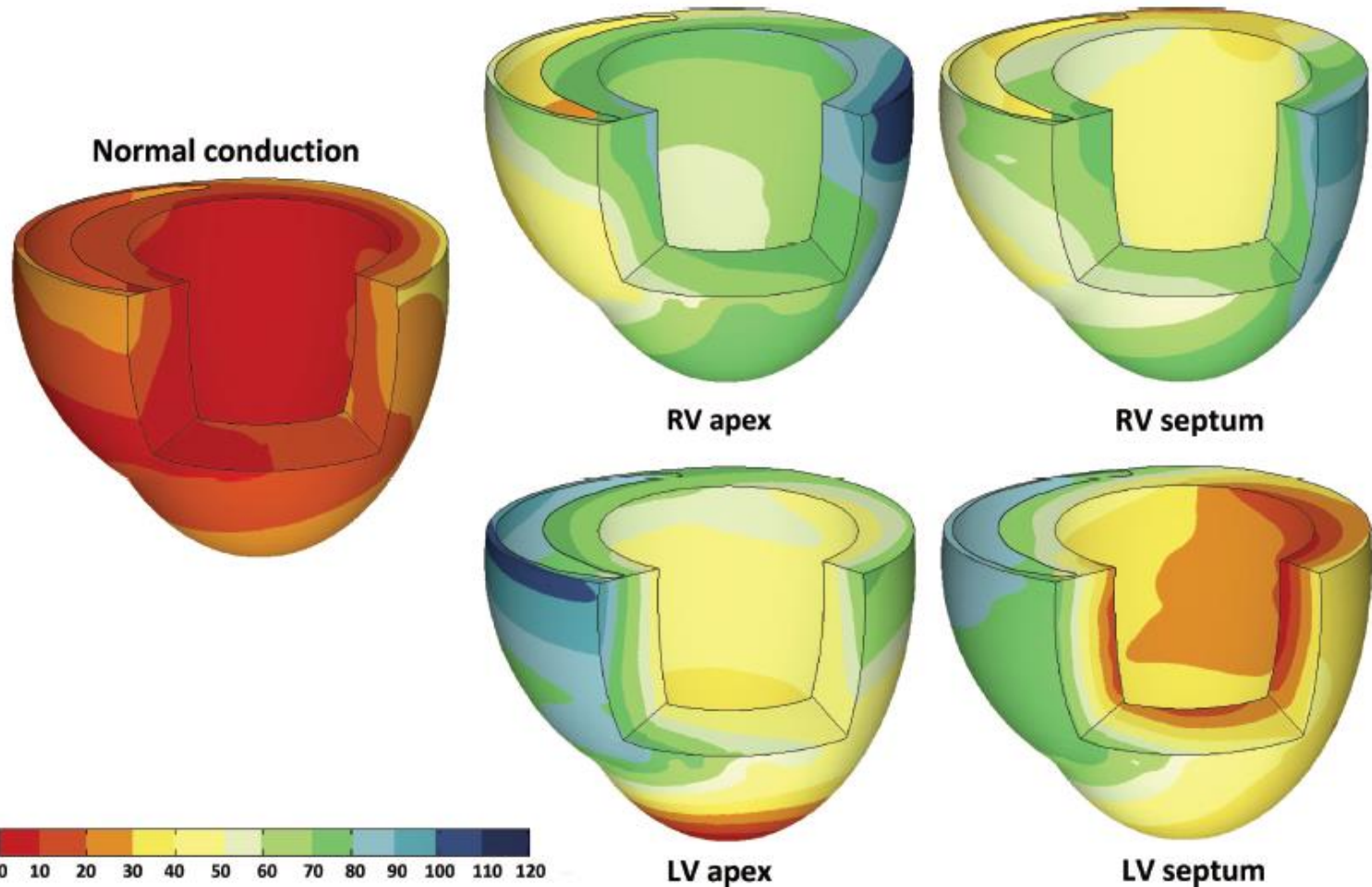
Search for alternative pacing sites!



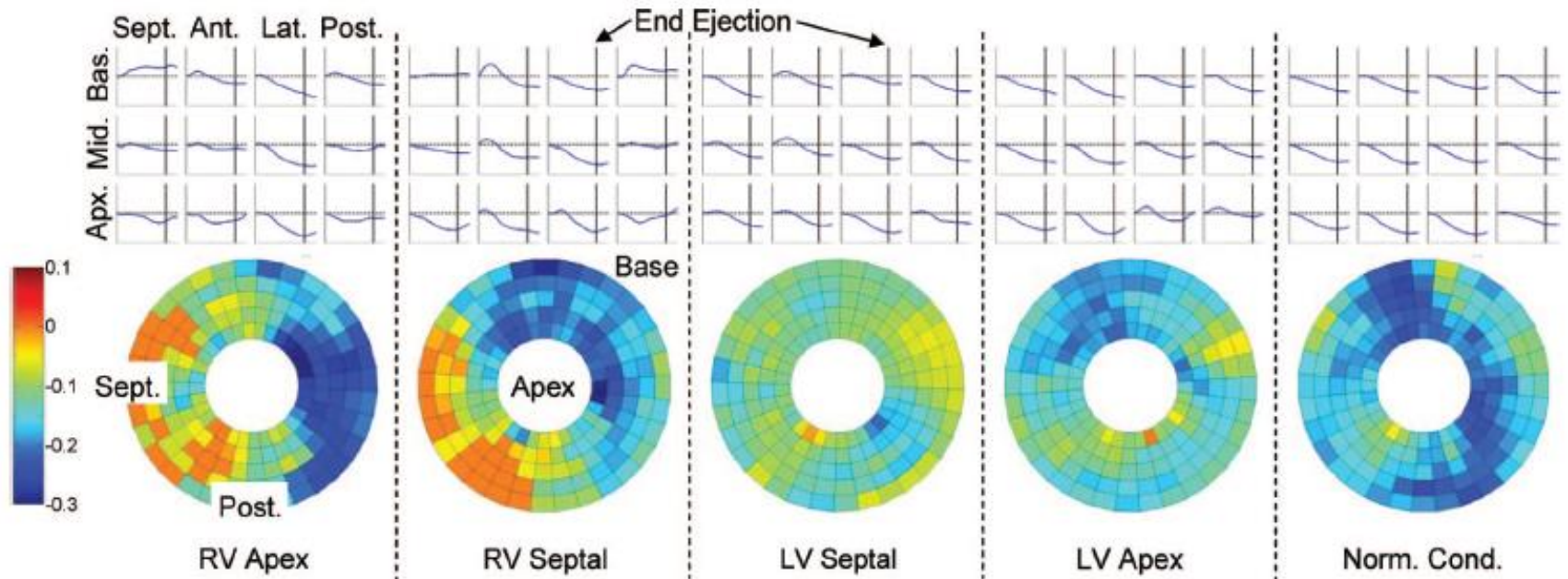
Yu. NEJM 2009



# Dyssynchronie

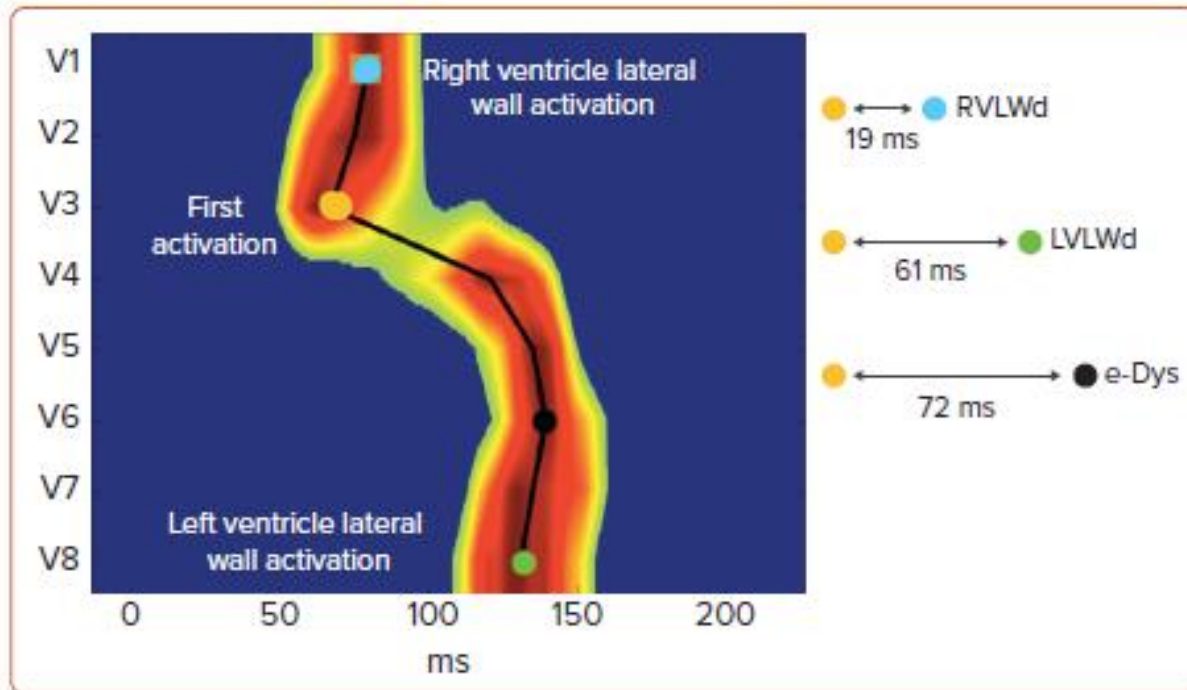


# Dyssynchronie

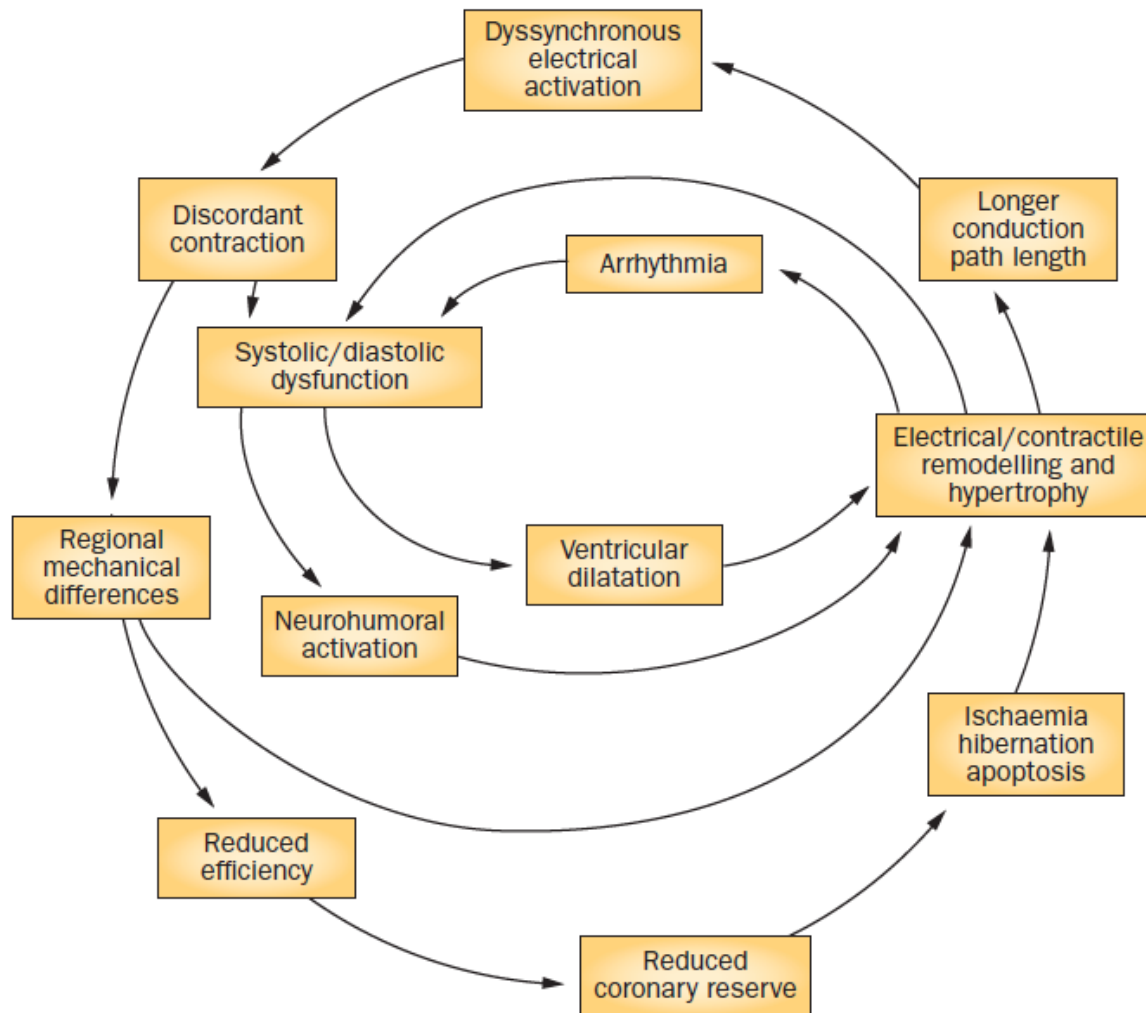


# Dyssynchronie

Figure 2: Ultra-high-frequency ECG Map in Right Ventricular Septal Pacing



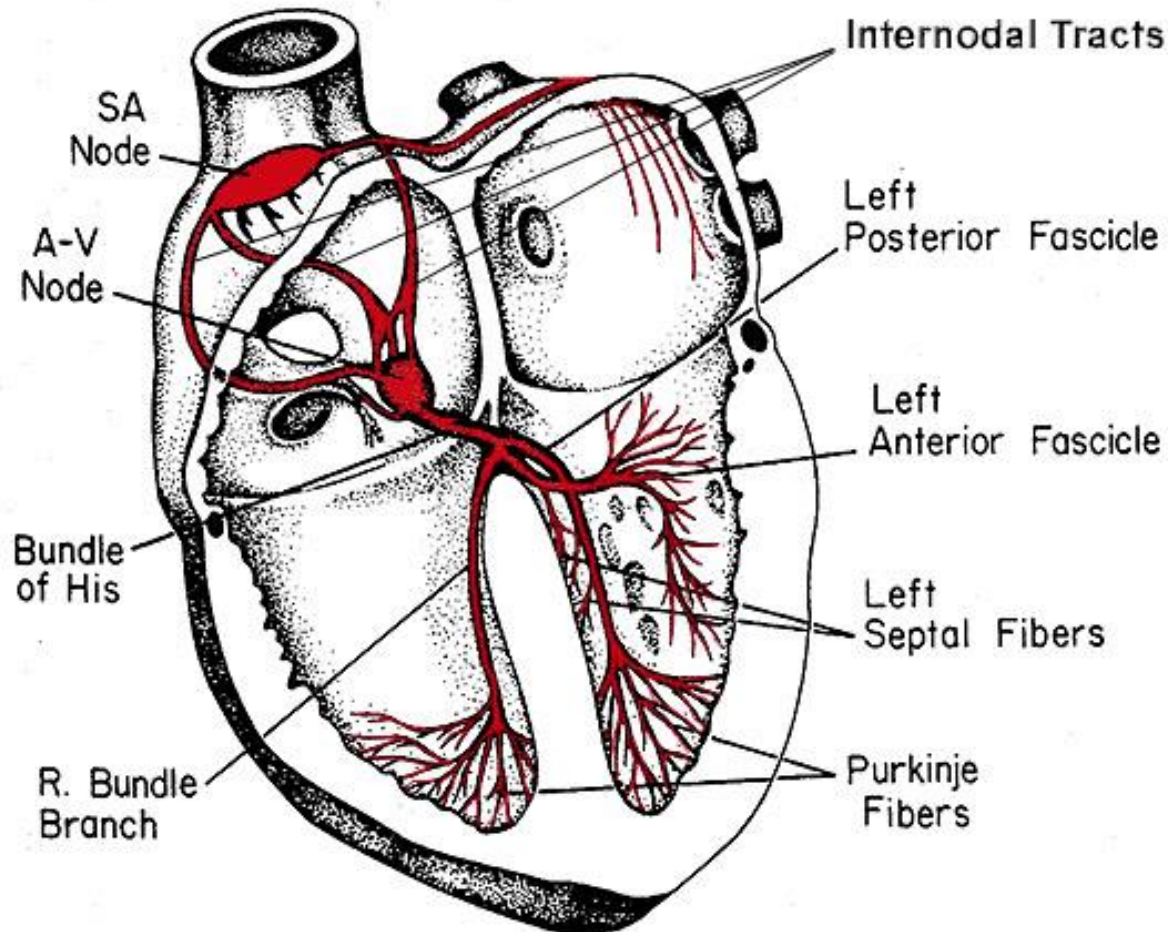
# Dyssynchronie



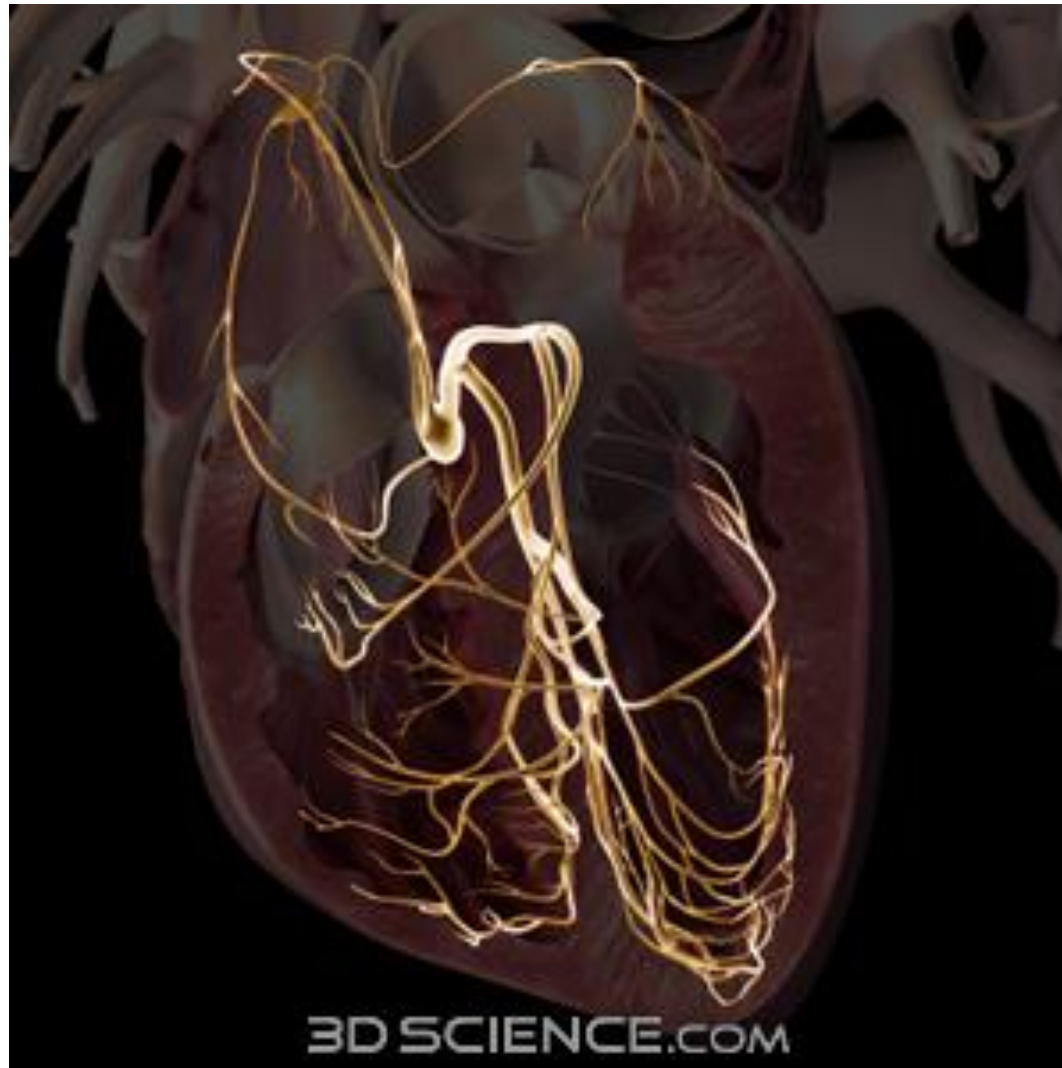
## Nadelen huidige vormen van pacing

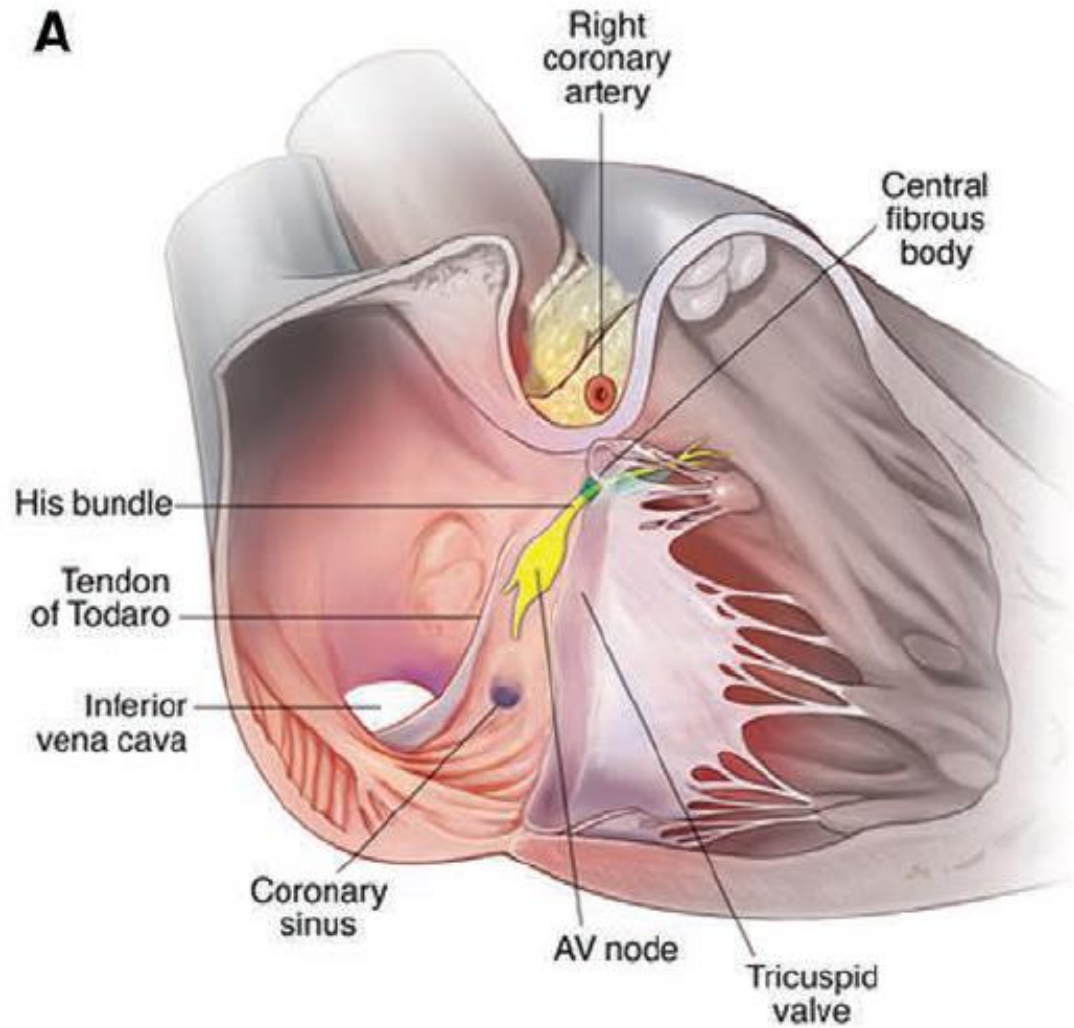
### RV pacing

- ✓ -Dyssynchronopathie: LV-dysfunctie
- ✓ -20% ~ > 20% RV pacing
- ✓ -Geen aangetoond verschil apicaal / septaal / outflowtract

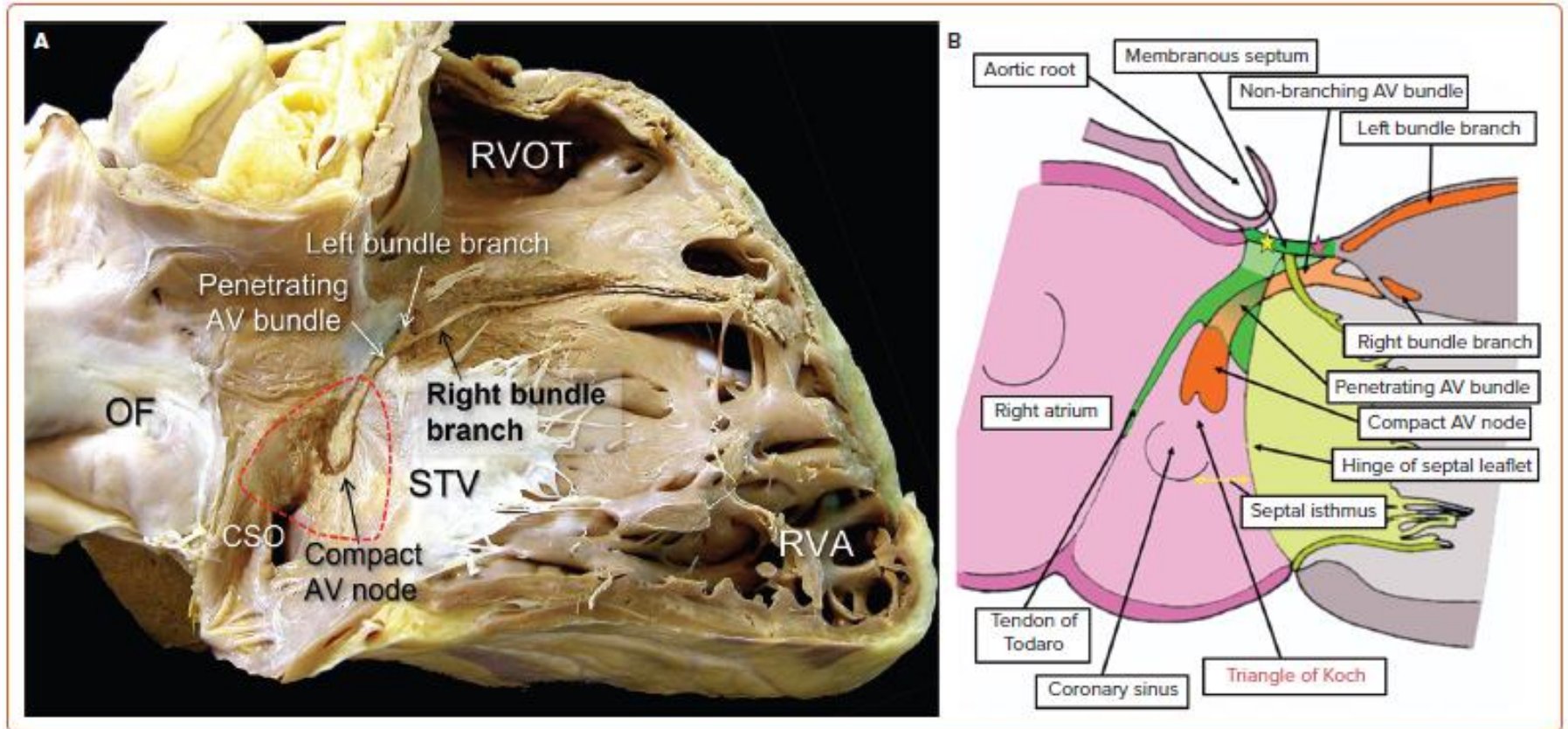


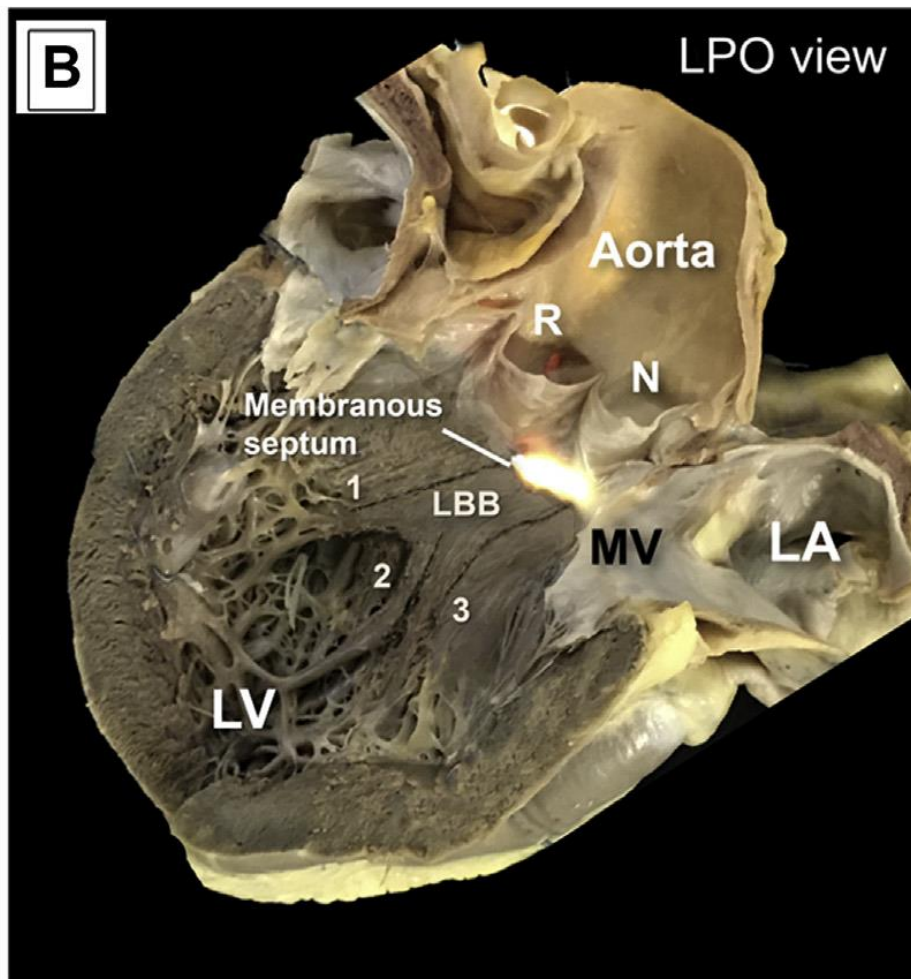
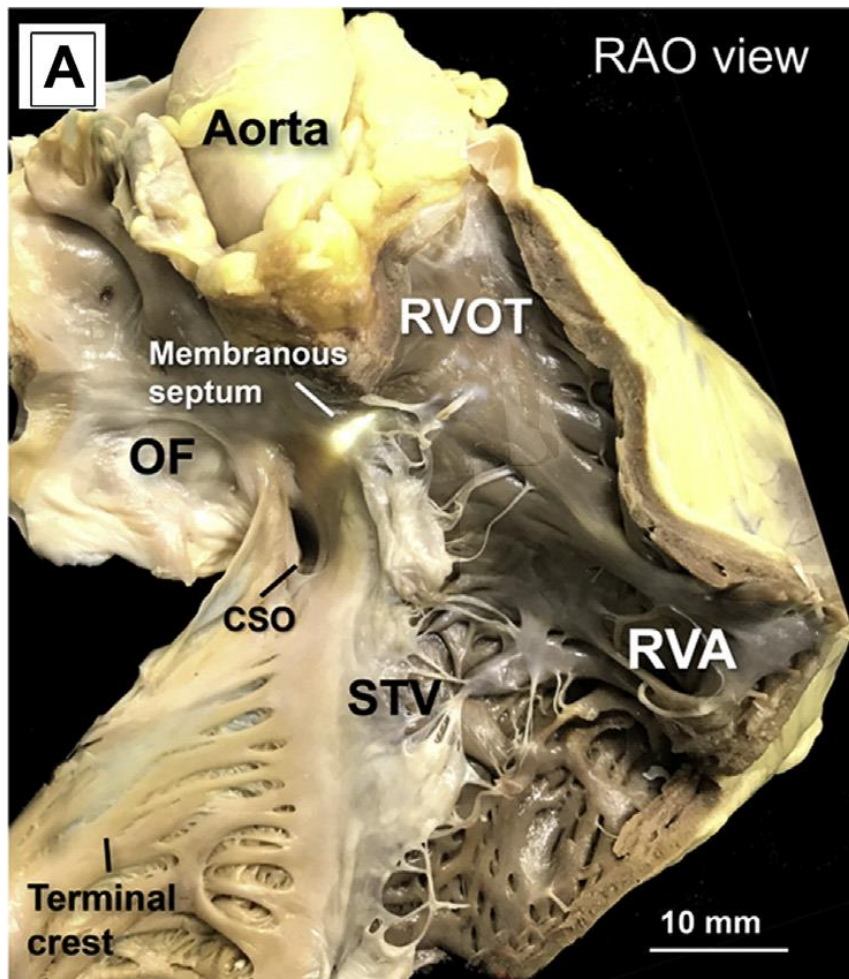
# Anatomie

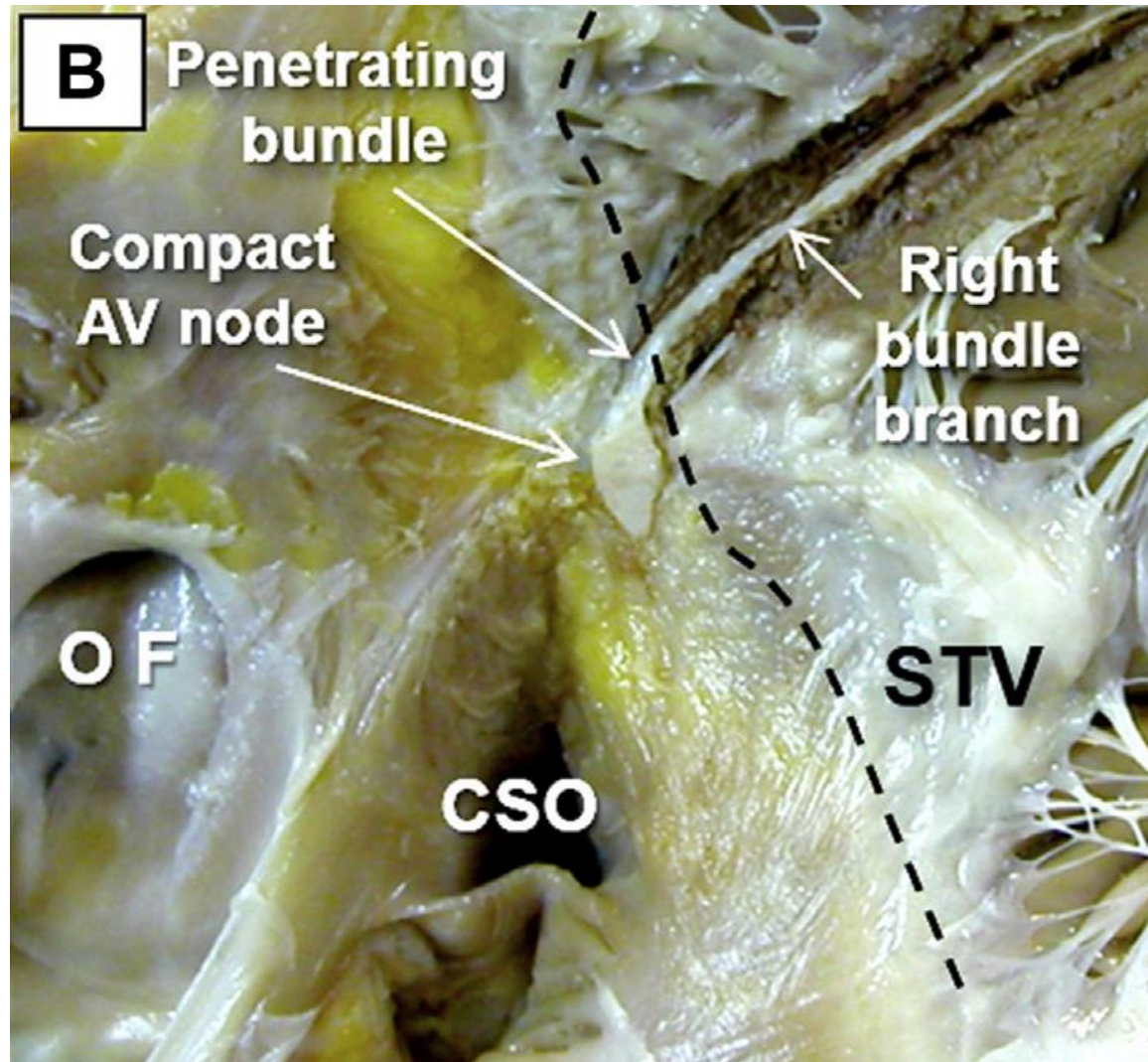


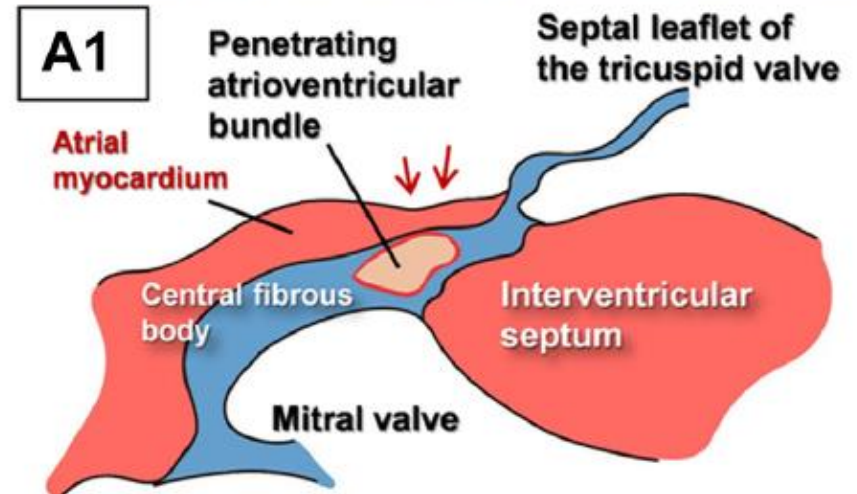
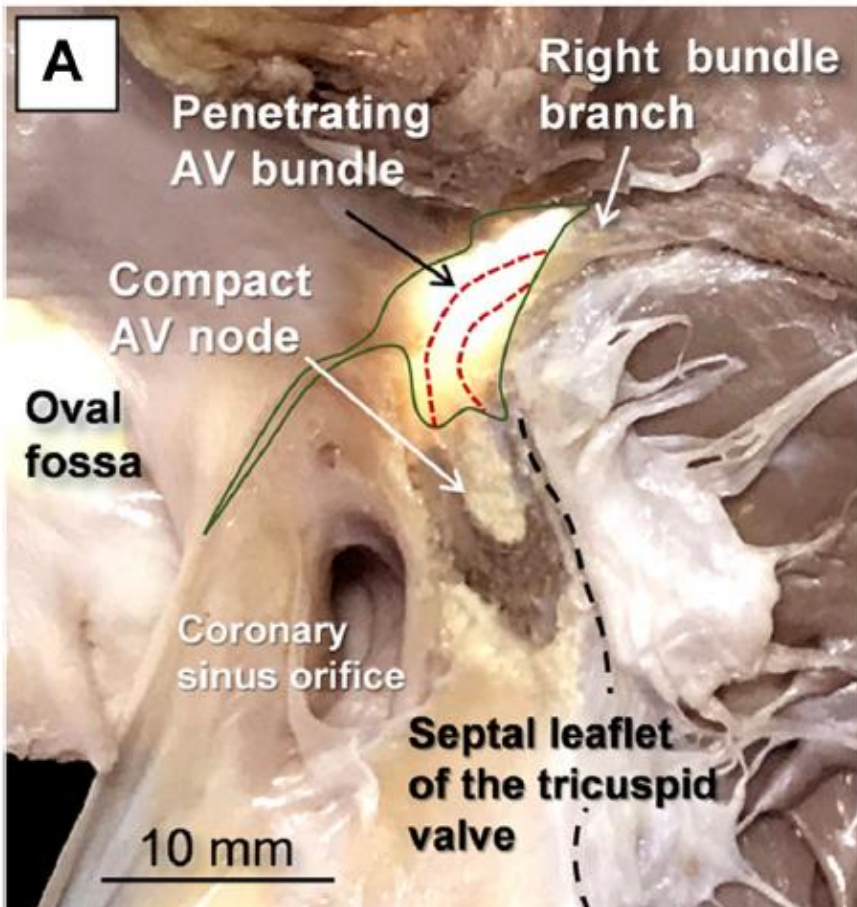




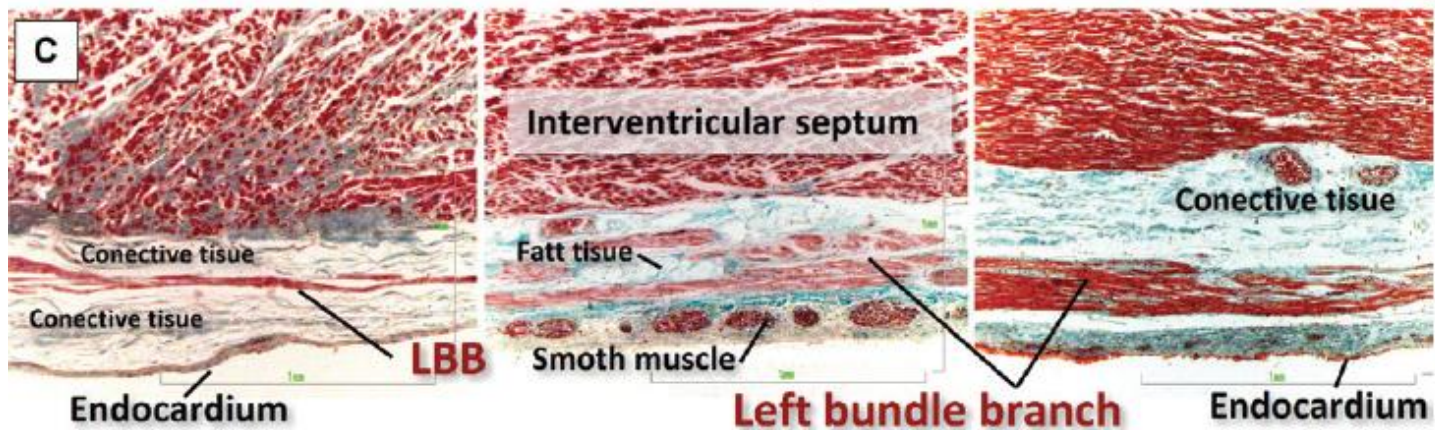
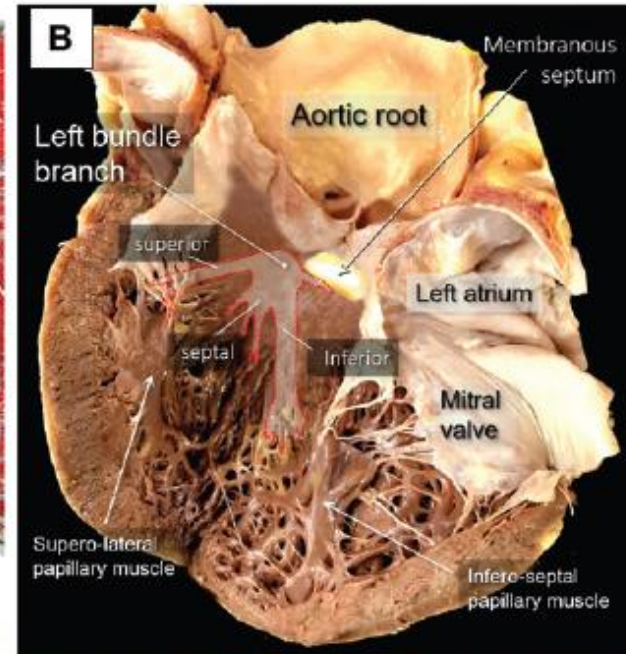
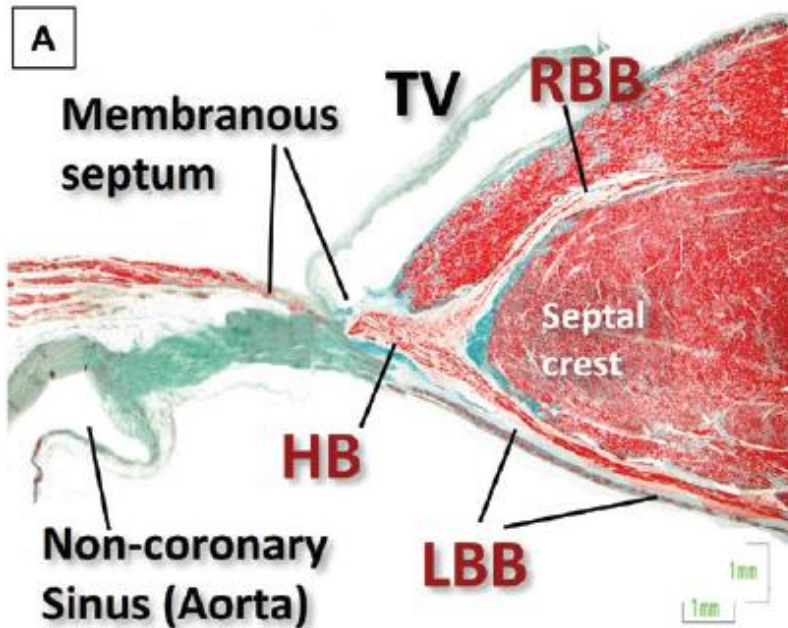


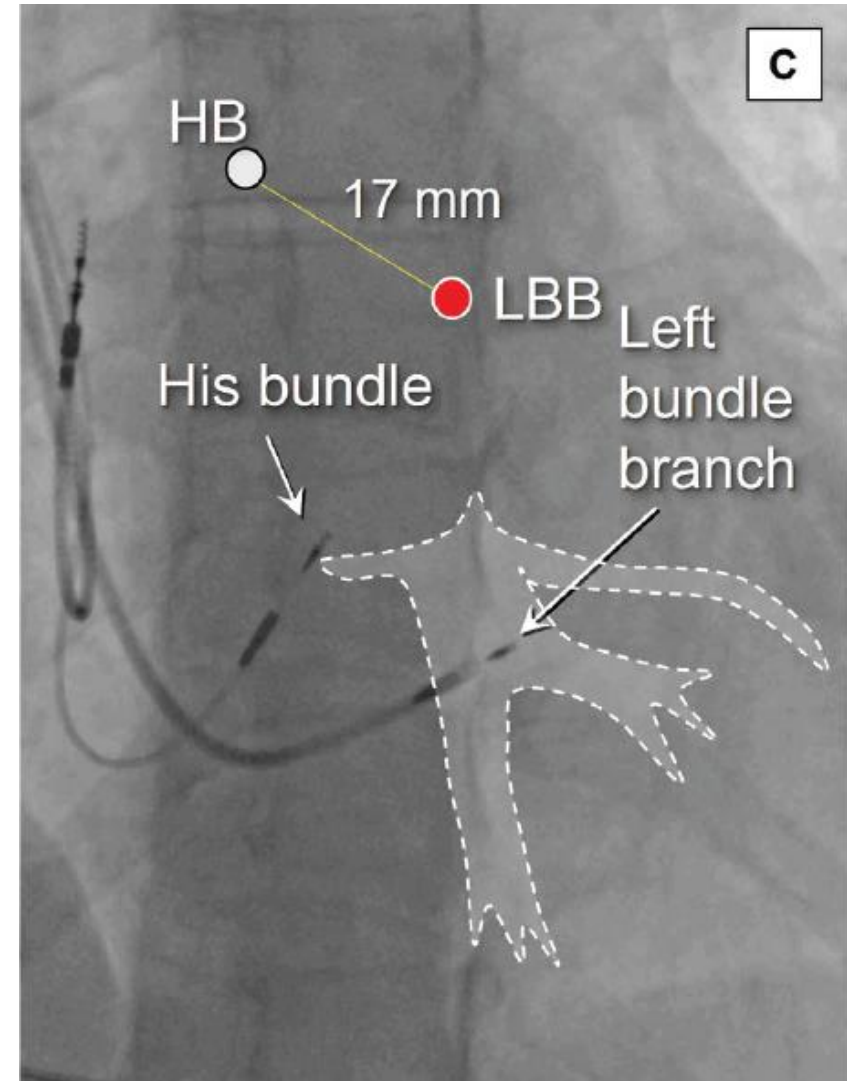
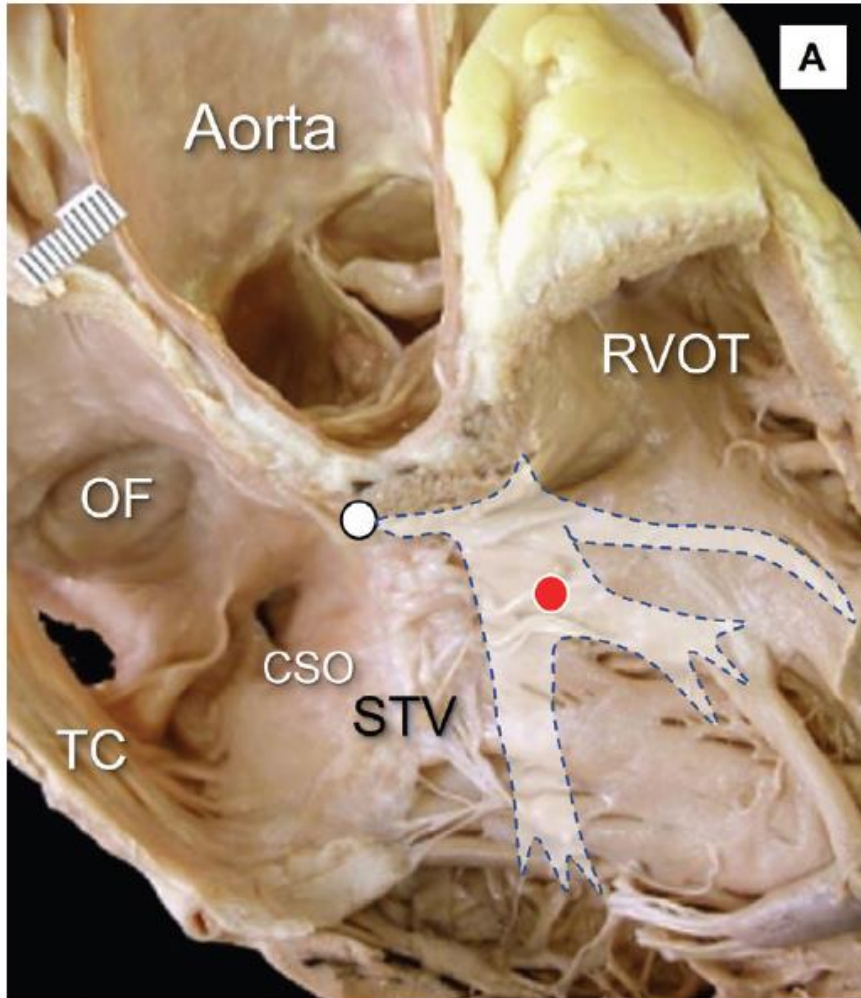




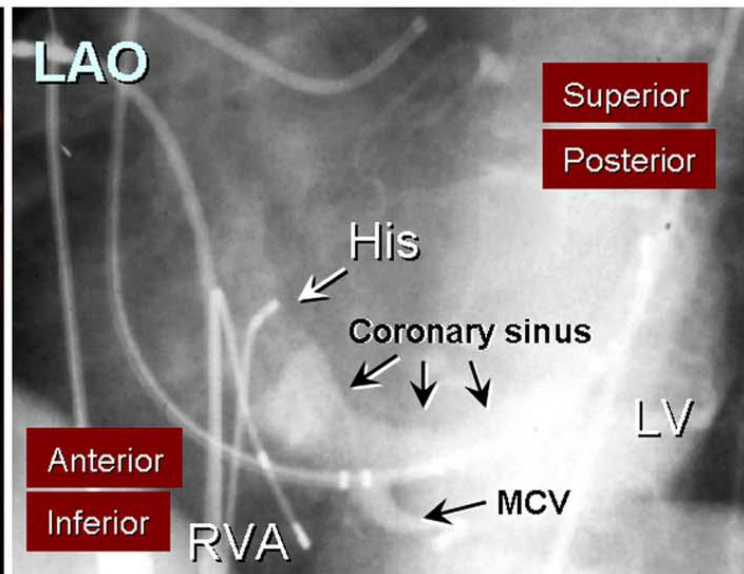
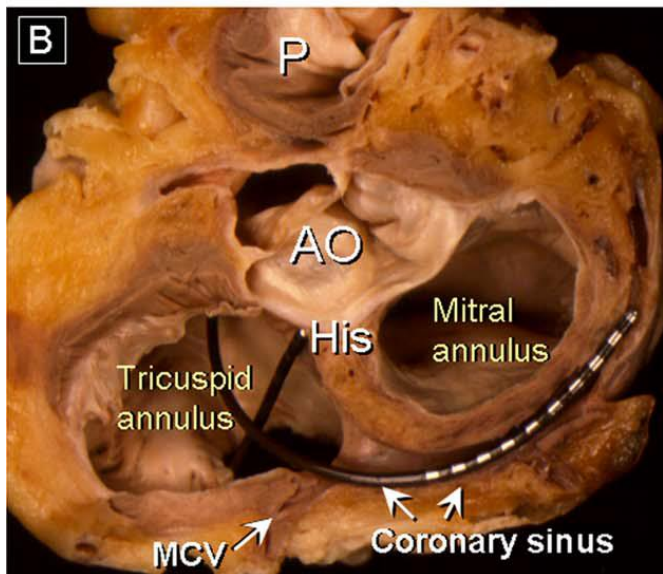
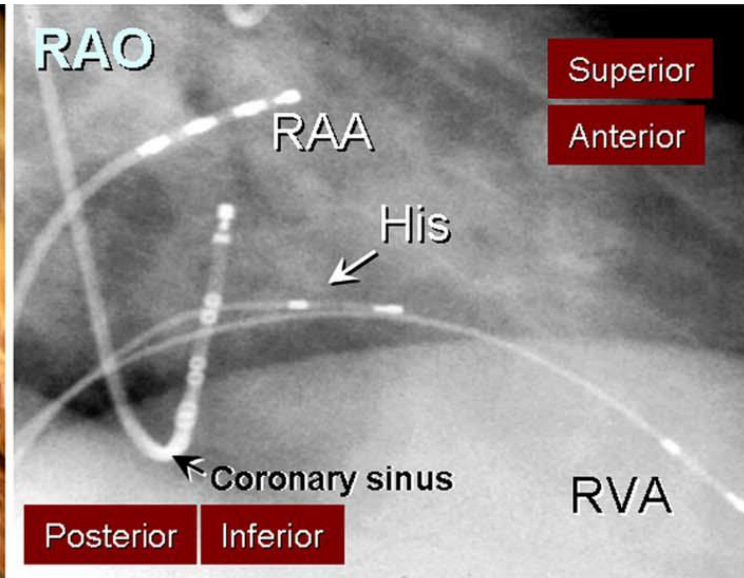
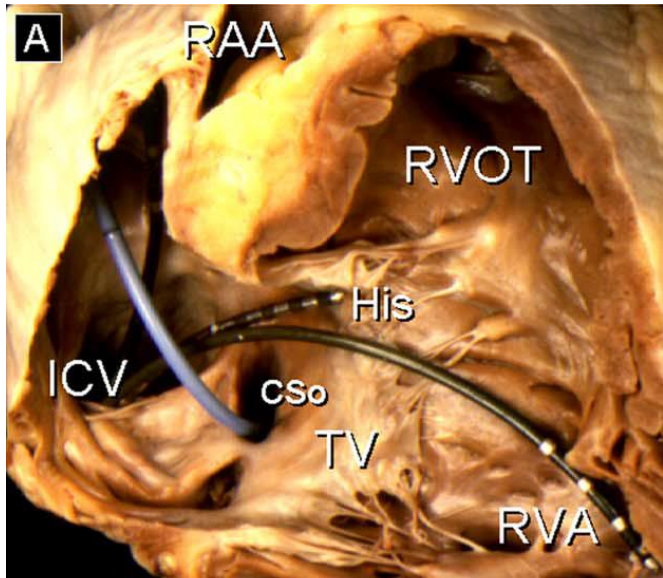


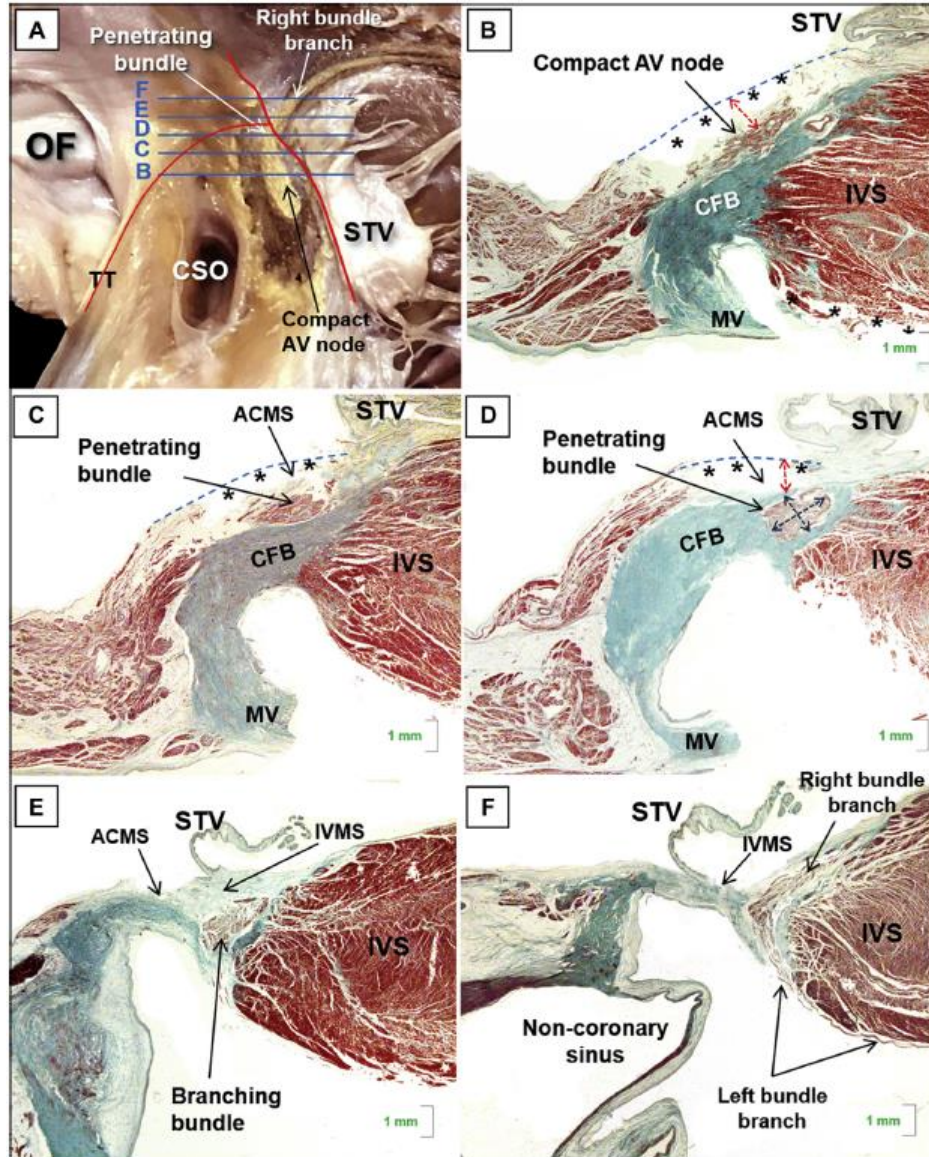
# Anatomie





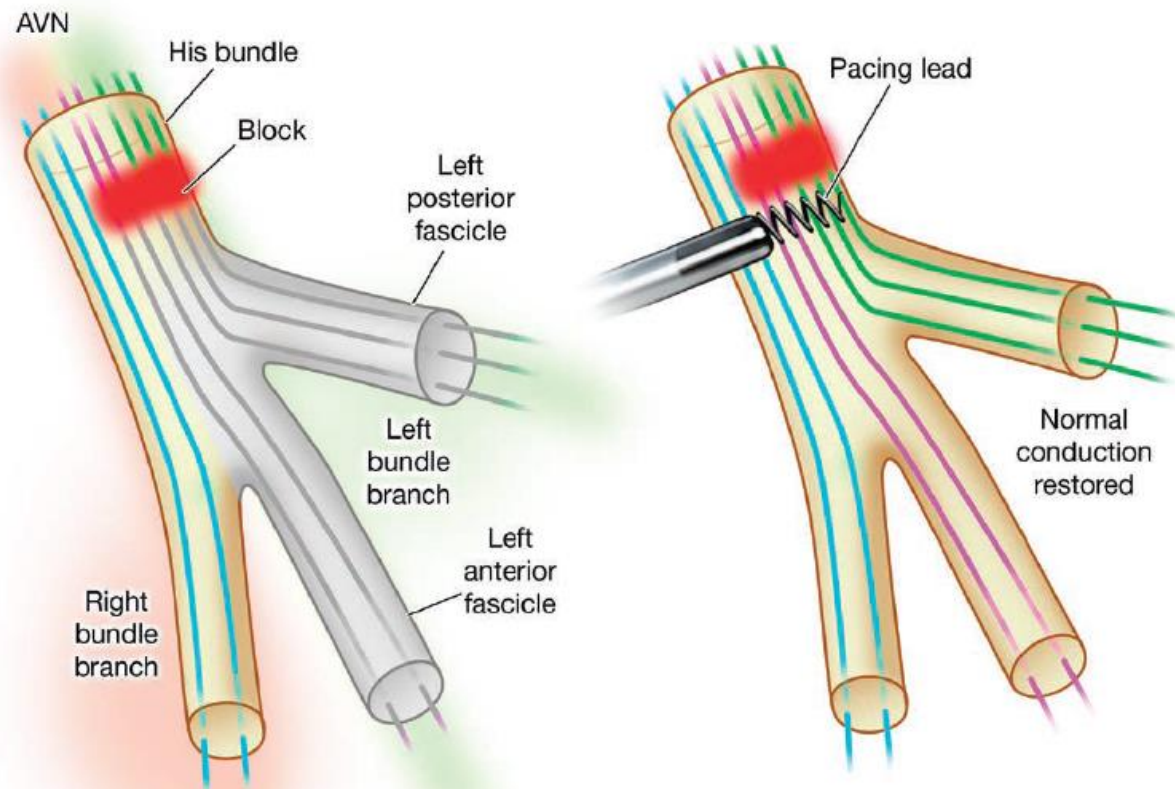
# Anatomie



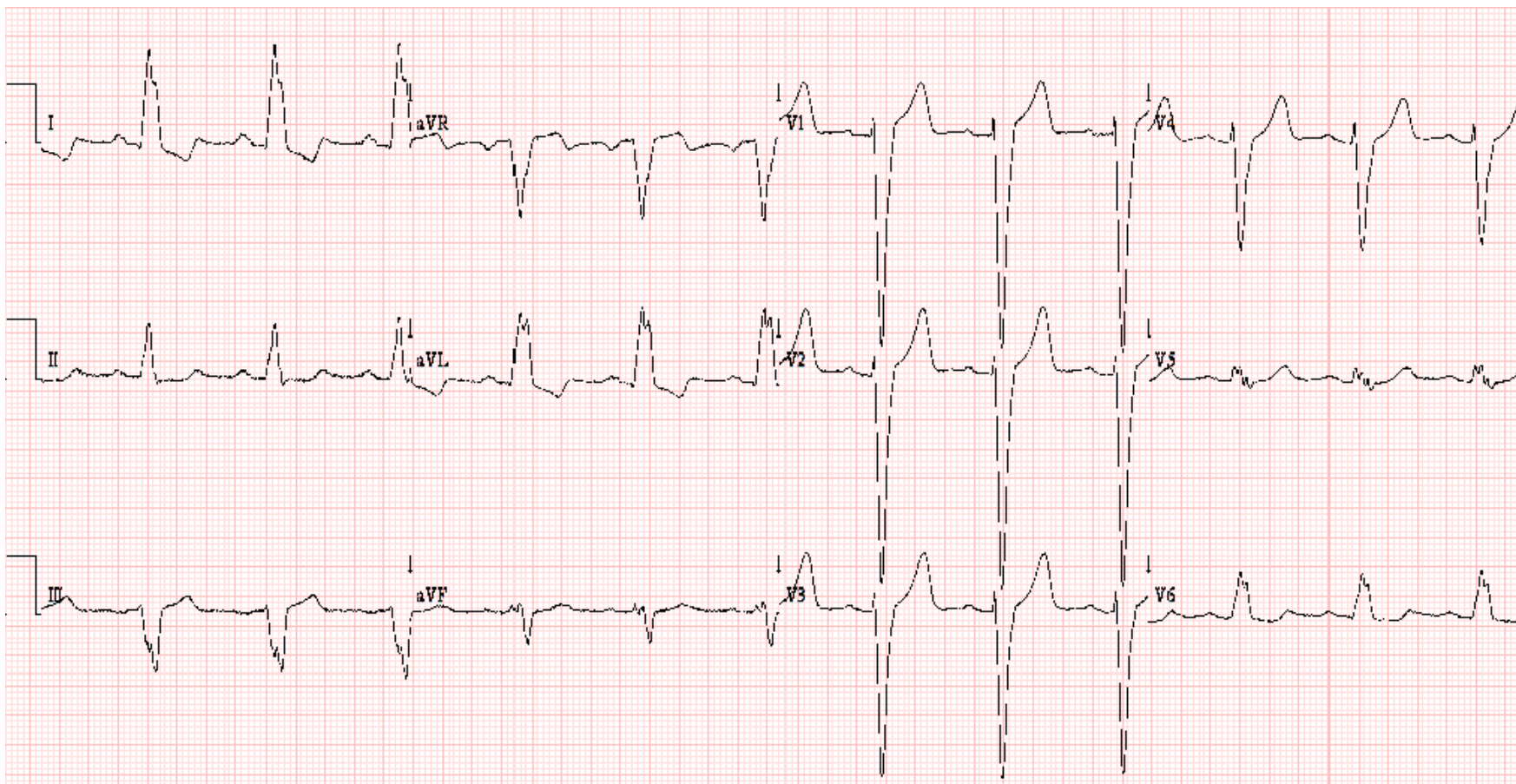




## Longitudinale dissociatie

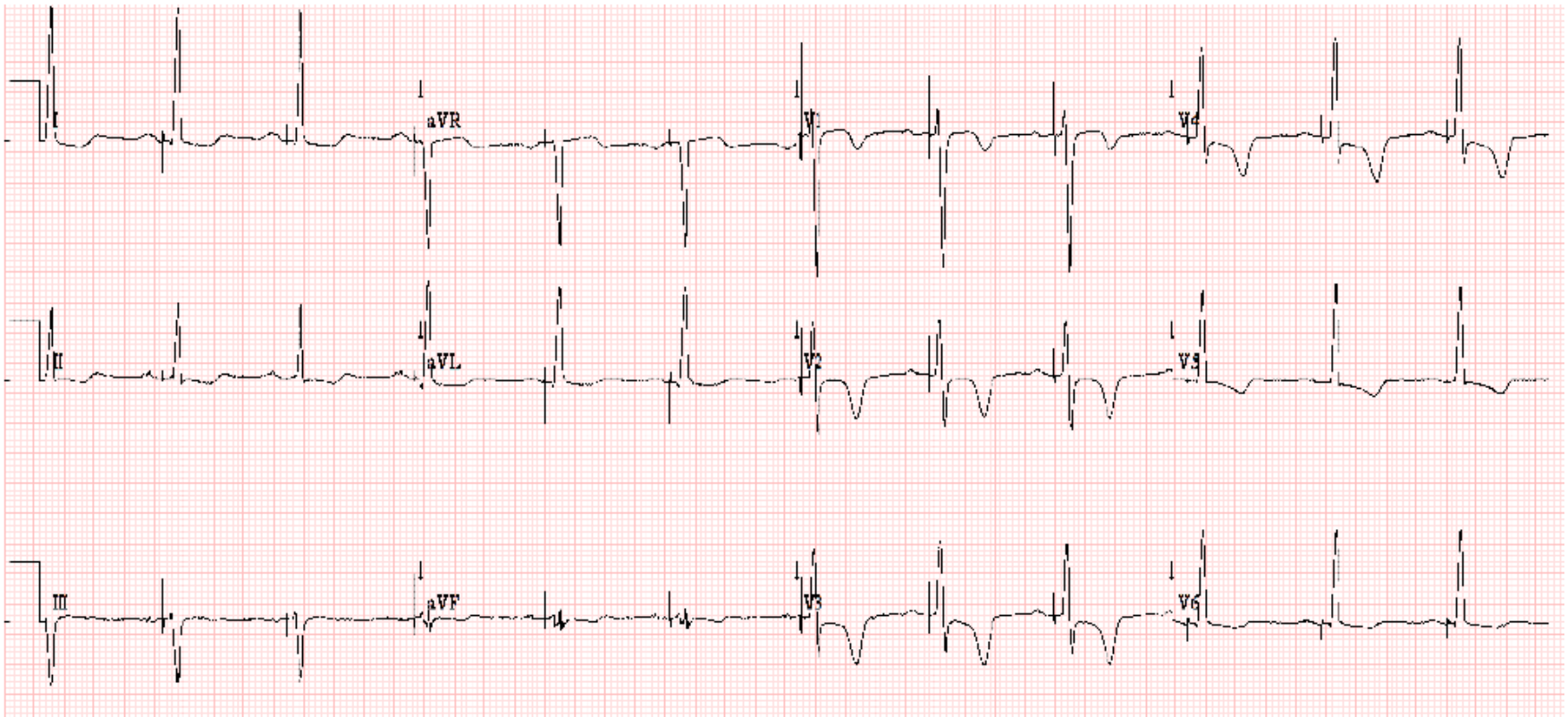


## Longitudinale dissociatie



# LBTB correctie

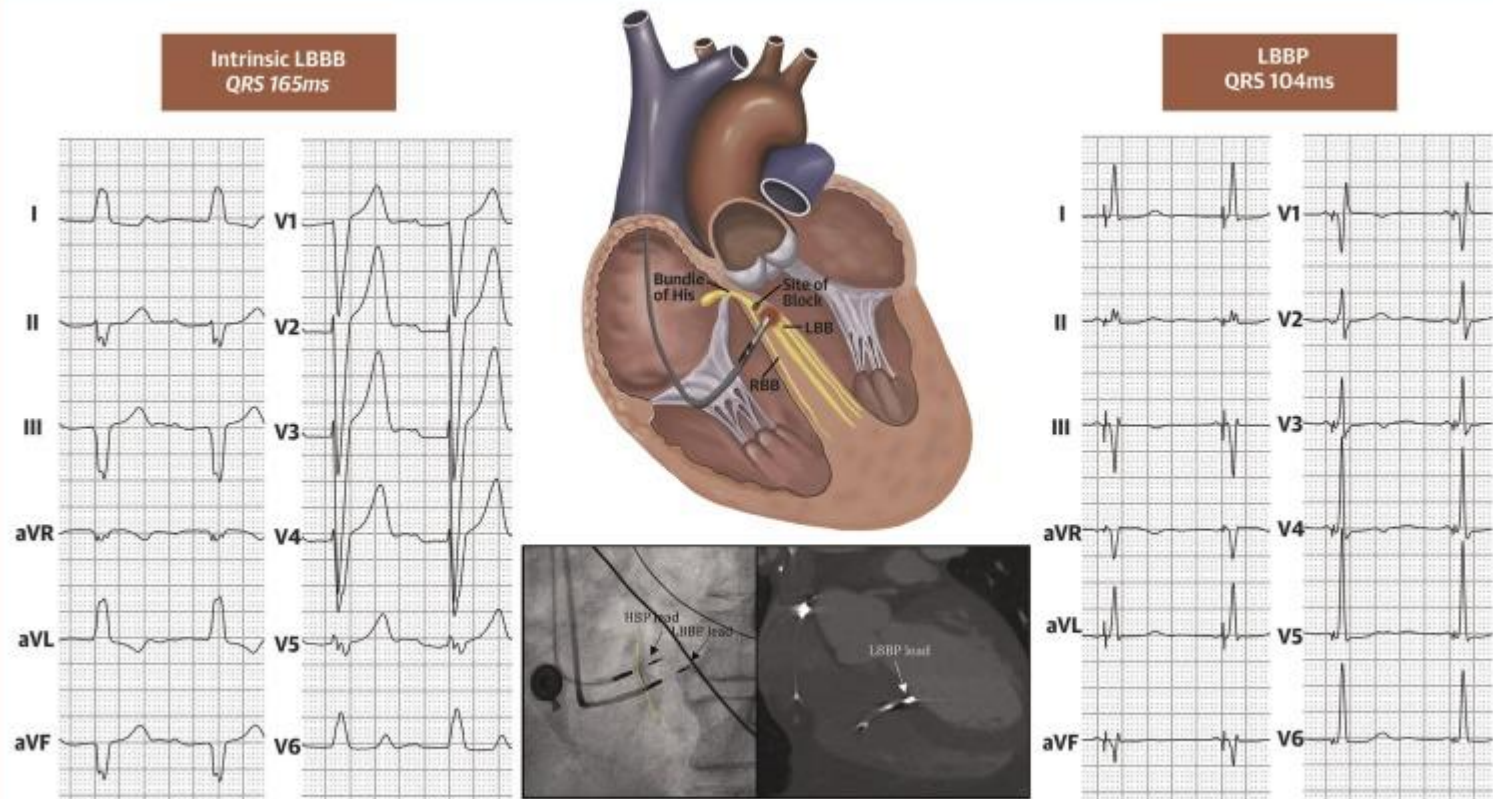
## Longitudinale dissociatie



**Na His-bundel pacing**

# LBTB correctie

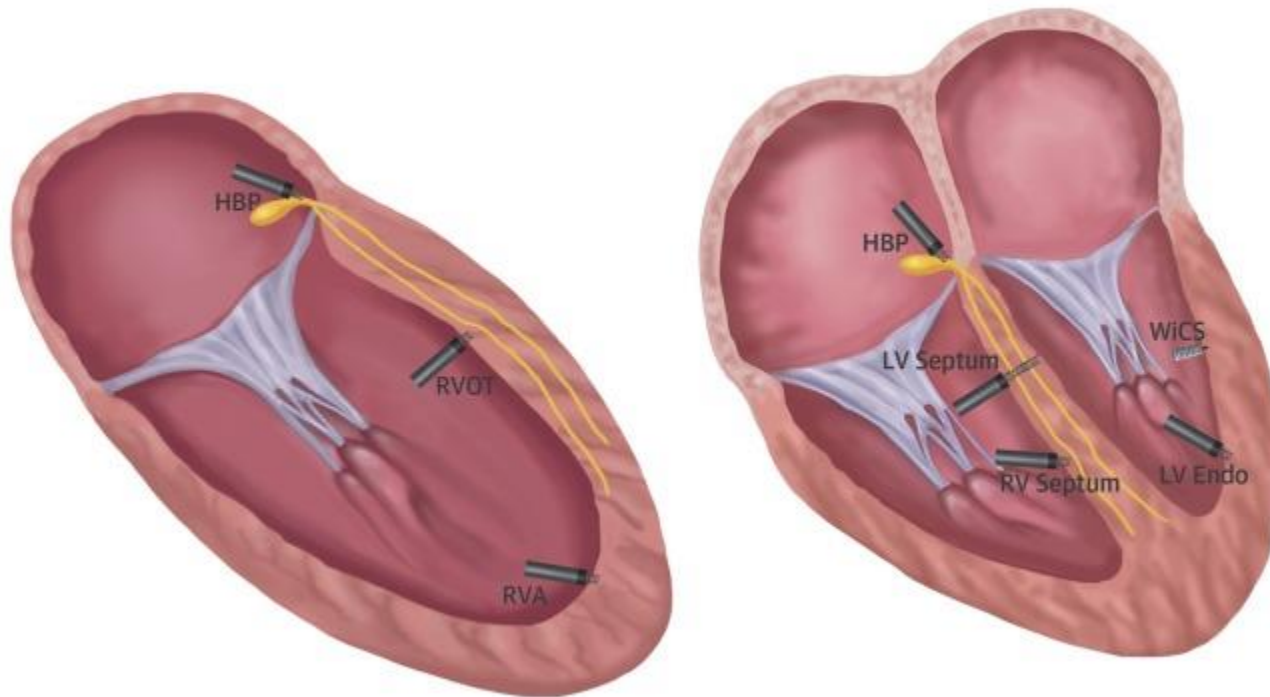
## CENTRAL ILLUSTRATION: Correction of LBBB Pattern With LBBP



Huang, W. et al. J Am Coll Cardiol EP. 2020;6(7):849-58.

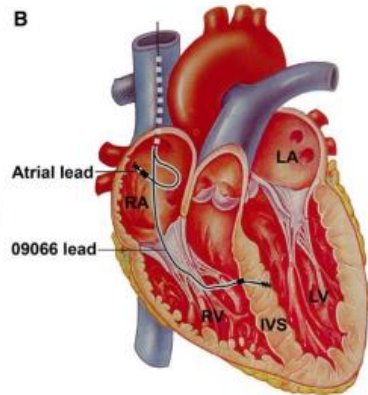
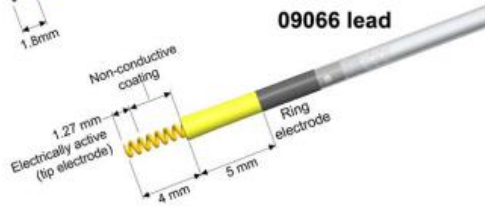
# Fysiologisch pacen

## CENTRAL ILLUSTRATION: Alternative Pacing Sites to Mimic Physiological Pacing

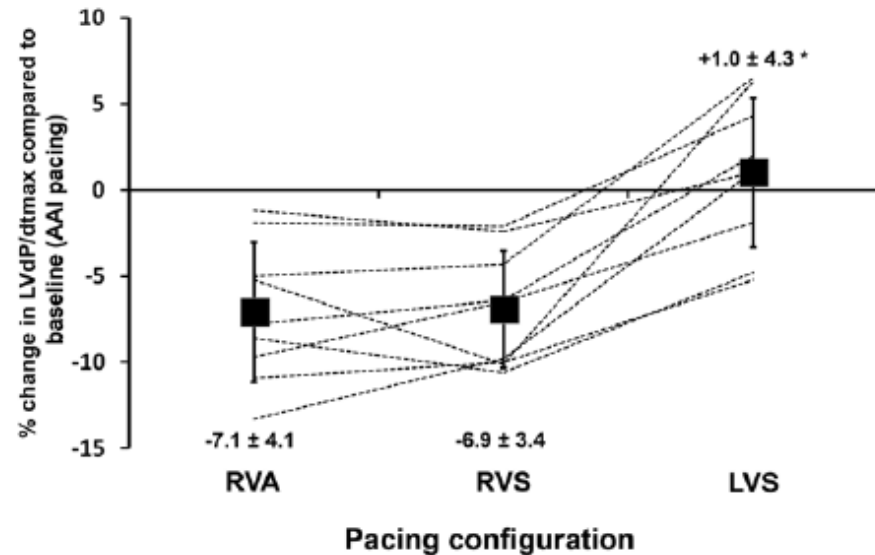


Vijayaraman, P. et al. J Am Coll Cardiol. 2017;69(25):3099-114.

# Fysiologisch pacen



Mafi Rad. Circ AE 2016



Canadian Journal of Cardiology 33 (2017) 1736.e1–1736.e3 www.onlinecjc.ca

## Case Report

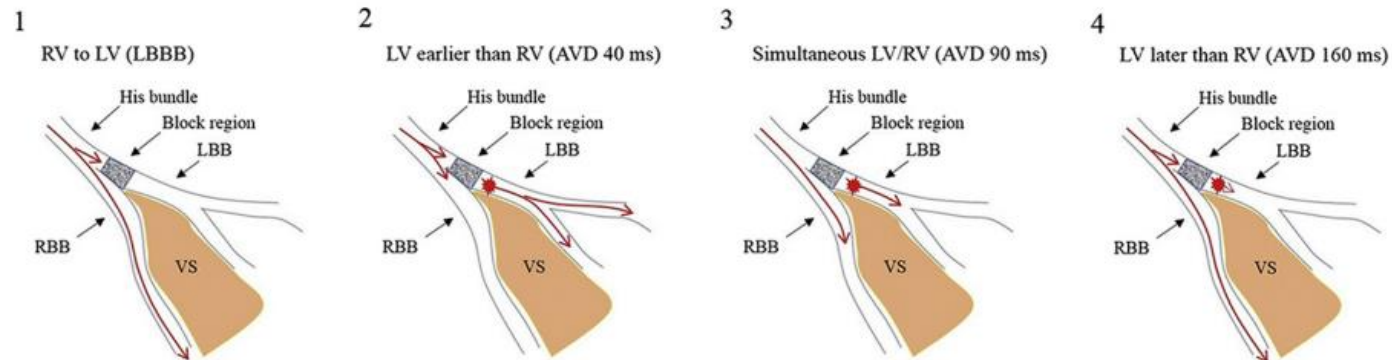
### A Novel Pacing Strategy With Low and Stable Output: Pacing the Left Bundle Branch Immediately Beyond the Conduction Block

Weijian Huang, MD, FHRS,<sup>a</sup> Lan Su, MD,<sup>a</sup> Shengjie Wu, MD,<sup>a</sup> Lei Xu, MD,<sup>a</sup> Fangyi Xiao, MD,<sup>a</sup>  
Xiaohong Zhou, MD,<sup>b</sup> and Kenneth A. Ellenbogen, MD, FHRS<sup>c</sup>

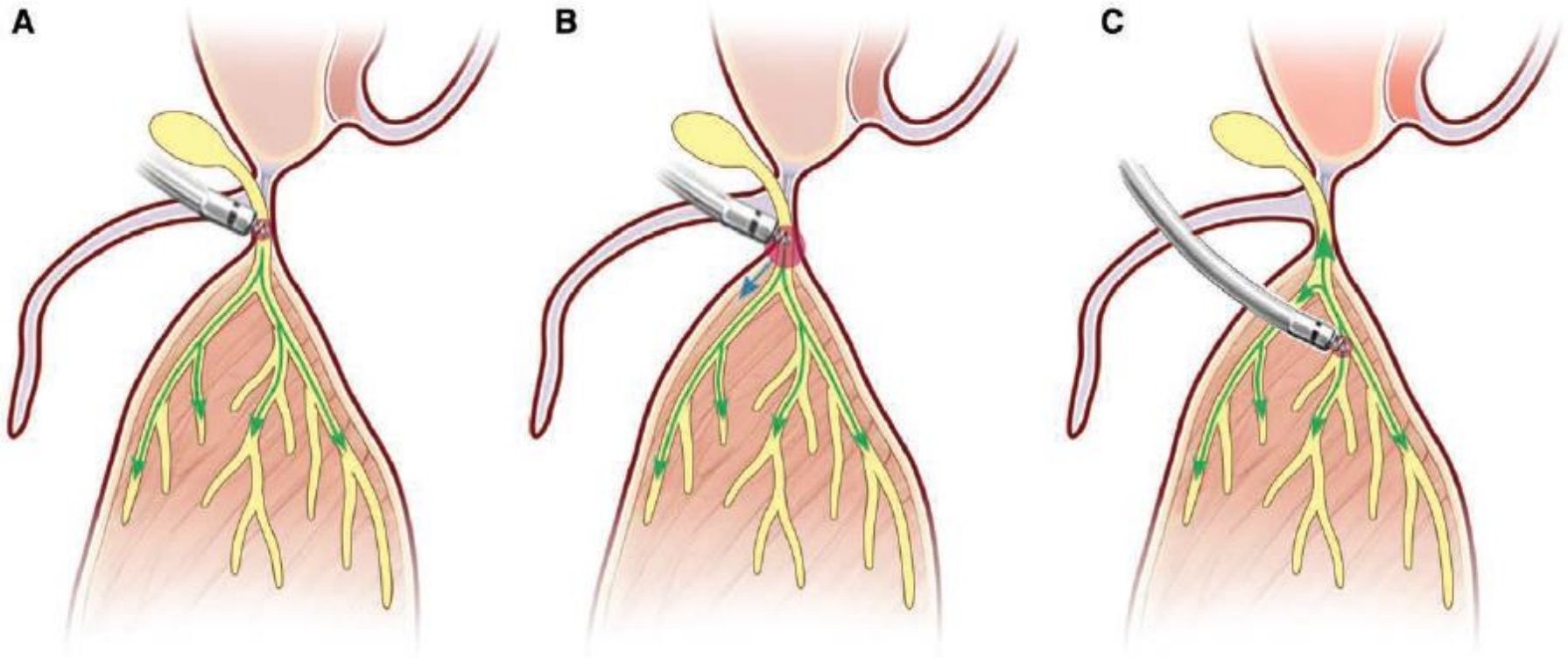
<sup>a</sup>Department of Cardiology, First Affiliated Hospital of Wenzhou Medical University, Key Lab of Cardiovascular Disease of Wenzhou, Wenzhou, China

<sup>b</sup>CRHF Division, Medtronic PLC, Mounds View, Minnesota, USA

<sup>c</sup>Department of Cardiology, Virginia Commonwealth University Health System, Richmond, Virginia, USA



# Fysiologisch pacen

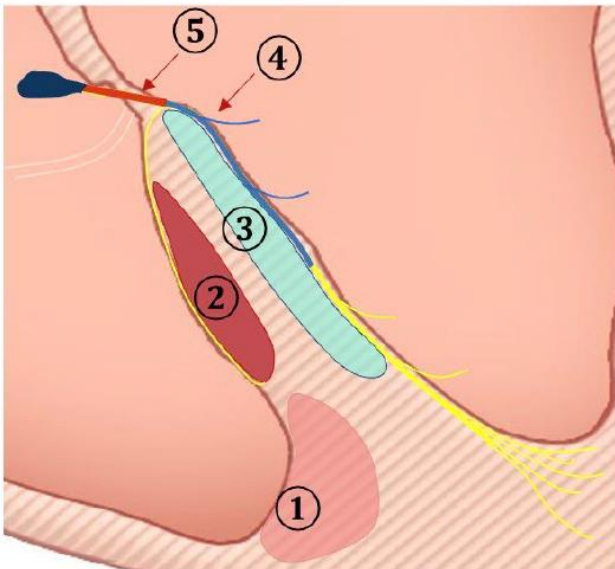




# Fysiologisch pacen

1

- 1 RV apex
- 2 RV septum



## Conduction system pacing (CSP)

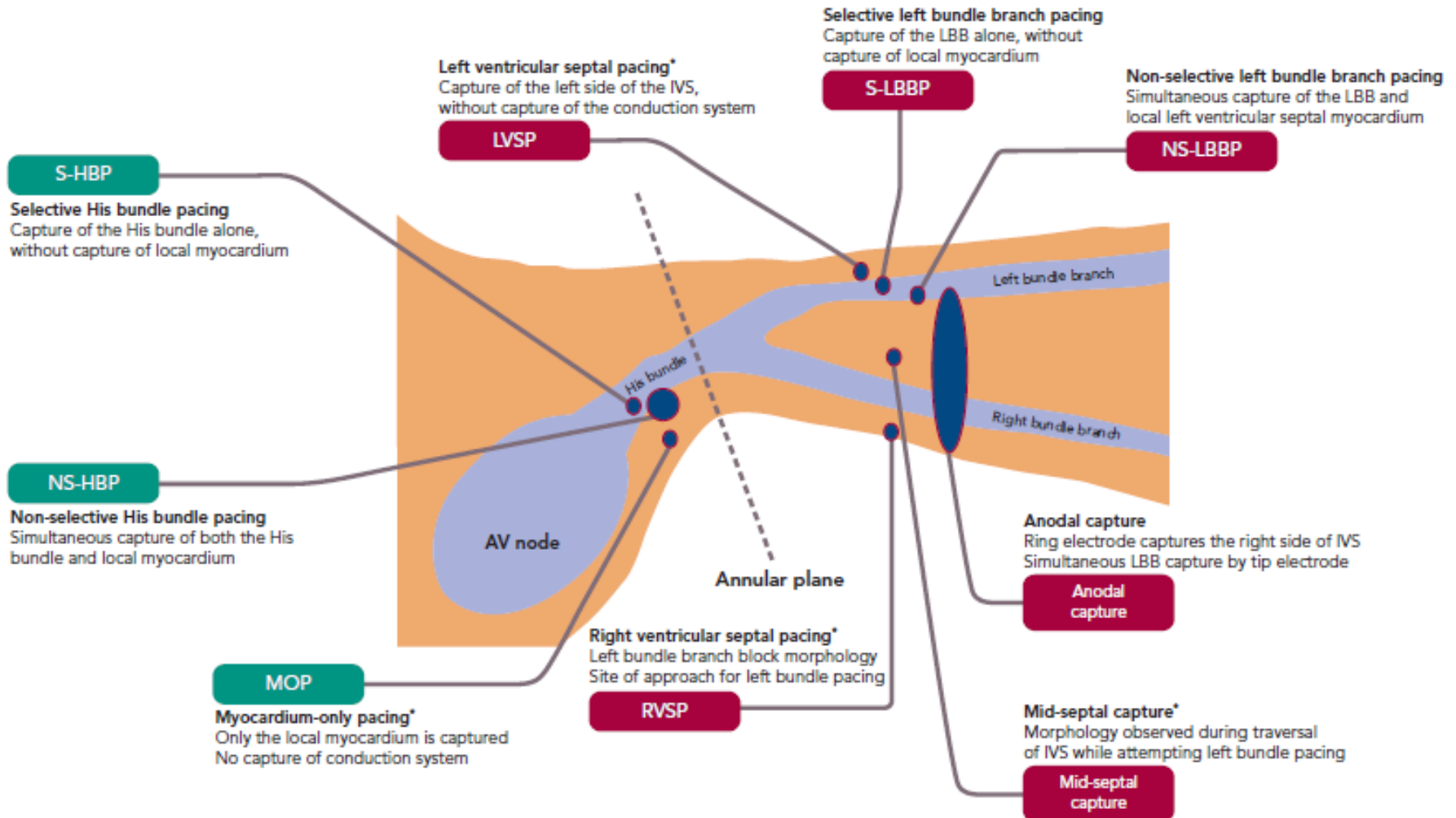
5 His bundel pacing (HBP)

3 Left bundle area pacing (LBBap)

4 Left bundle pacing

(LV septal pacing)

# Fysiologisch pacen



# Fysiologisch pacen

## Kenmerken

- Via His-purkinje-systeem
- His-bundel pacing:
  - Hoge drempels
  - Complexer
  - Far-field atriale oversensing
- Alternatief: LB pacing
  - Hoge R-top
  - Lage drempel
  - Technisch eenvoudiger
  - Grote 'sweetspot' linkerbundel

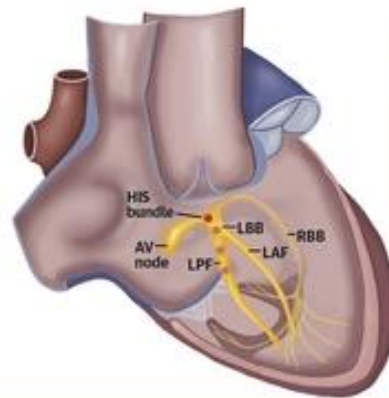
# Fysiologisch pacen

## CENTRAL ILLUSTRATION: HBP Compared With LBBAP

A

### ● His Bundle Pacing

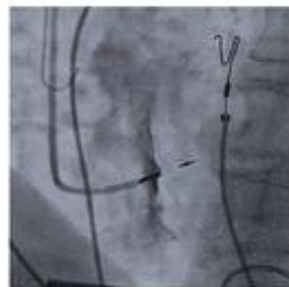- Technically challenging
- Narrow target zone
- Encased in electrically inert fibrous tissue
- Low success rates in AV block
- High thresholds



### ● Left Bundle Branch Area Pacing

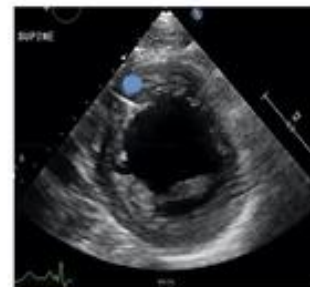- Technically less challenging
- Wide target zone
- Encased in dense muscle
- High success rates in AV block
- Low thresholds

B



Septogram showing lead depth in septum

C



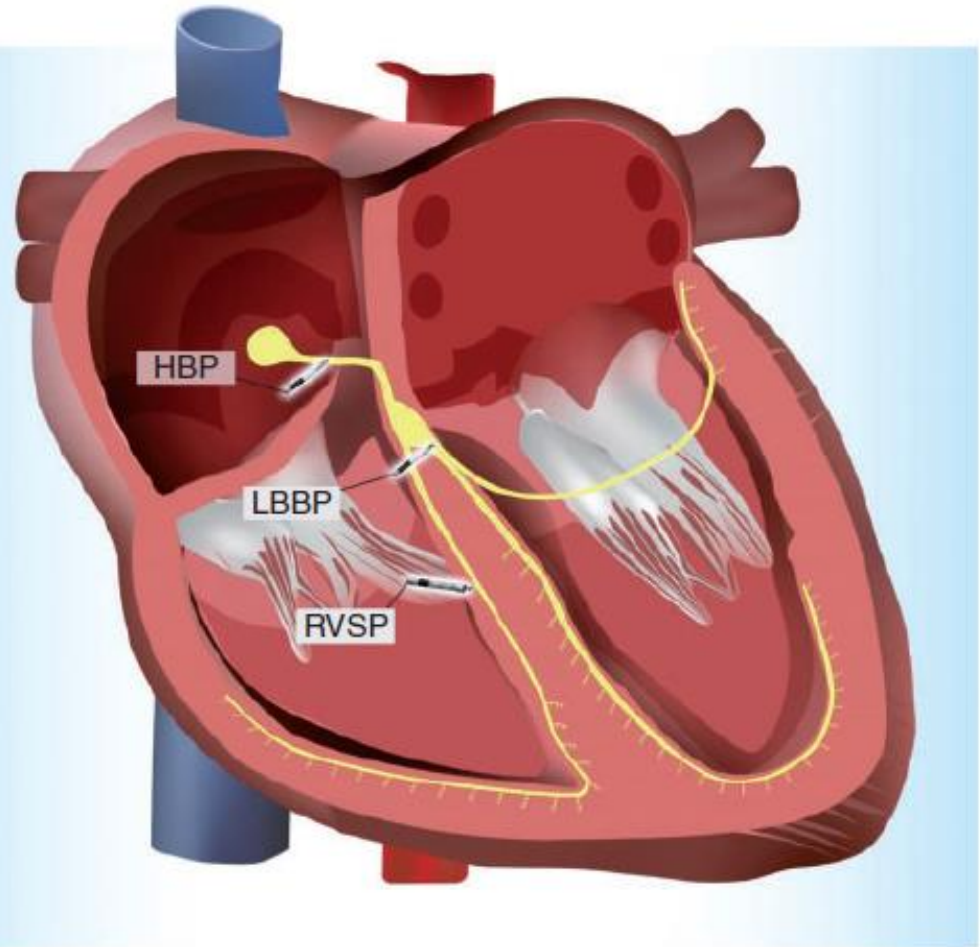
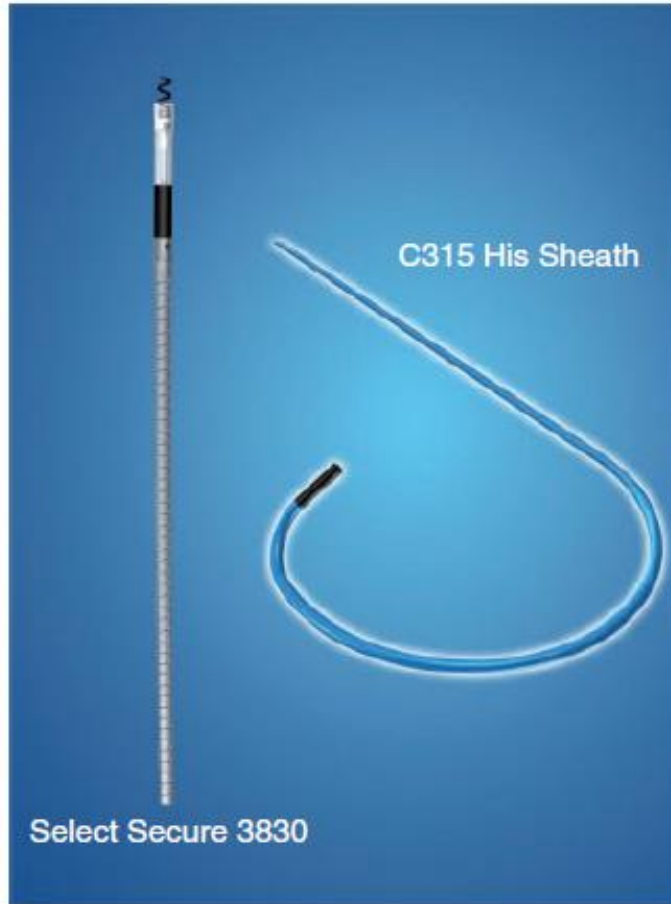● TTE short axis showing lead depth in septum

# Linkerbundel

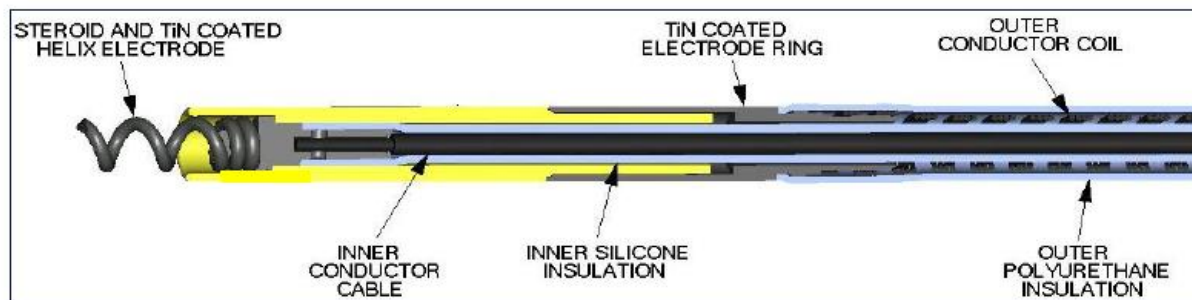
## ‘Sweet spot’



# Materiaal

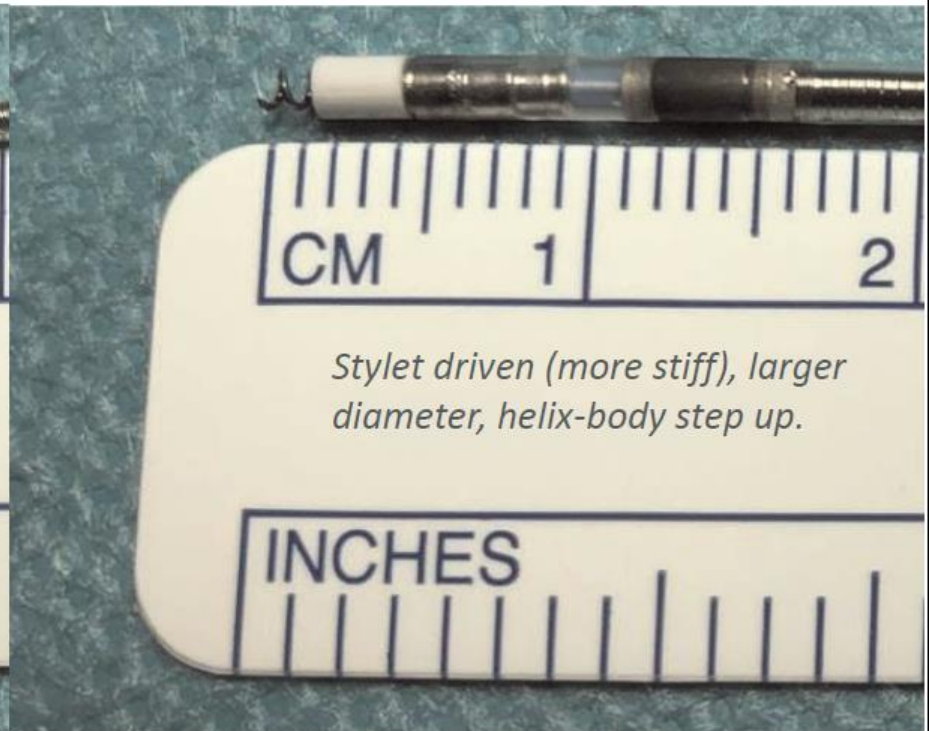

The Model 3830 MRI lead is a steroid eluting, bipolar, implantable non-retractable screw-in, catheter delivered, transvenous lead.



**Cross-sectional view of 3830 lead**

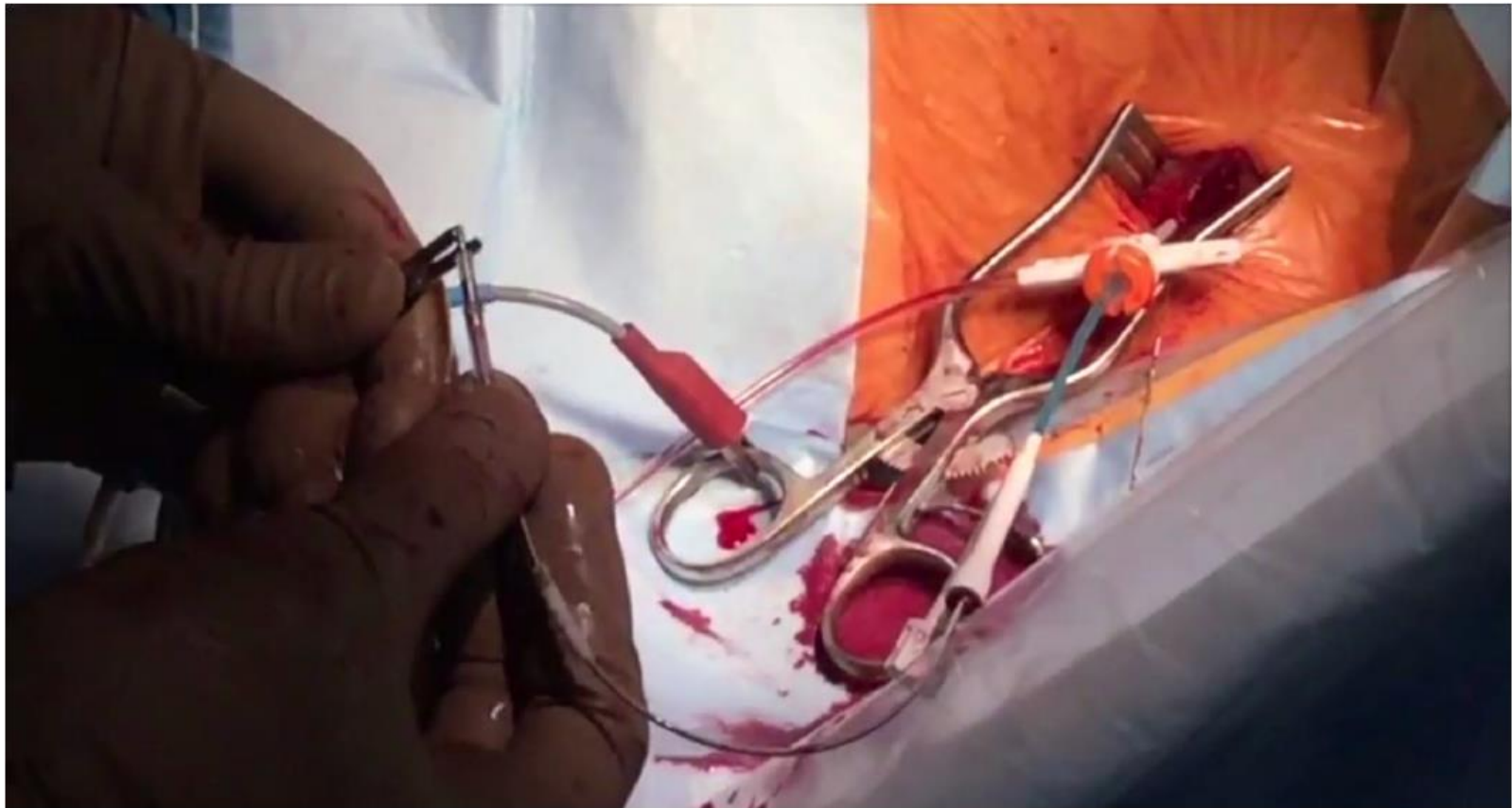
## SelectSecure 3830 vs Biotronik Solia S





# Procedure

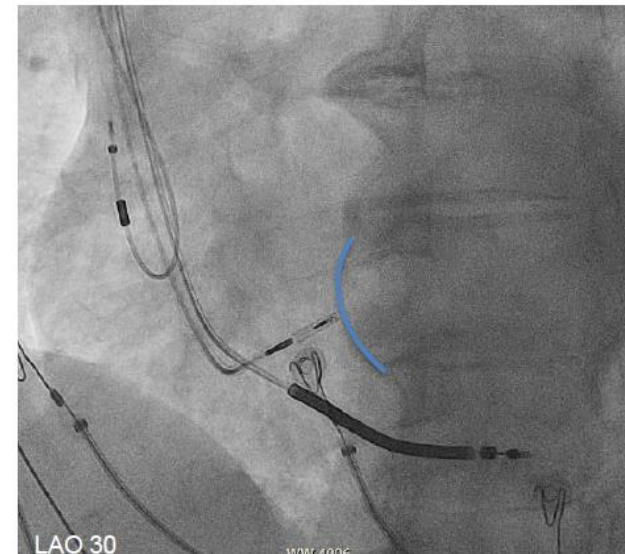
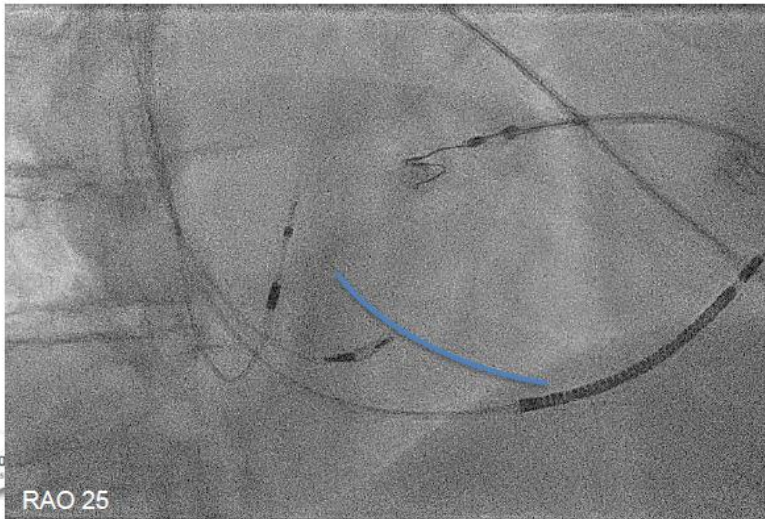
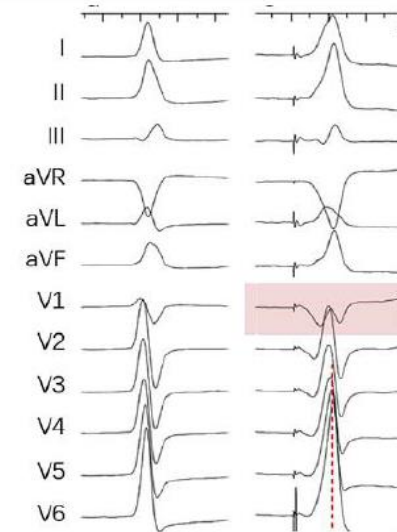
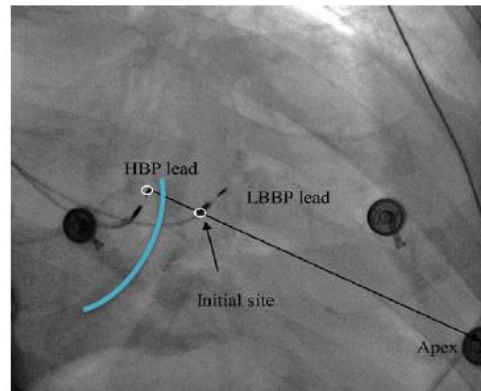
## Prepare for unipolar pace mapping



# Procedure

## How to determine site for lead implantation?

Pace mapping 5V unipolar:  
"W" morphology in V1.  
~2cm caudal from TV  
Stay away from RVOT !

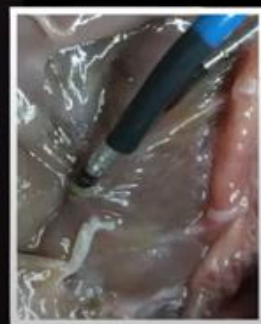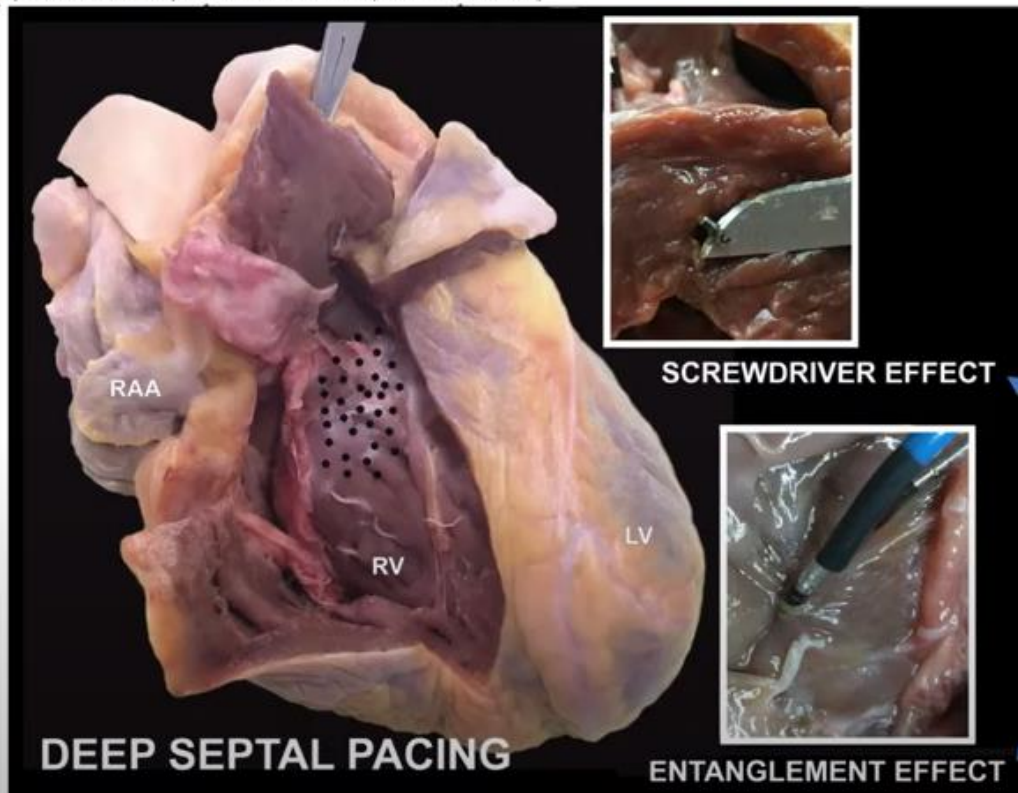


# Procedure

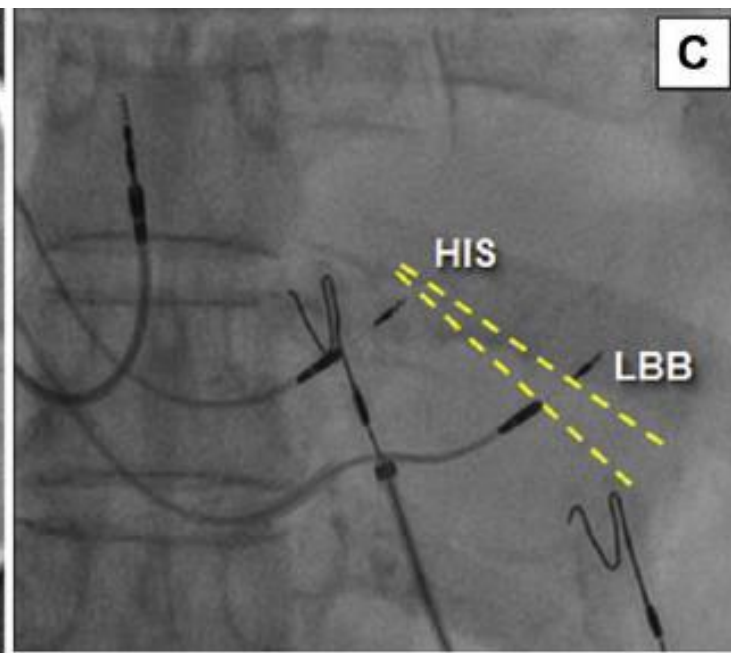
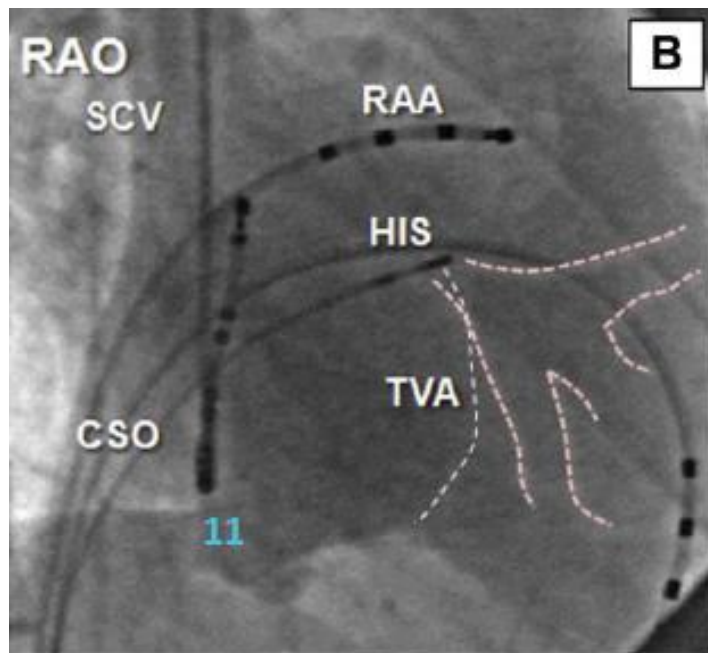
## Deep septal deployment of a thin, lumenless pacing lead: a translational cadaver simulation study

Marek Jastrzębski<sup>1\*</sup>, Paweł Moskal<sup>1</sup>, Mateusz K. Hołda<sup>2</sup>, Marcin Strona<sup>3</sup>,

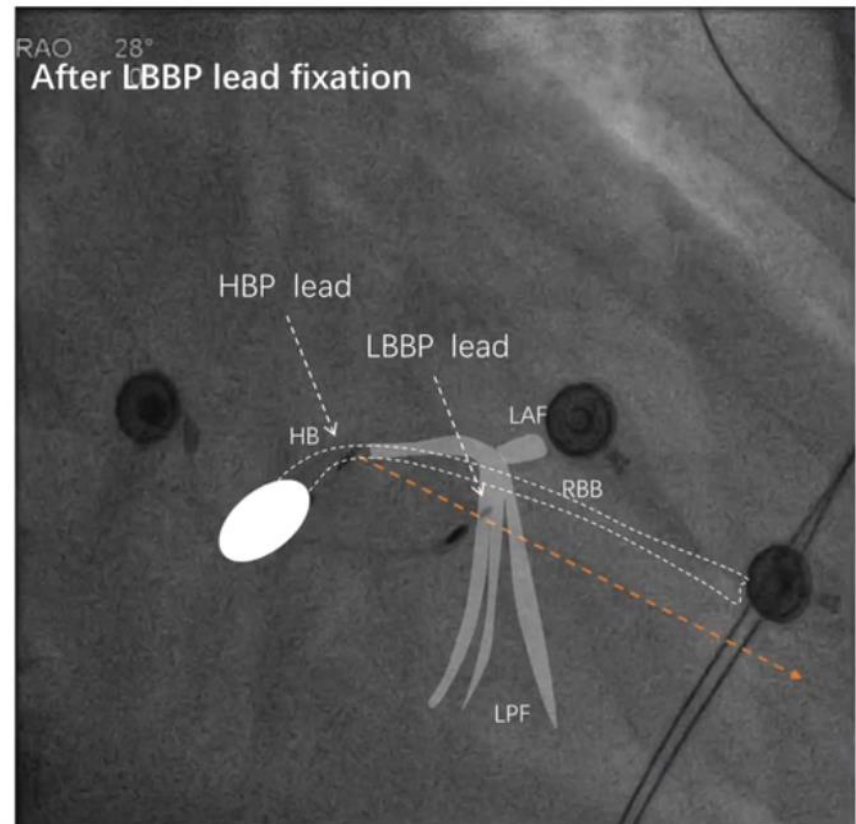
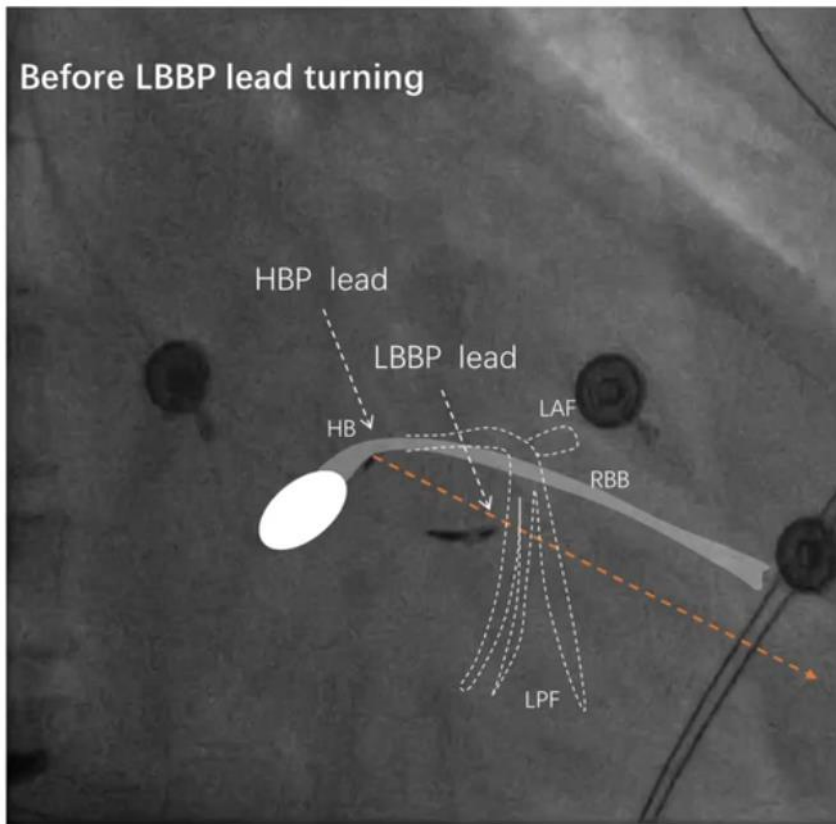
## Responses to screwing



# Procedure

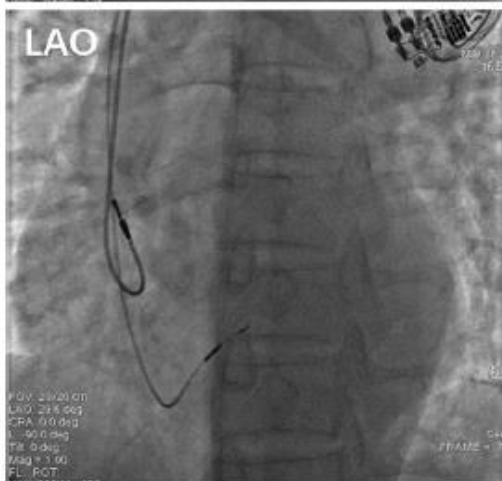
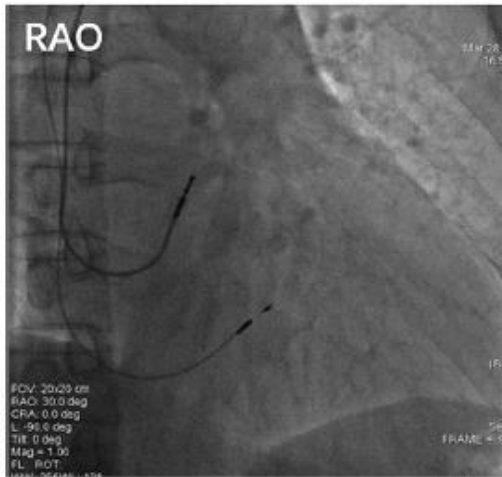


## Relationship between bundle branch and the pacing lead

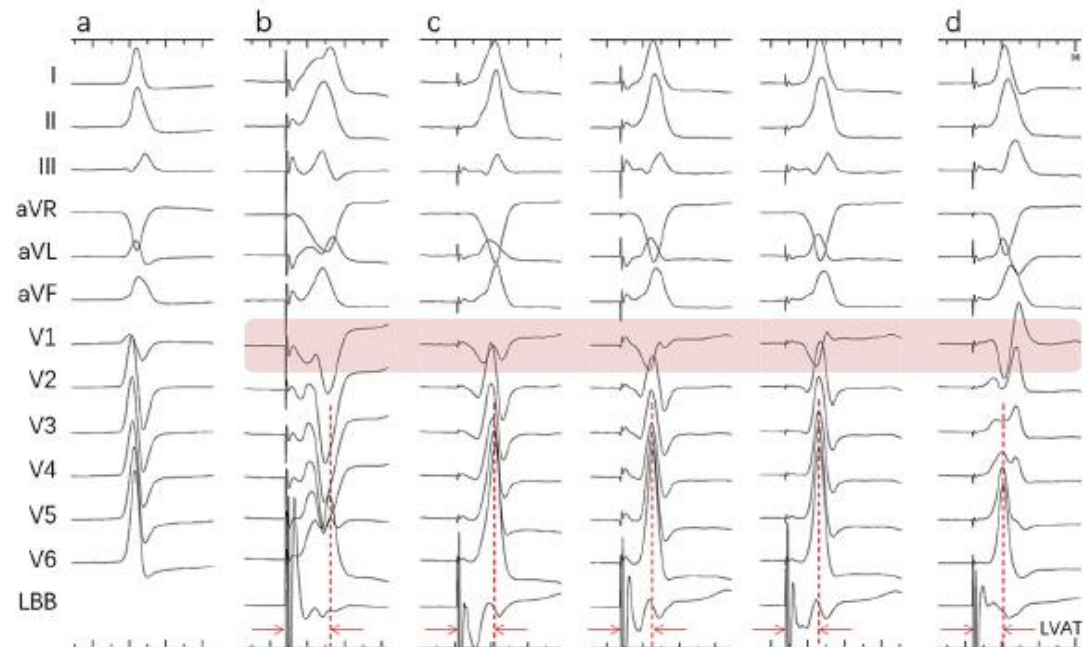


# Procedure

A



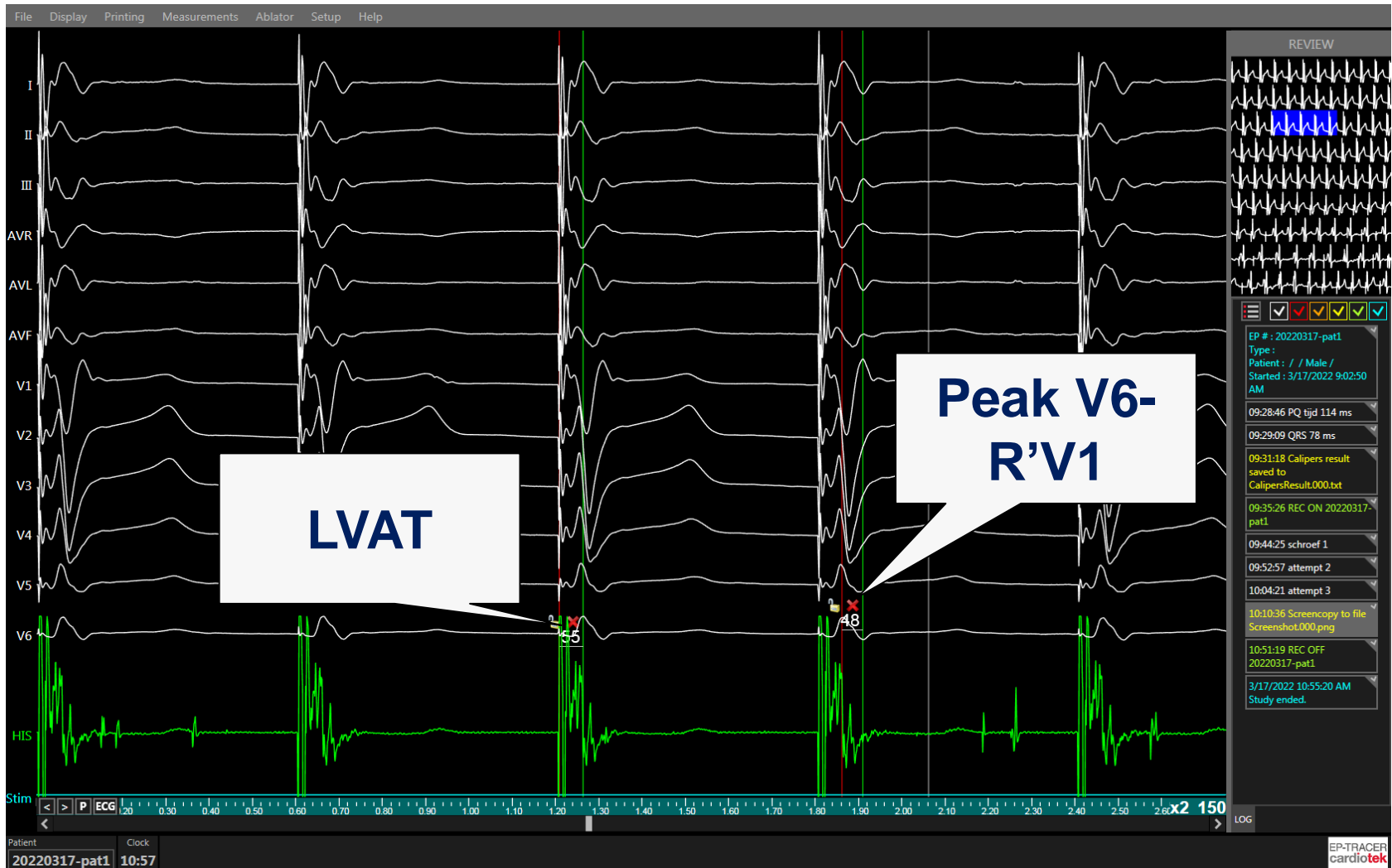
B



## Criteria voor LB pacing

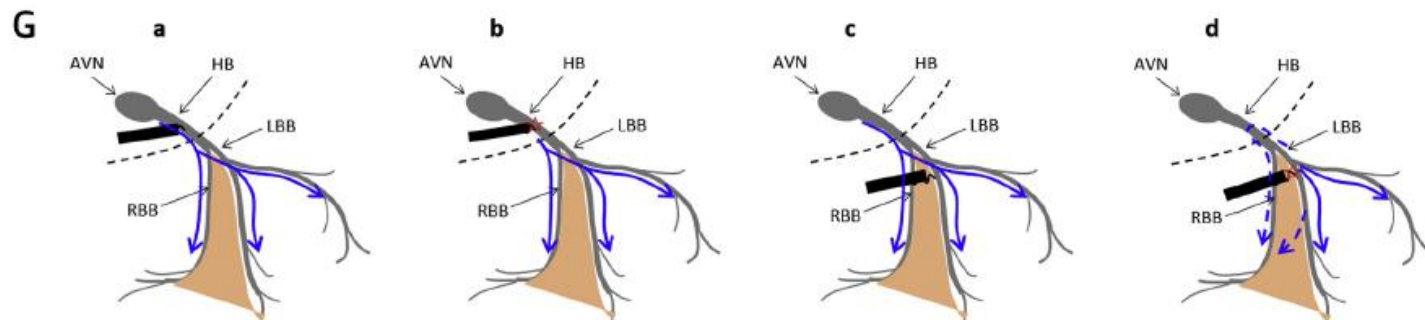
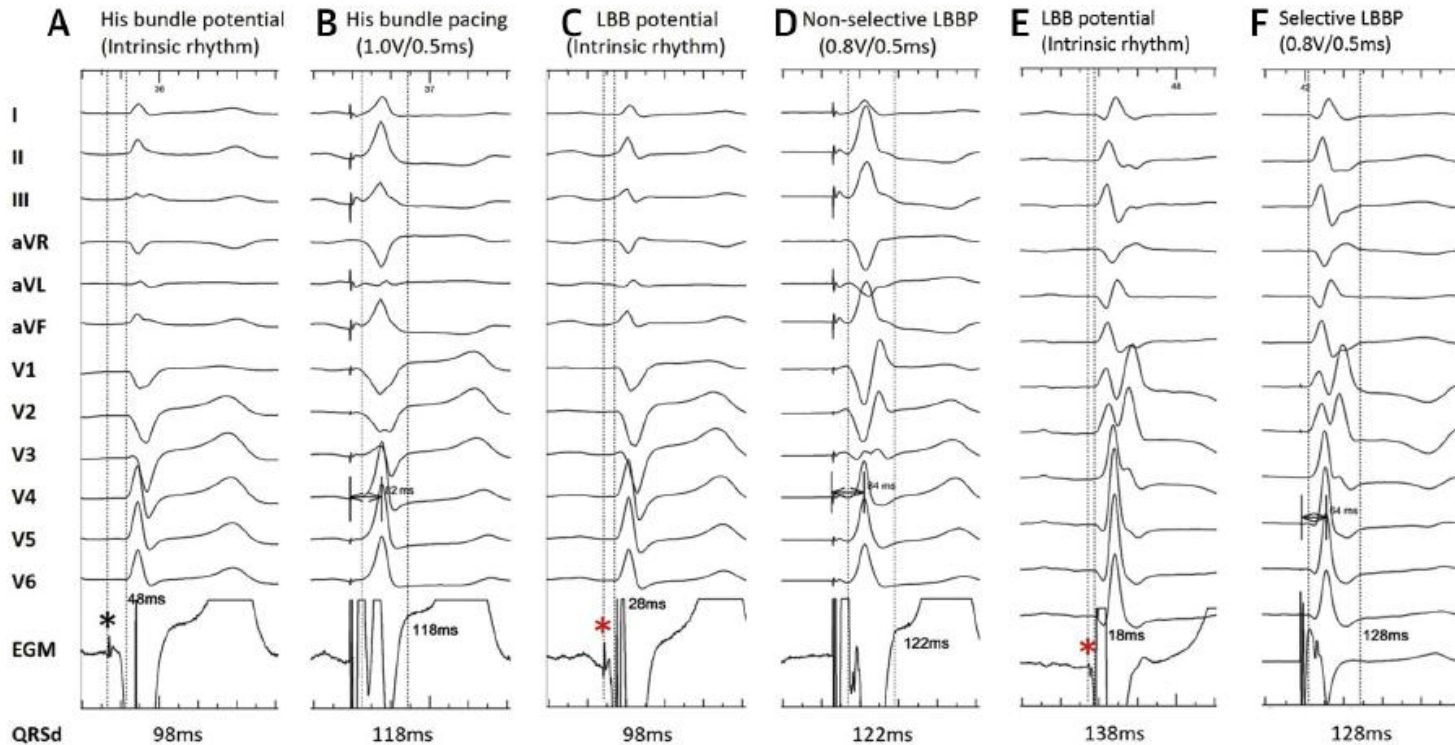
- **RBTB achtige configuratie**
- **LVAT < 70-80ms**
  - Pacing artefact → R V5-6
  - Cst bij hoge en lage output
  - Cave: in niet-CRT populatie
- **LB potential**
  - Alleen met EP-systeem zichtbaar
- **Peak V6 → r'V1 >40ms**

# Procedure

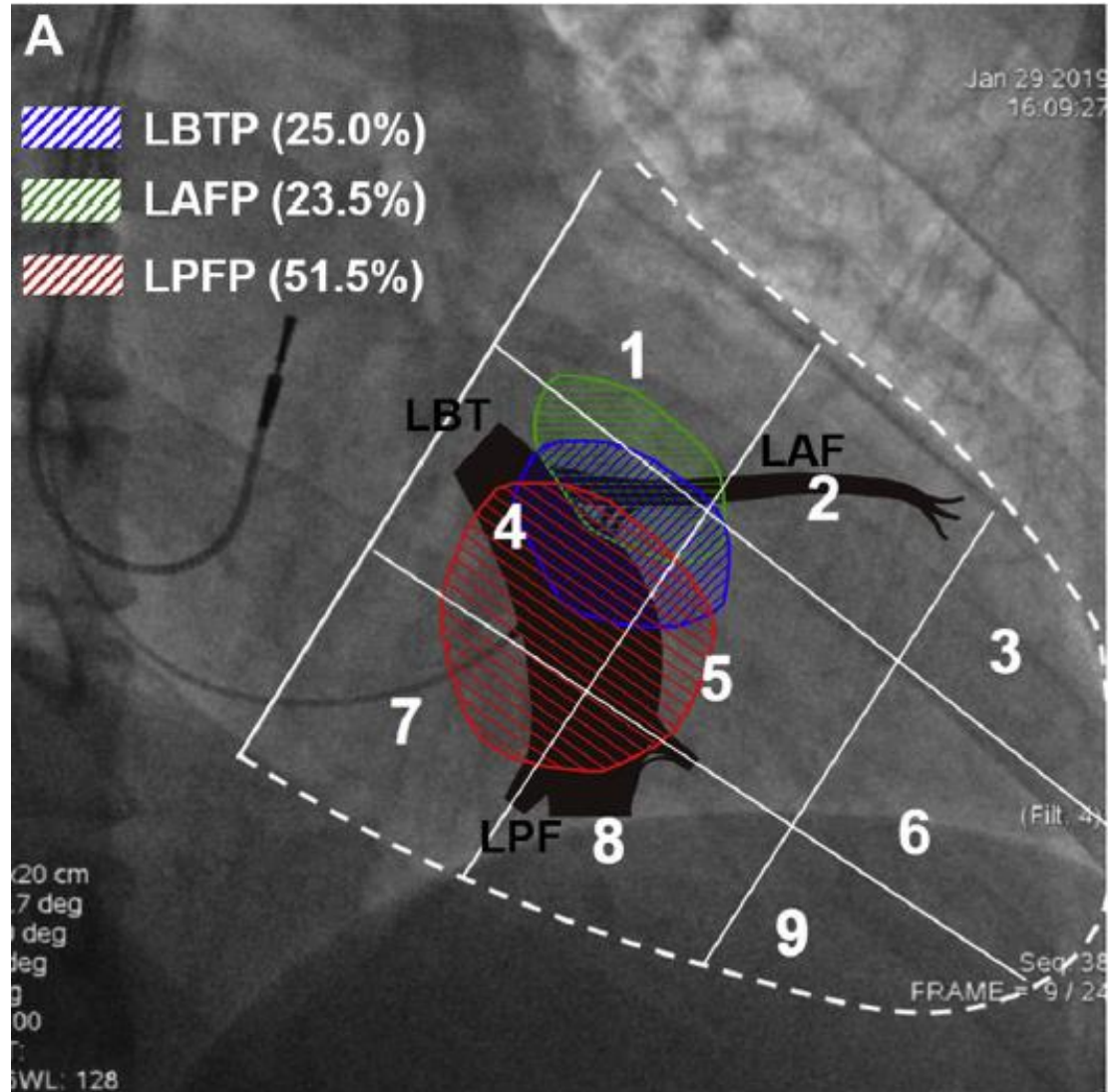




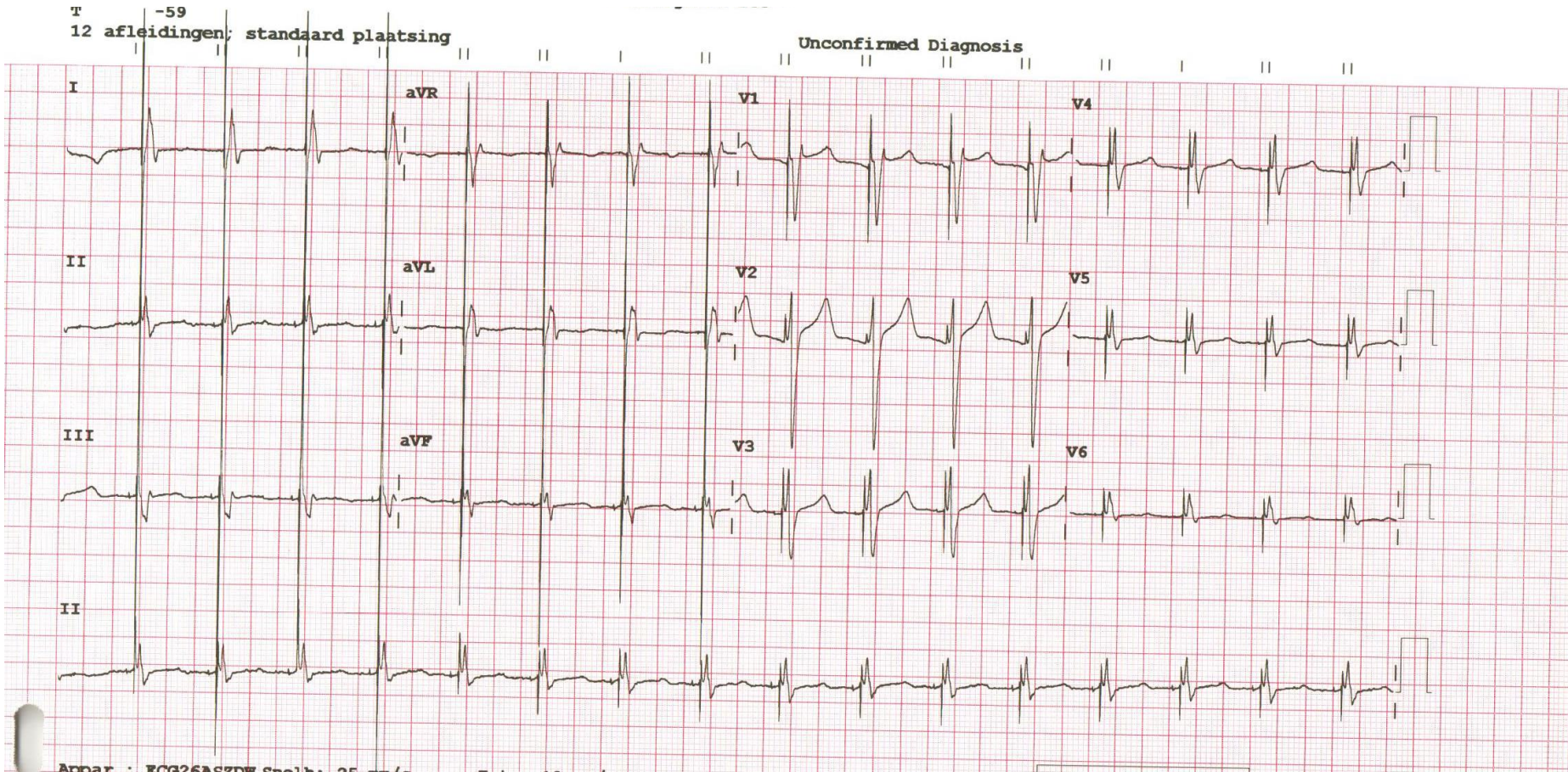
# ECG en LB pacing



# Procedure



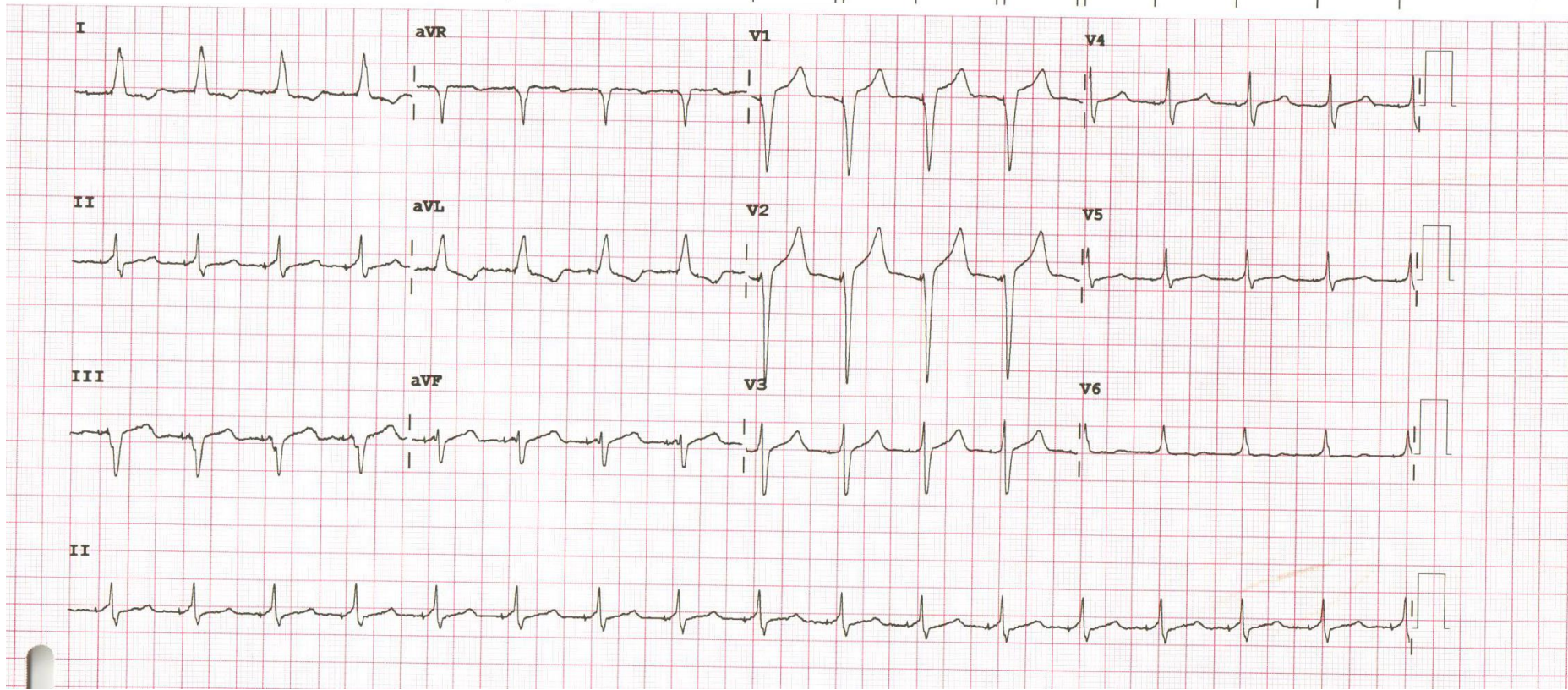
# LBB pacing: ECG post



# LBB pacing: ECG post

12 afleidingen; standaard plaatsing

Unconfirmed Diagnosis



# Resultaten

## MELOS — MULTICENTER EUROPEAN LEFT BUNDLE BRANCH AREA PACING OUTCOMES STUDY



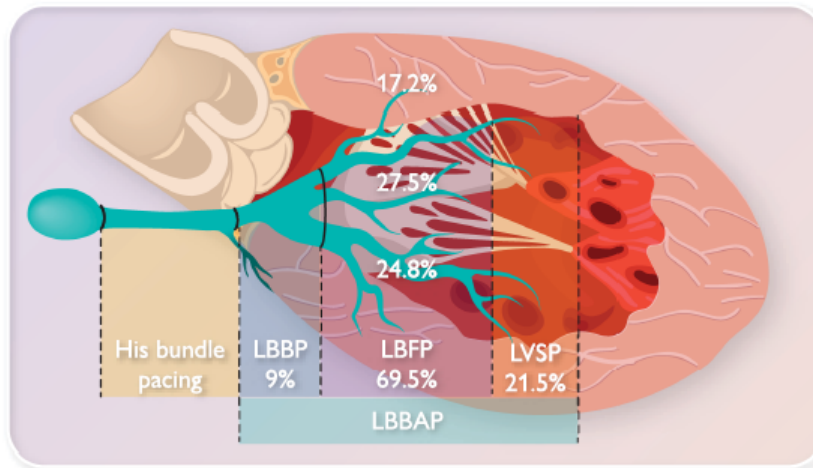
Prospective, multicenter,  
registry-based observational study



2533  
Participants



14  
European centres



### Independent predictors of LBBAP lead implantation failure

Heart failure indication	OR 1.49, 95% CI 1.01–2.21
Baseline QRS duration, per 10 ms	OR 1.08, 95% CI 1.03–1.14
LVEDD, per 10 mm increase	OR 1.53, 95% CI 1.26–1.86

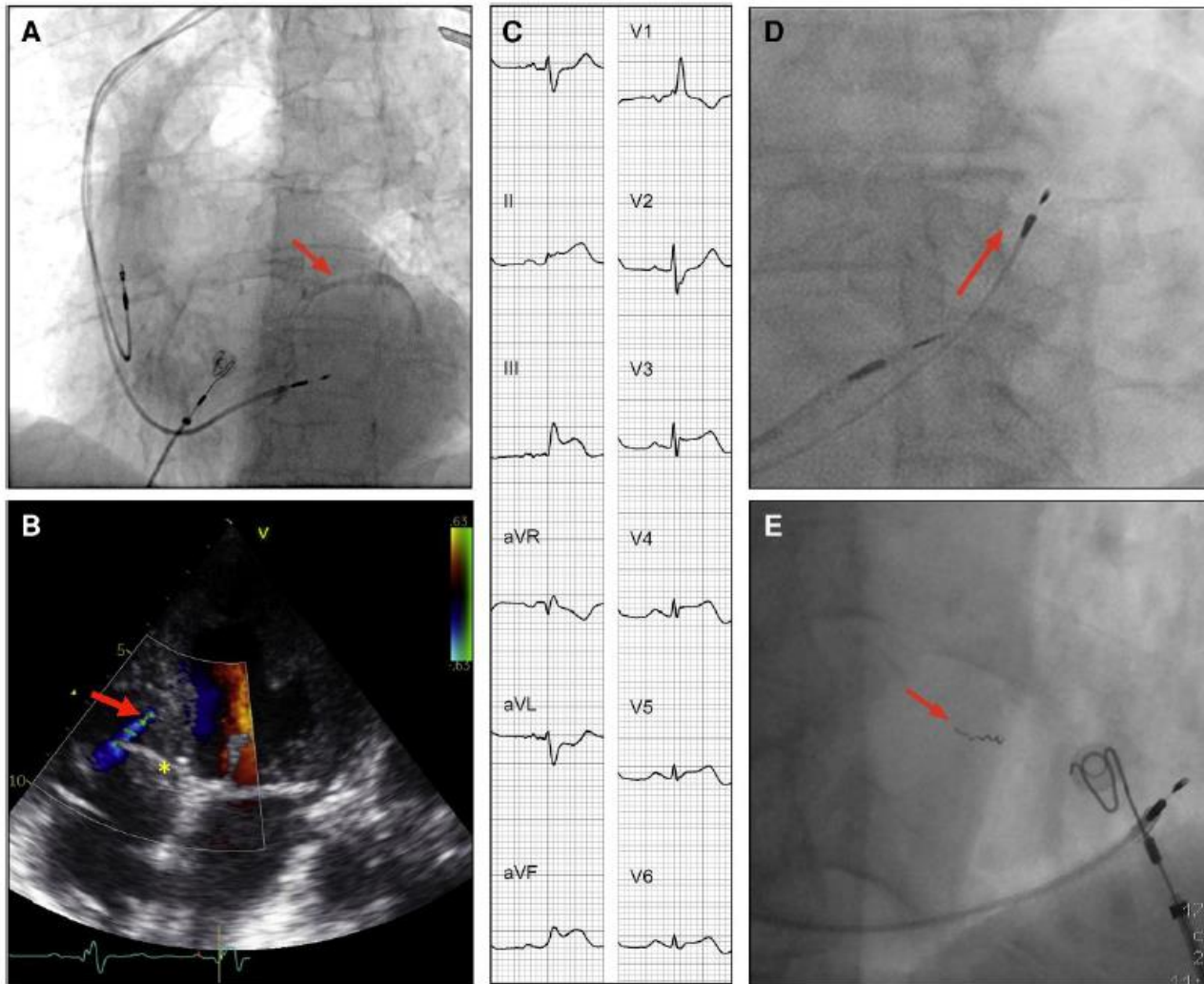
### LBBAP implantation success

Bradycardia indication success	92.4%
Heart failure indication success	82.2%

### LBBAP lead complications

• Acute perforation to LV	3.7%
• Lead dislodgement	1.5%
• Acute chest pain	1.0%
• Capture threshold rise	0.7%
• Acute coronary syndrome	0.4%
• Trapped/damaged helix	0.4%
• Delayed perforation to LV	0.1%
• Other	0.7%

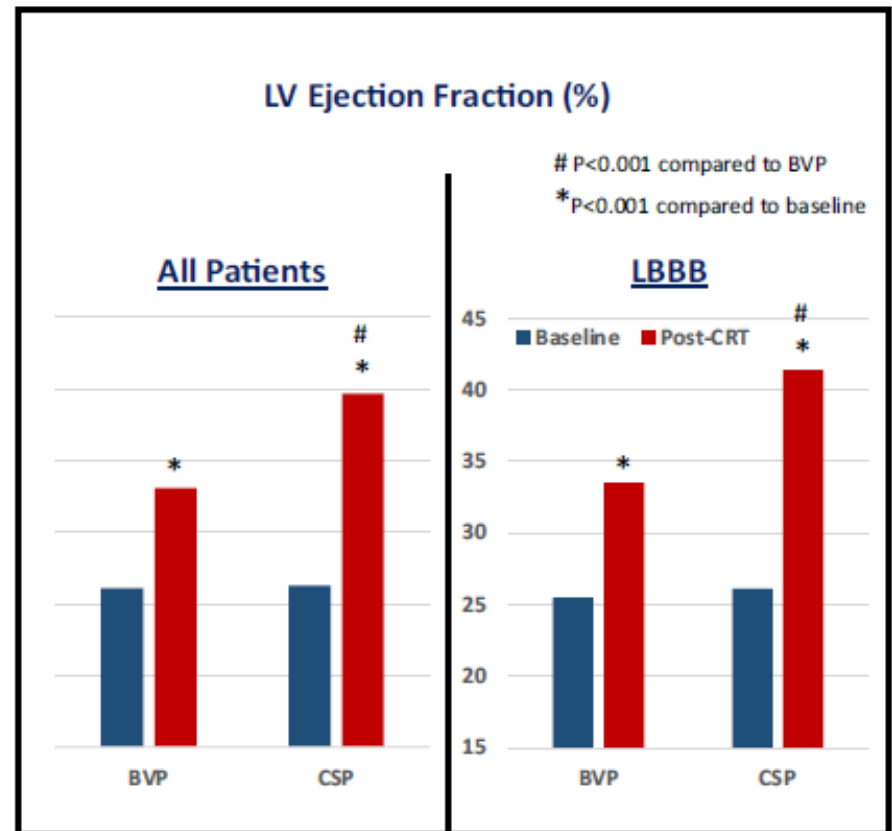
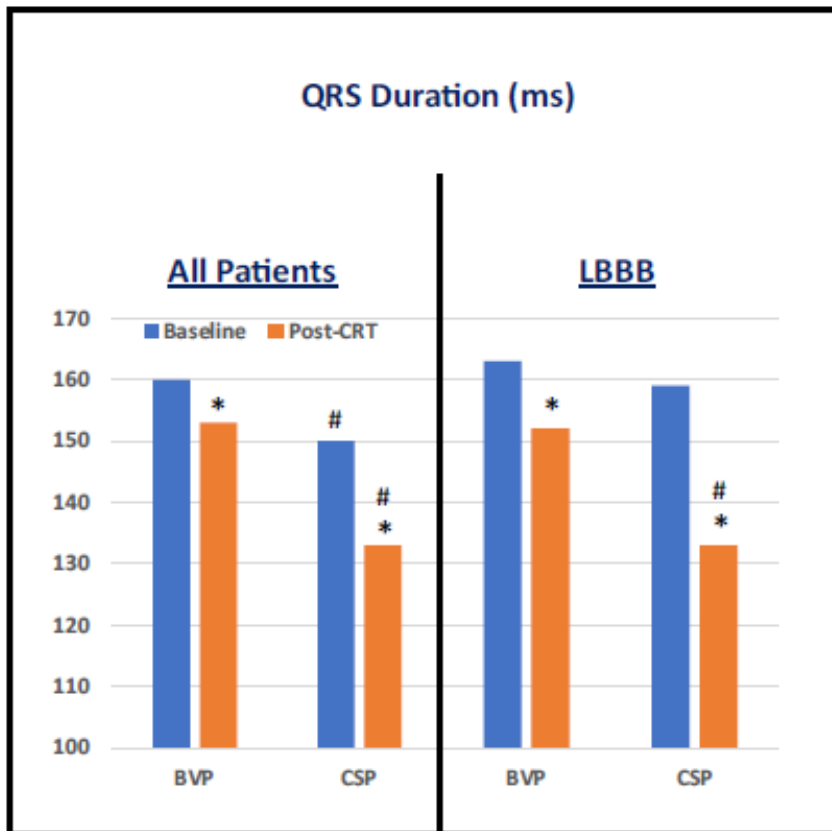
# Complicaties



# Vervanging van CRT?

- **CRT is toch prima?**
  - ✓ Harde evidence, veel gerandomiseerde studies
  - ✓ Zeer veel ervaring
  - ✓ Goede materialen
  
- **Nadelen van CRT**
  - ✓ Complexer (upgrades)
  - ✓ Variatie van veneuze anatomie
  - ✓ Epicardiale activatie
  - ✓ Langere procedures
  - ✓ Re-do ~ PNS, verlies van pacing, hoge drempels
  - ✓ Duurder
  - ✓ Meer stroomverbruik

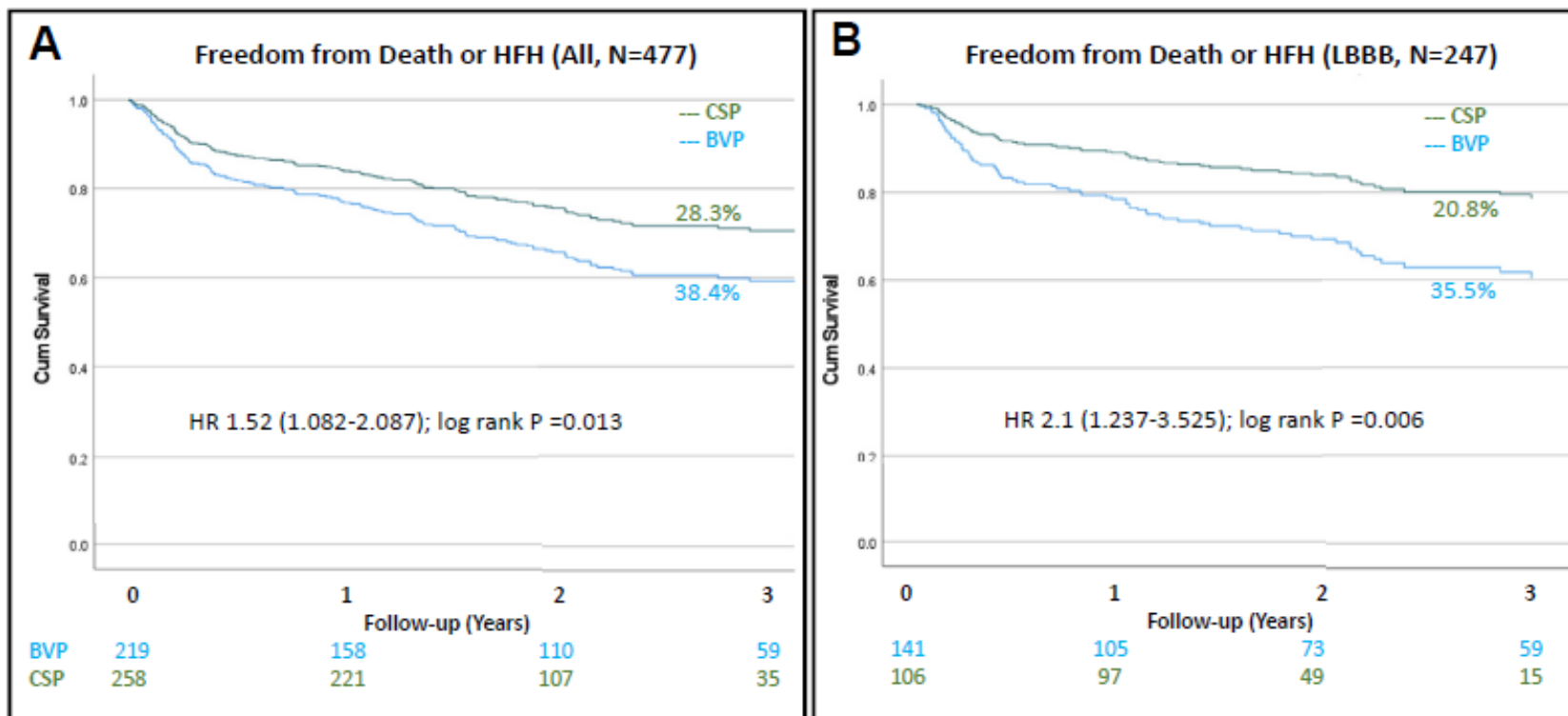
# Vervanging van CRT?





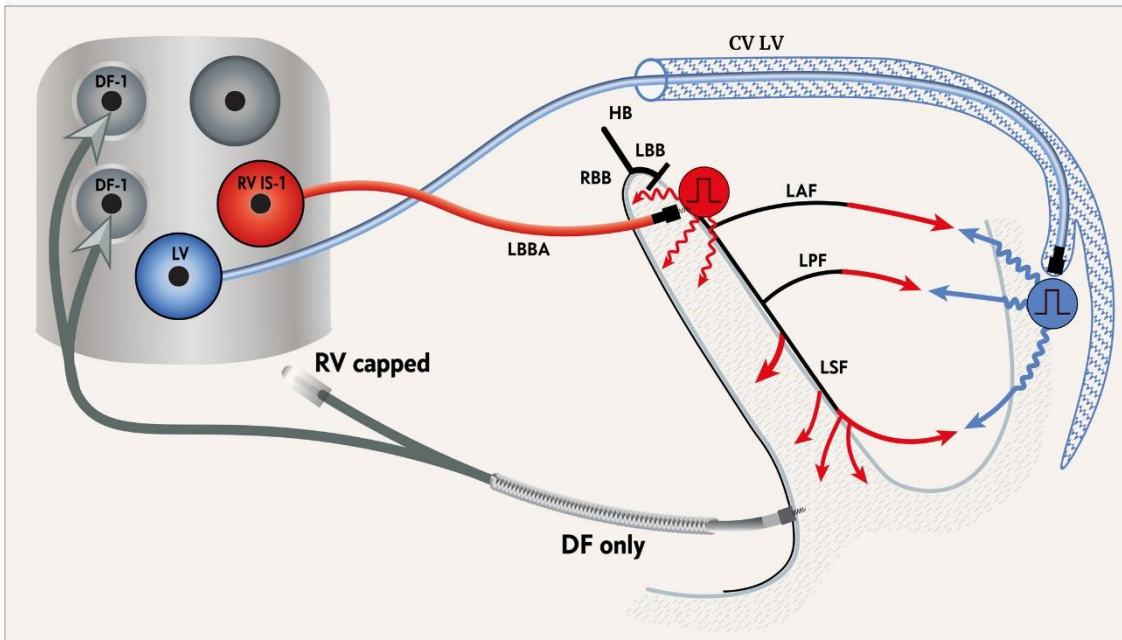
# Vervanging van CRT?

## Time to Death or Heart Failure Hospitalization

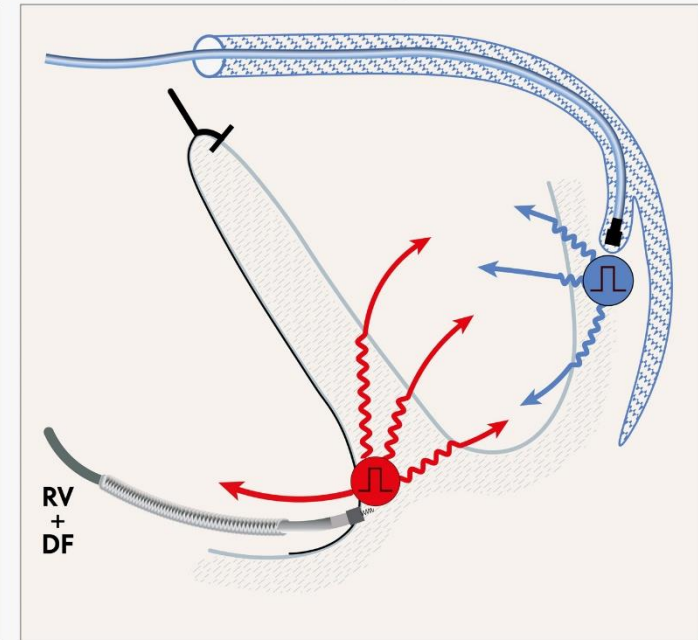


# Vervanging van CRT?

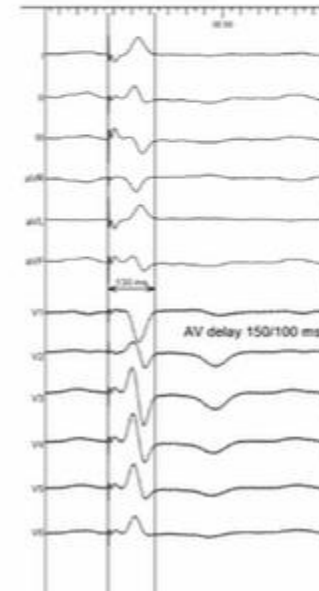

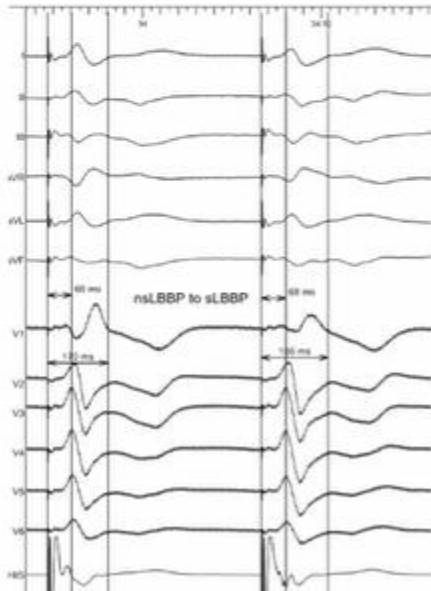
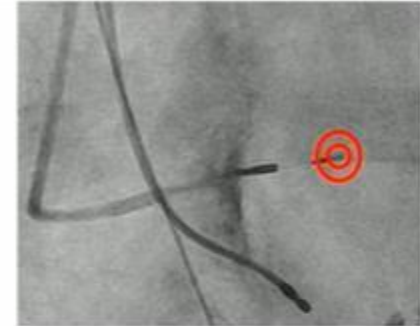
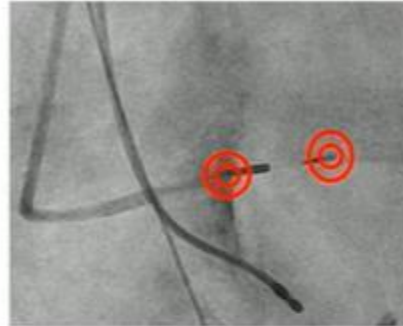
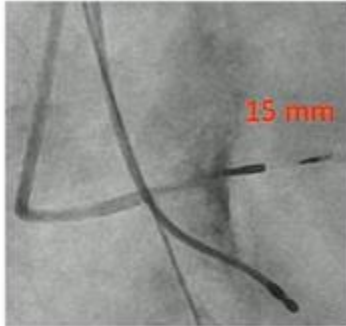
## LOT-CRT



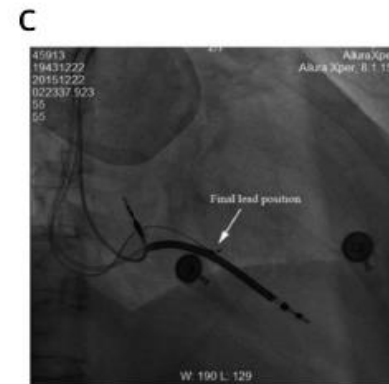
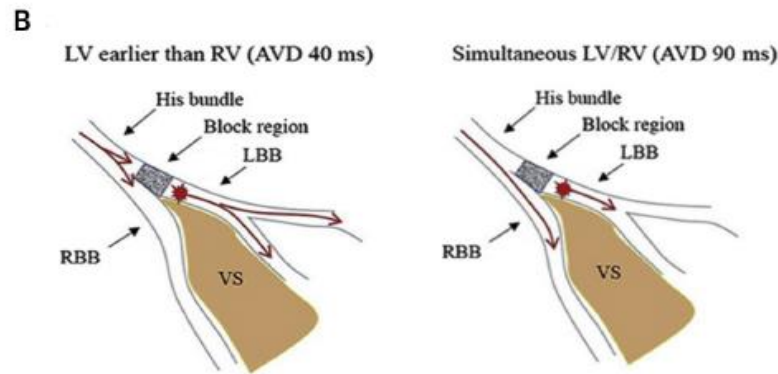
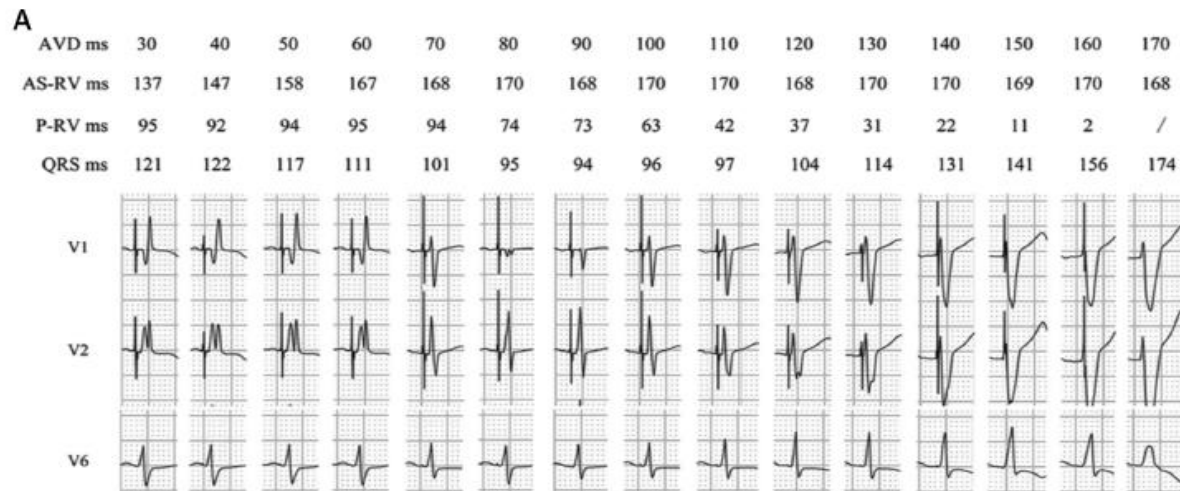
## BIV-CRT



# Instellen



**FIGURE 1** Electrocardiographic Characteristics and Potential Mechanism of LBBP in a Patient With Heart Failure



(A) The effect of sensed atrioventricular delay (AVD) on paced QRS duration and configuration. (B) The graphics illustrate potential conduction with pacing the left bundle branch at AVDs of 40 and 90 ms, respectively. (C) The fluoroscopic image shows the final lead position in the right anterior oblique view. Adapted with permission from Huang et al. (23). AS-RV = right atrial sensing to right ventricular signal; LBB = left bundle branch; LBBP = left bundle branch pacing; LV = left ventricle; P-RV = pacing to right ventricular interval; RBB = right bundle branch; RV = right ventricle; VS = ventricular septum.

- **Veelbelovend**
- **GEEN lange-termijn resultaten**
- **Blijft lead goed? Kan een extractie?**
- **RCT's nodig!**
- **Hype? Veel enthousiasme; 'boot niet missen'**
- **Weegt het op tegen relatief klein aandeel upgrades?**
- **Kosten**
- **Wanneer tevreden? Criteria nodig**
- **LV septum pacing voldoende?**
- **Hoe instellen?**
- **CRT heeft harde evidence**
- **Materiaal voor HF populatie**
  
- **Voorlopig**
  - **Bailout voor CRT**
  - **Pacing bij LVF↓ + hoog % pacing?**

## 58-Jarige patiënte – Non-ischemisch hartfalen

### Voorgeschiedenis

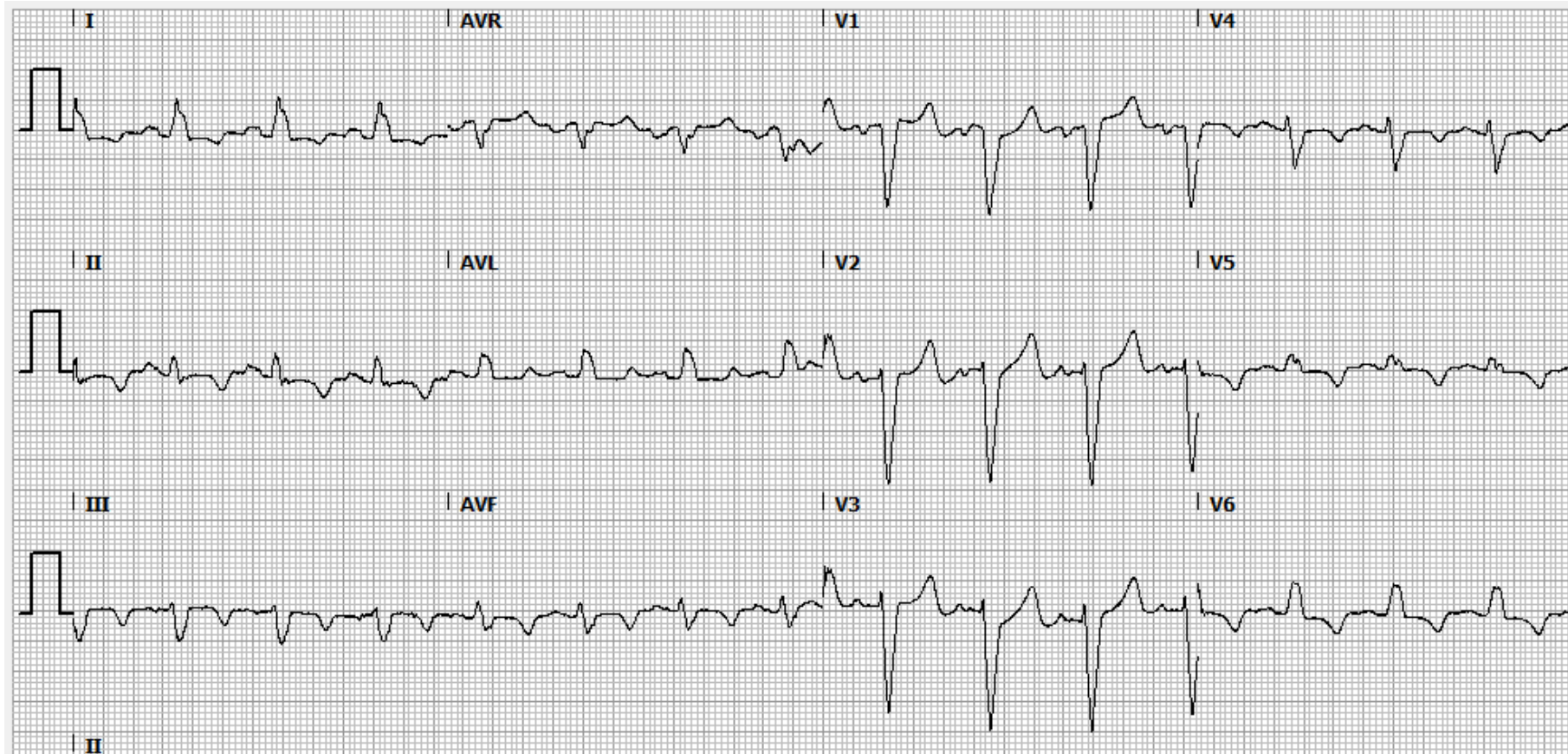
2010: CAG: gave coronairen.

2010: Mitralisklepplastiek en ringimplantatie in verband met ernstige mitralisklepinsufficiëntie

2013: Matige linkerventrikelfunctie, geen mitralisklepinsufficiëntie

2015: Biventriculaire-ICD implantatie. NYHA II, slechte linkerventrikelfunctie bij niet-ischaemisch hartlijden, LBTBM, QRS 140ms (PNS op CS1).

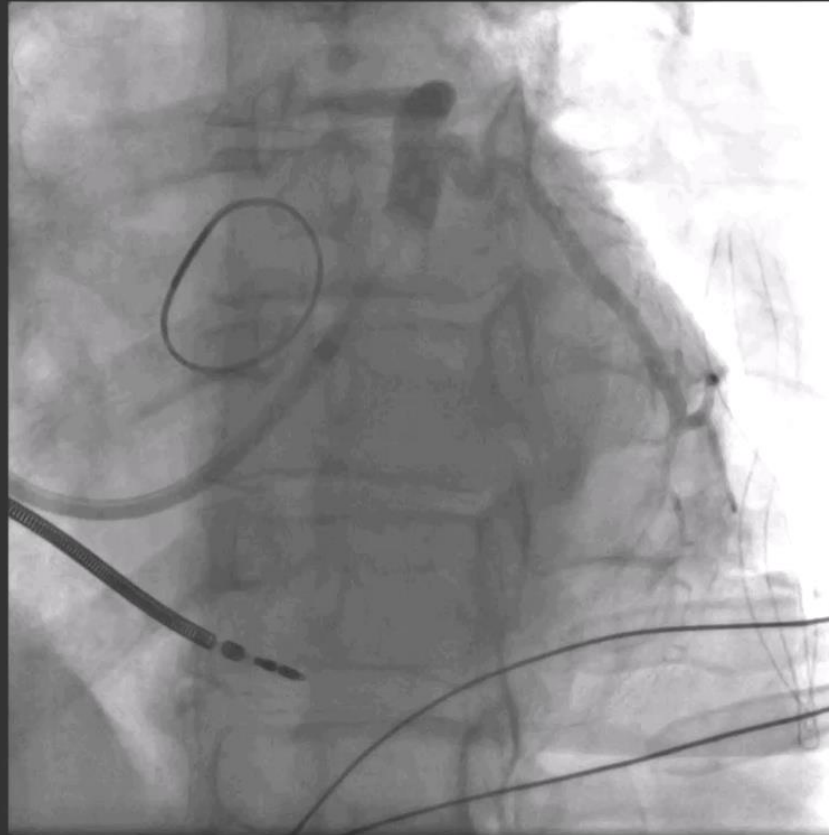
# Casus



# Casus

Leeftijd 52 jaar  
3. Coro ND ▾

C: 1700,0, W: 2500,0  
🔄 # 📄



## Vergelijkingen: 2 (2)

HCK01  
LAO / RAO: 29  
CAUD / CRAN: 0,1  
REF

31-8-2015, 10:29:42 ▾

F

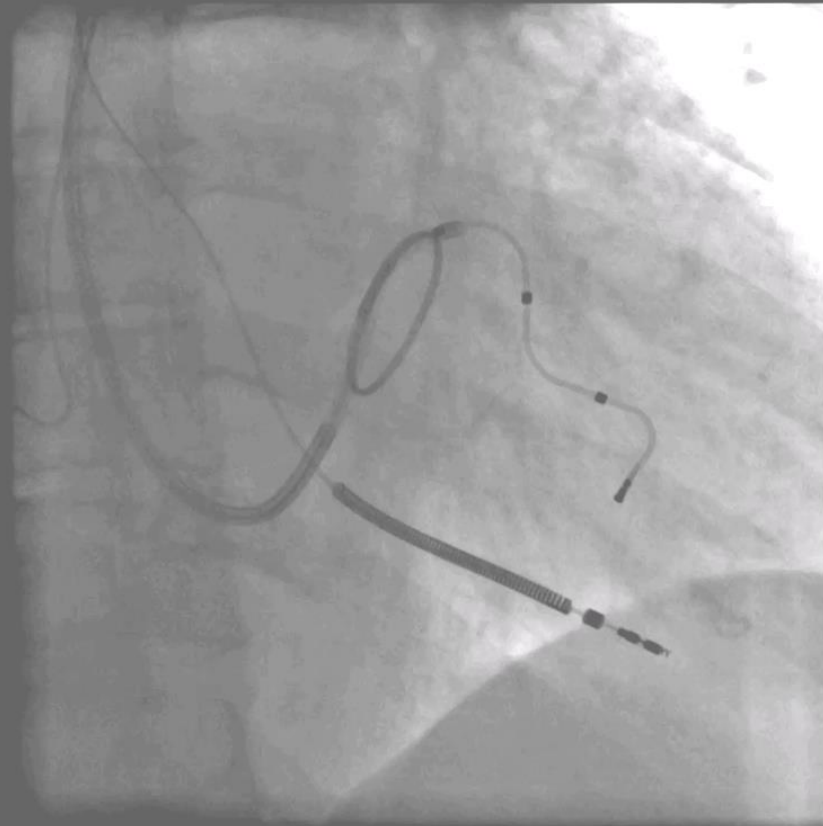


# Casus

Leeftijd 52 jaar

5. Coro ND ▾

C: 1700,0, W: 2500,0



## Vergelijkingen: 2 (2)

HCK01

LAO / RAO: -27,9

CAUD / CRAN: 0

31-8-2015, 10:38:59 ▾

F

# Casus

Leeftijd 58 jaar

4. Right Coronary 15 fps Medium ▾

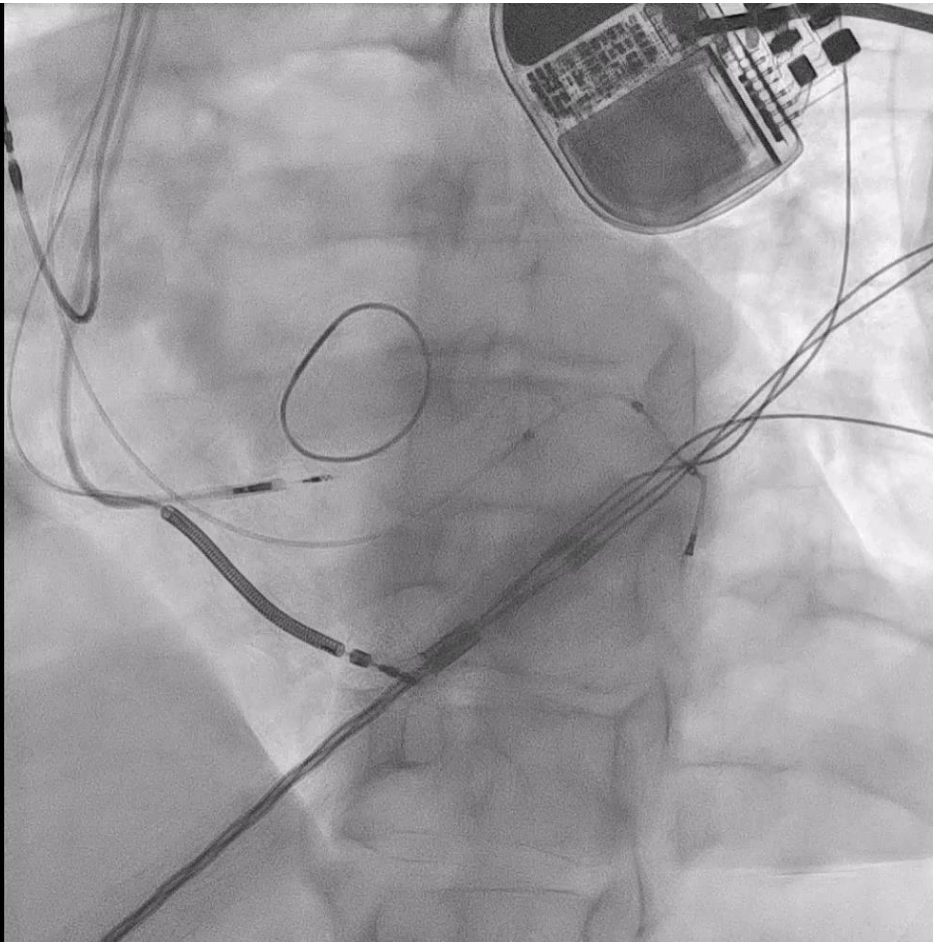
**Vergelijkingen: 1 (1)**

CAR\_KAMER1

LAO / RAO: 30,120000839233

CAUD / CRAN: 3,210000038147

26-5-2021, 15:58:37 ▾



C: 2048,0, W: 4096,0

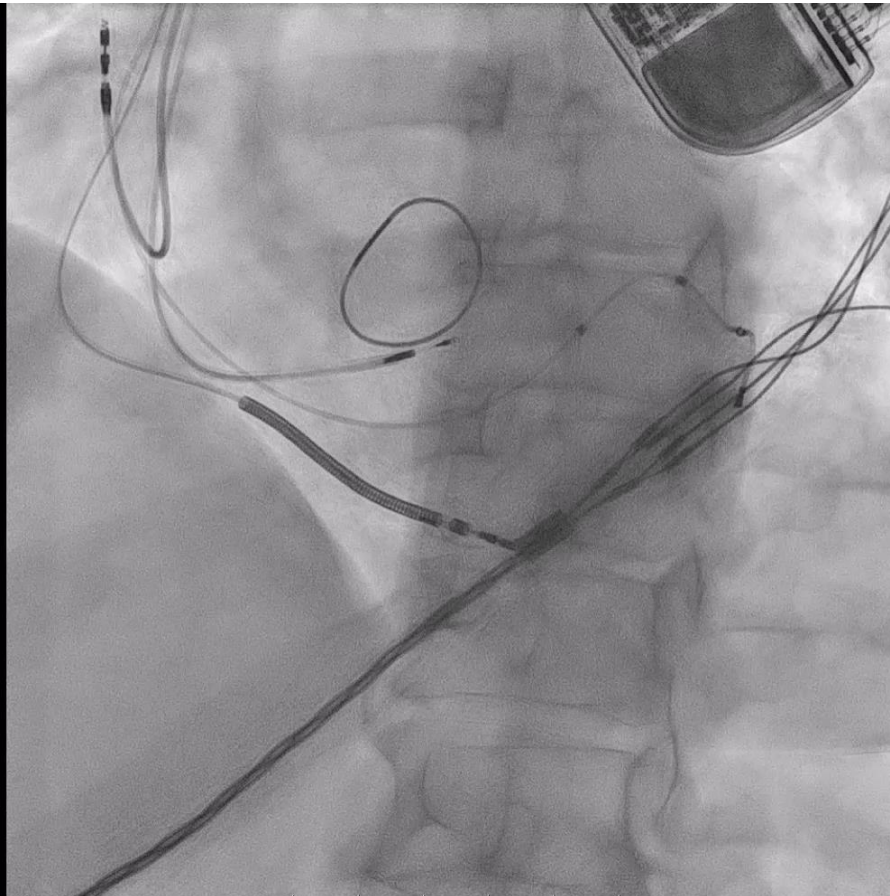


# Casus

Leeftijd 58 jaar

5. Right Coronary 15 fps Medium ▾

C: 2048,0, W: 4096,0



**Vergelijkingen: 1 (1)**

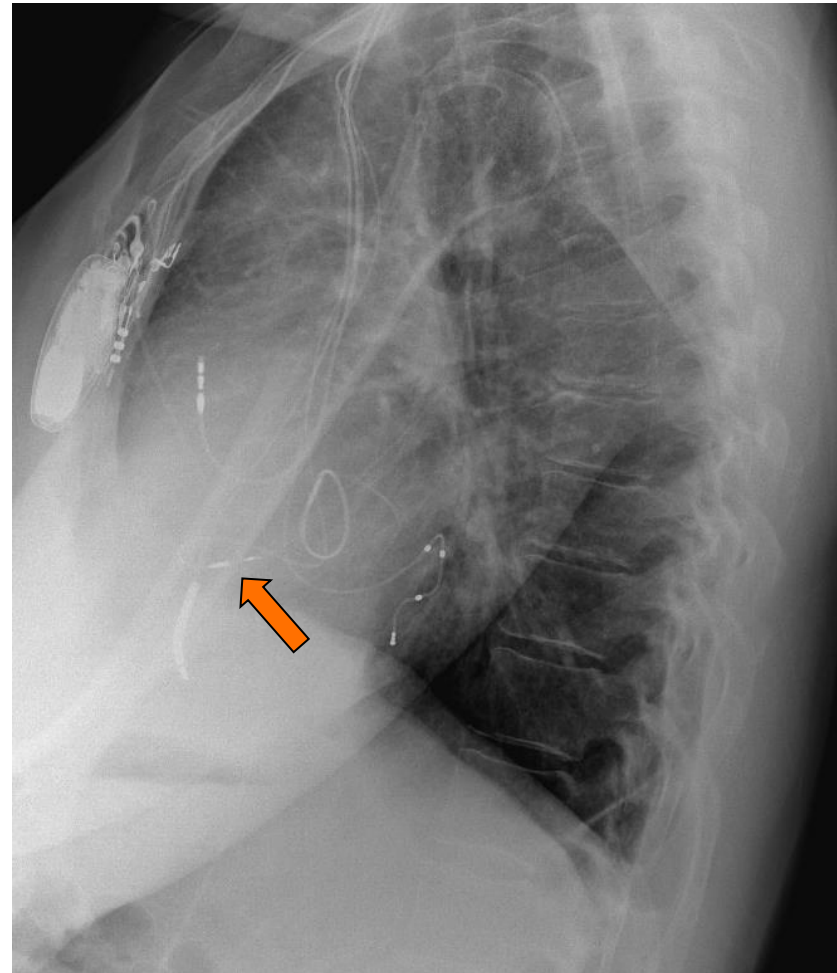
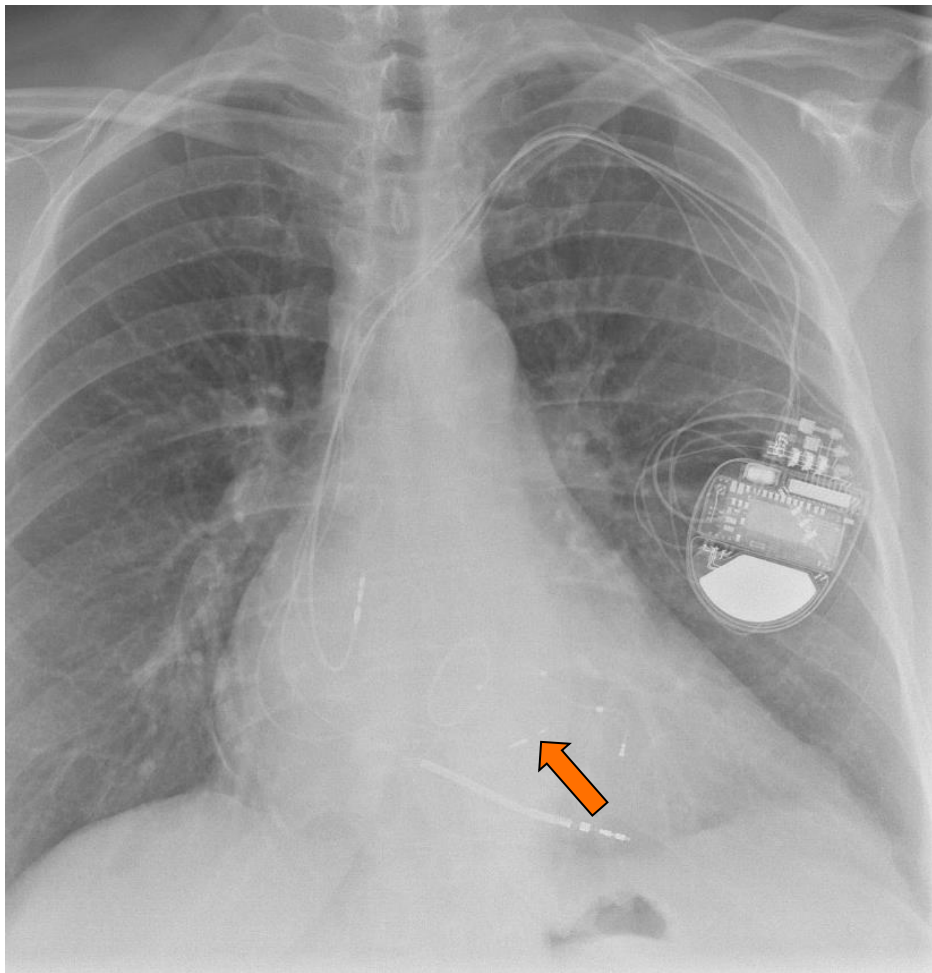
CAR\_KAMER1

LAO / RAO: 26,819999694824

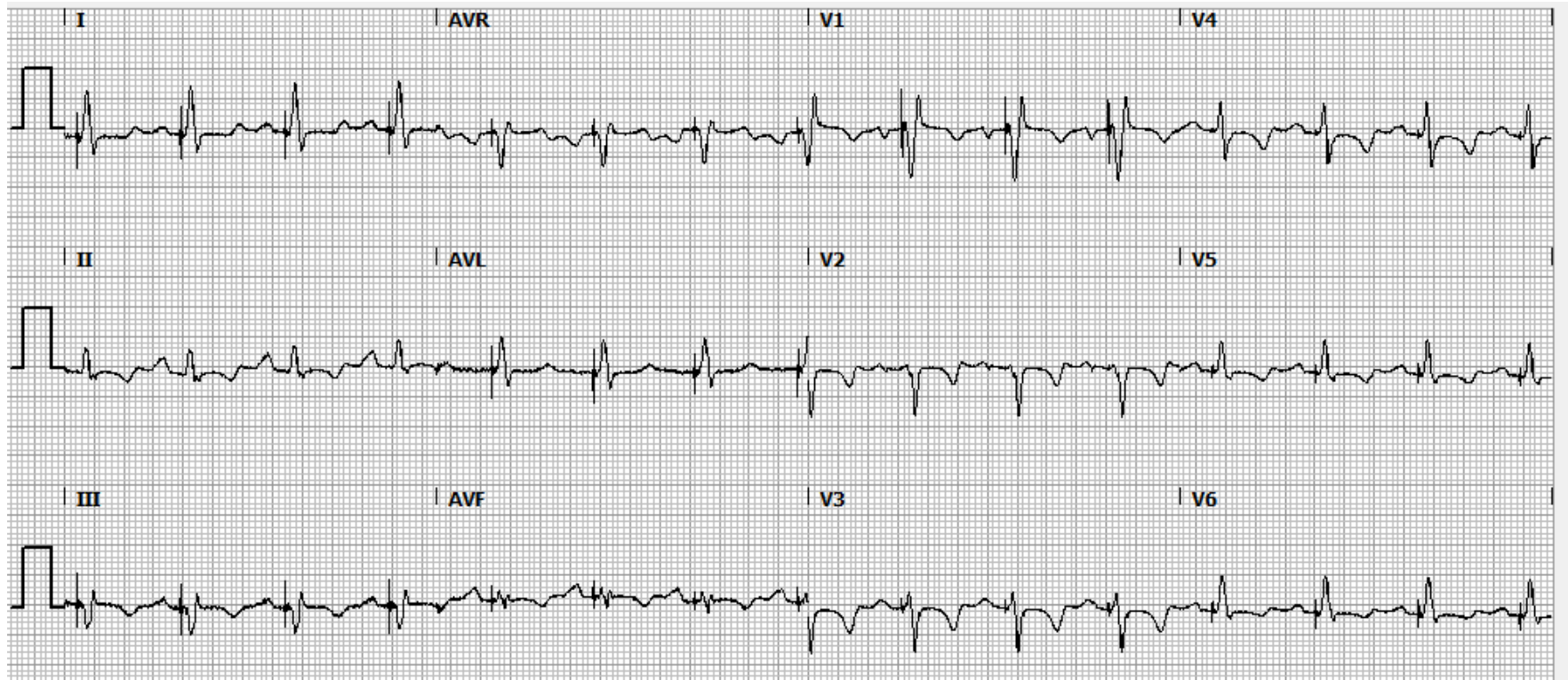
CAUD / CRAN: 3,210000038147

26-5-2021, 16:01:13 ▾

# Casus



# Casus



# Dank voor uw aandacht

