

Erasmus MC
University Medical Center Rotterdam

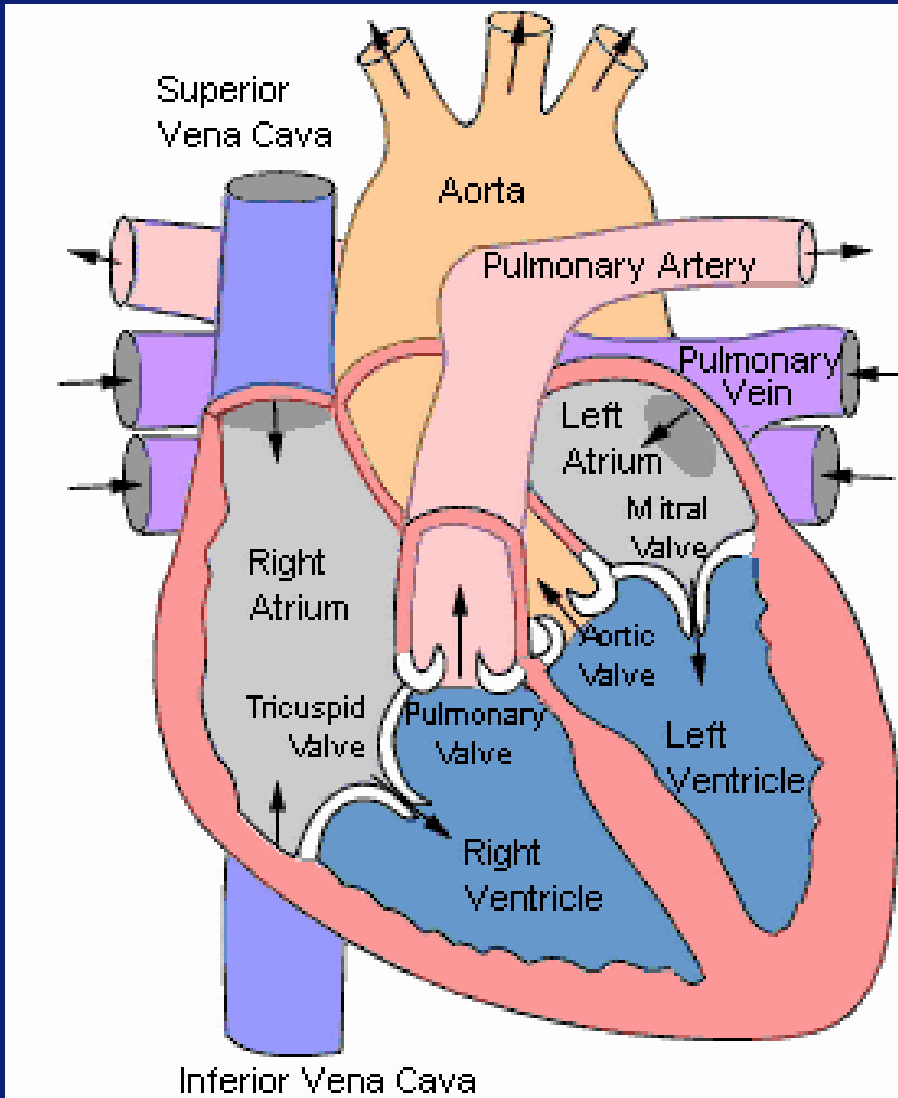


PREPAREREN VARKENSHART

Jan van Weezel

Pieter van de Woestijne

Anatomie Schematisch



Veneuze toevoer

Vena cava superior

Vena cava inferior

Longcirculatie

Rechter ventrikel

Arteria pulmonalis

Vena pulmonalis

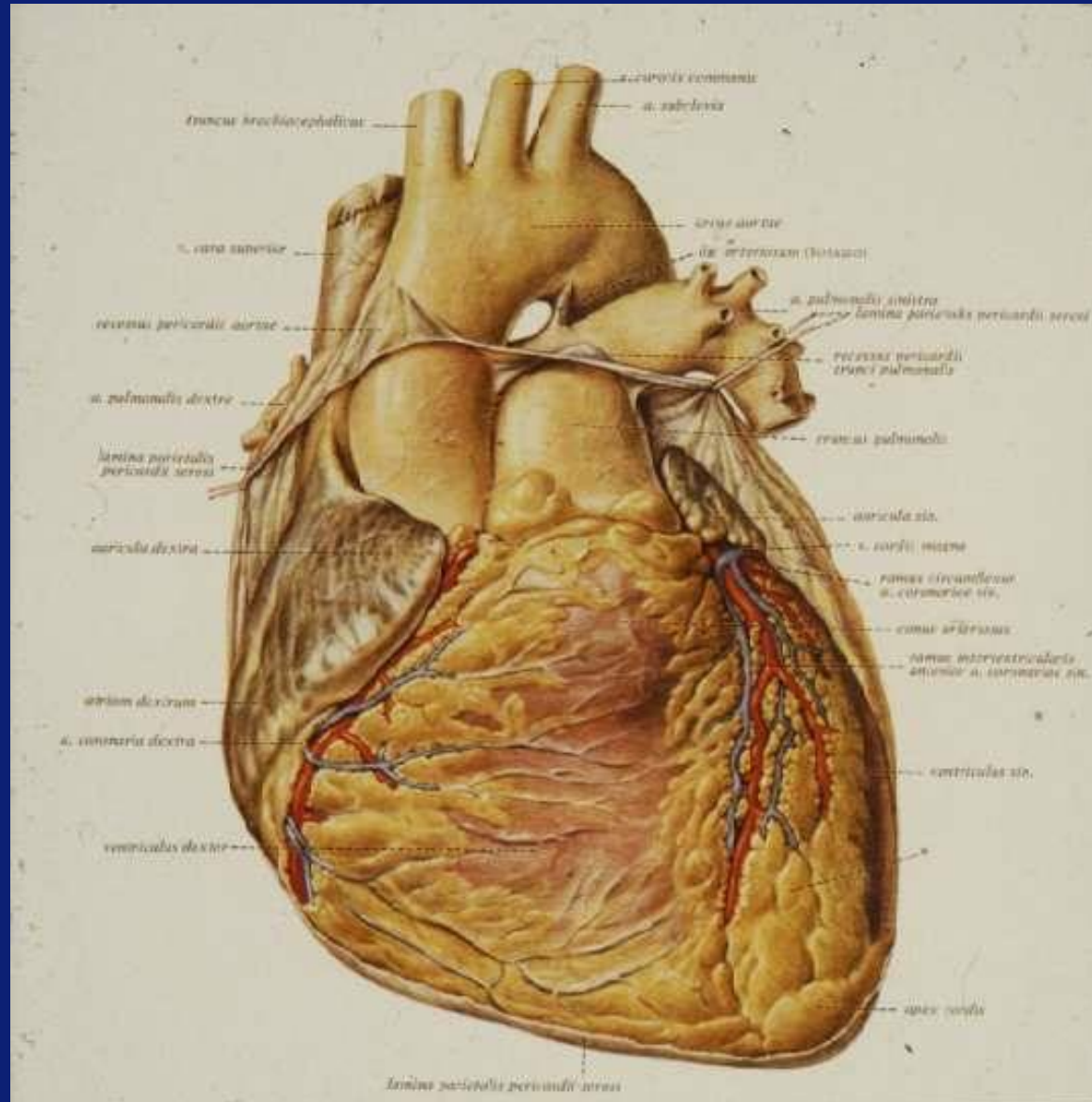
Linker ventrikel

Aorta

Coronairen

Halsvaten

Anatomie illustratie



Coronair arteriën

Coronair ostium

Linker coronair arterie

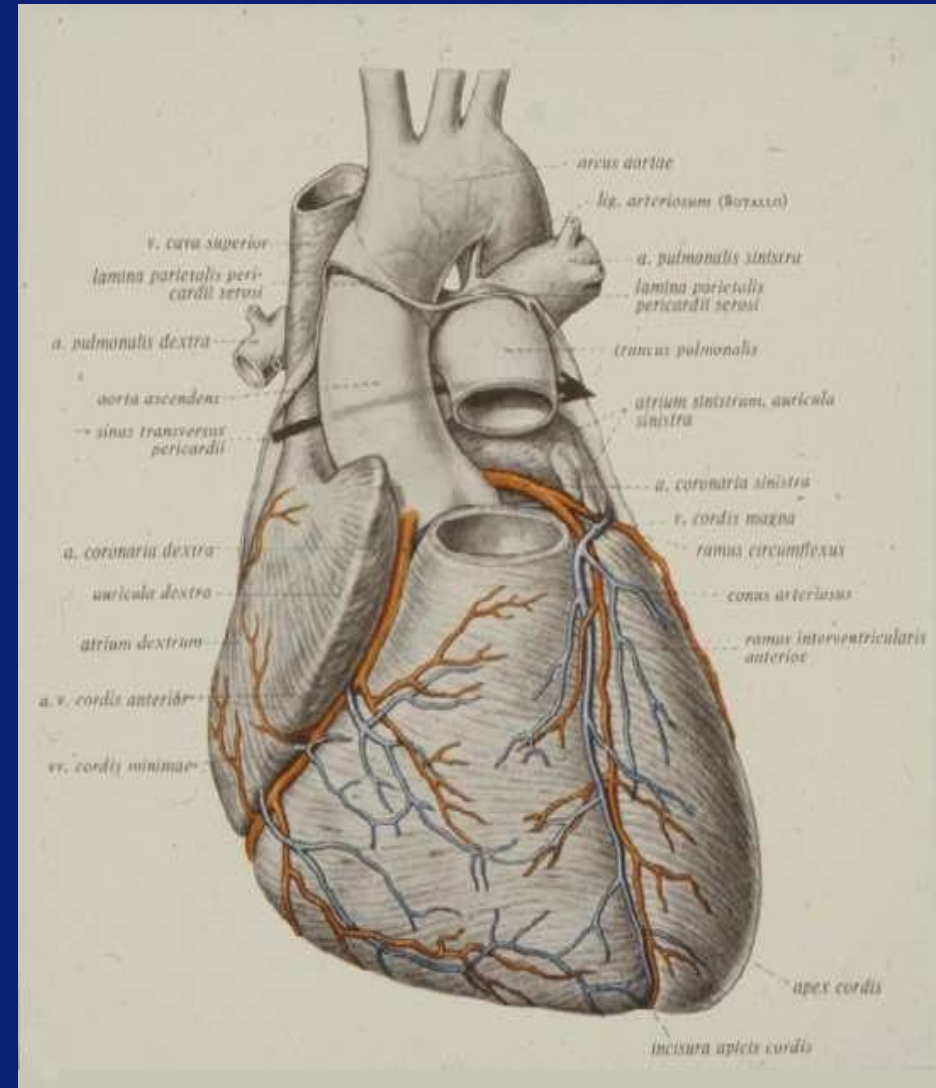
Hoofdstam

LAD

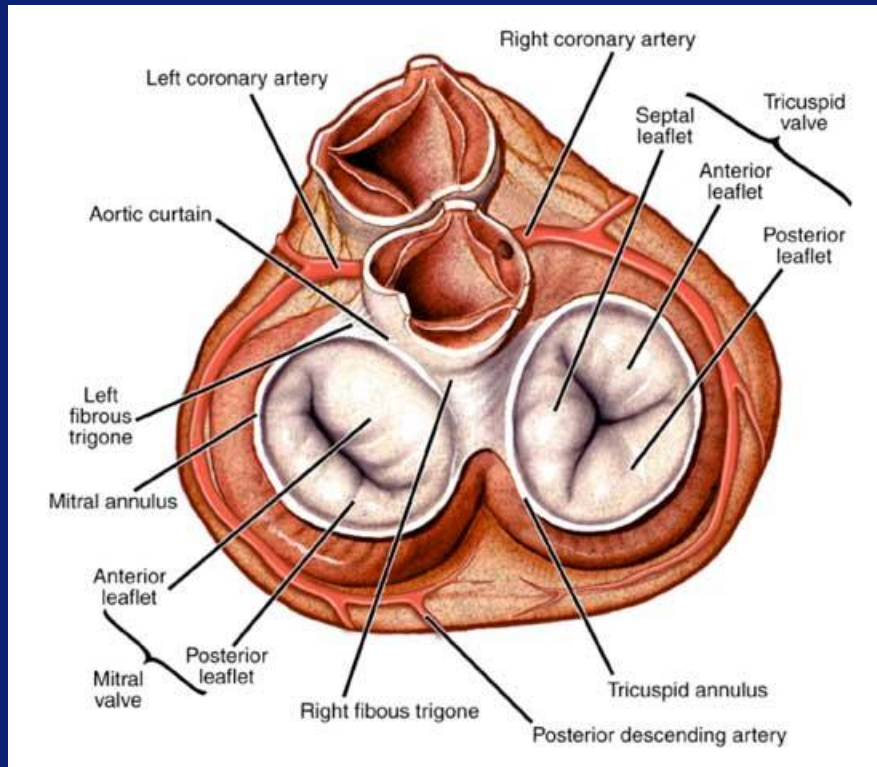
Circumflex

Rechter coronair arterie

Dominantie



Hartkleppen schematisch



Tricuspidalisklep

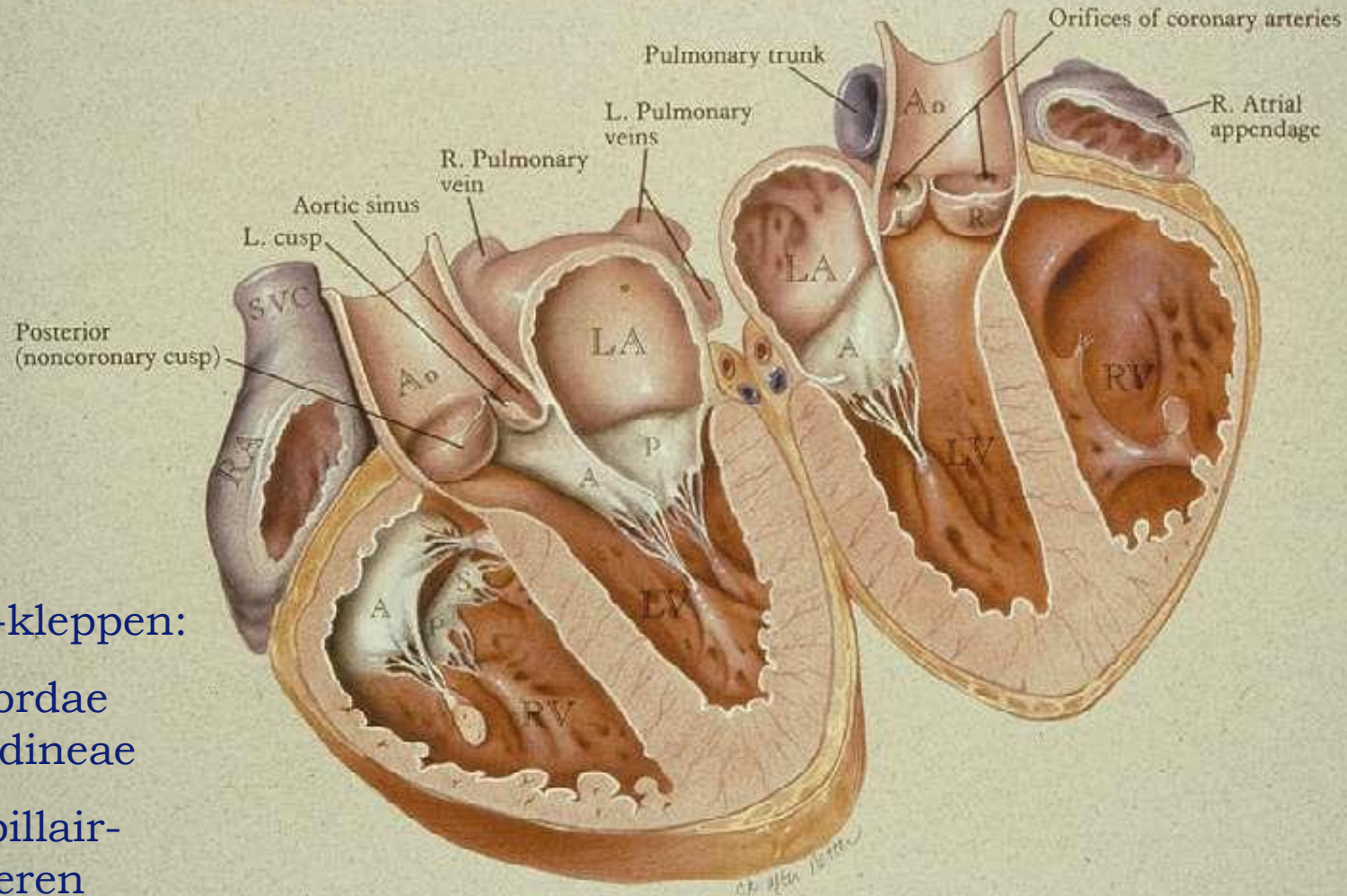
Pulmonalisklep

Mitralisklep

Aortaklep

Hartkleppen illustratie

• AORTIC and MITRAL VALVE ANATOMY



AV-kleppen:

Chordae
tendineae

Papillair-
spieren

Structuren varkenshart

Linker ventrikel

Rechter ventrikel

Apex

Vena cava superior / inferior

Rechter atrium

Linker atrium

AV-groef links en rechts

Linker coronair arterie

LAD

Circumflex

Rechter coronair arterie (RDP)

Aorta

Coronaire ostia

Arteria pulmonalis

Tricuspidalis klep

Mitralisklep

Pulmonalis klep

Aortaklep

Ventrikel wand

Ventrikel septum

Vaatwand aorta

Sinus coronarius

Sinusknoop

AV-knoop

???